



Comprehensive treatment – full Mouth Rehabilitation case

Presented by : Rwaida Ben Essa SALEM
Role number 830:

This work was achieved by the student (Rwaida Ben Essa)under the supervision of dental teaching stuff at Libyan International Medical University

Dr.Rafik AL Kuwafi

Dr.Abdelmonem Abdelnabi

Dr. Omar AL Huni

Dr.Anas AL Harati

Dr.Ali bu snena

Dr.Amal AL Awami

Dr.Abd AL Selam AL Hadad

Dr. Mohamed AL Gatlawi



Personal Data

Name : F.A.F

Date of birth : 20/08/1969

Gender : Female

Nationality : Libyan

Occupation : House wife

Material & Society : Married

Address : Shibna



Chief complaint & History of Chief complaint

C.C :

Bleeding from the gums, since 1 month .

H.C.:

Gingiva bleeding started month ago during tooth brushing and sometimes with eating the bleeding is moderate and is not spontaneous and not present during sleep is last for few min No associated systemic symptoms no history of bleeding disorder or medication intake no history of trauma or epilepsy Not present in family and no pregnant



Medical history : N.O.S

Drug history : N.O.S

Allergic history : N.O.S

Family history :

Free

Dental history :

Extraction without complications since years ago .

Social history :

Married , has 8 children

P.t is on non balanced diet which is more likely to be
carbohydrated diet .



Extra-oral examination

Face symmetry : symmetrical

Scarring : N.A.D

Skin color : N.A.D

Lesions : N.A.D

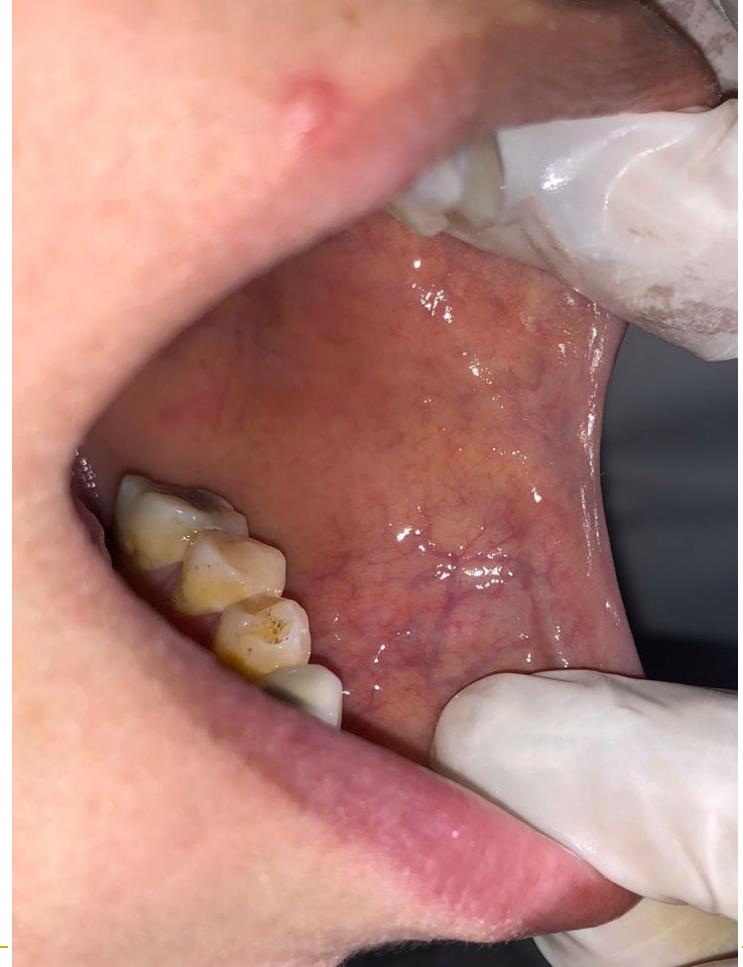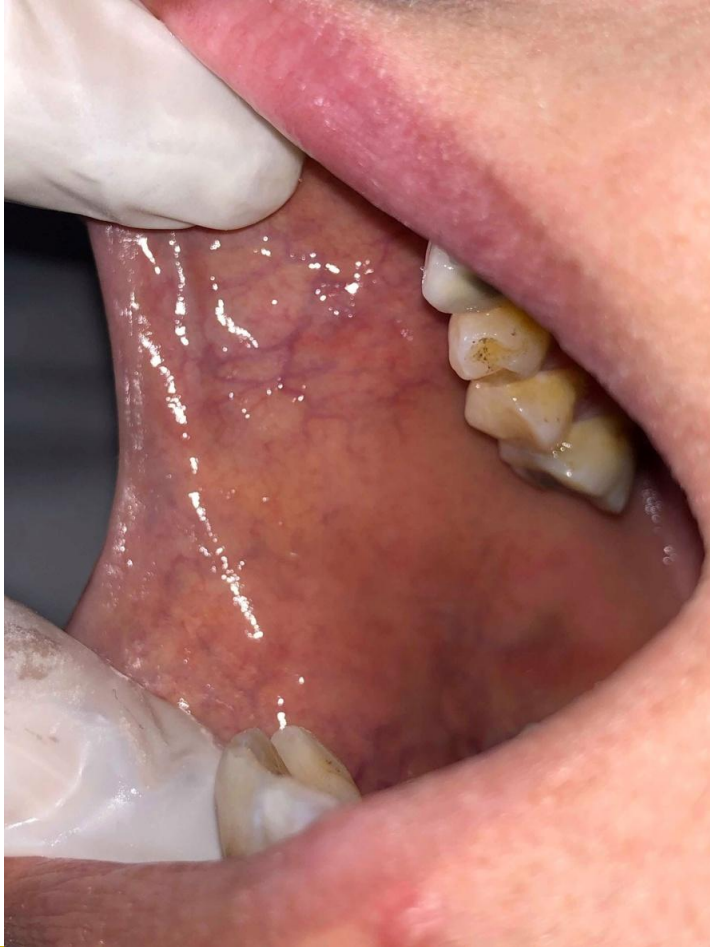T M J: N.A.D

L . N : not palpable not tender .



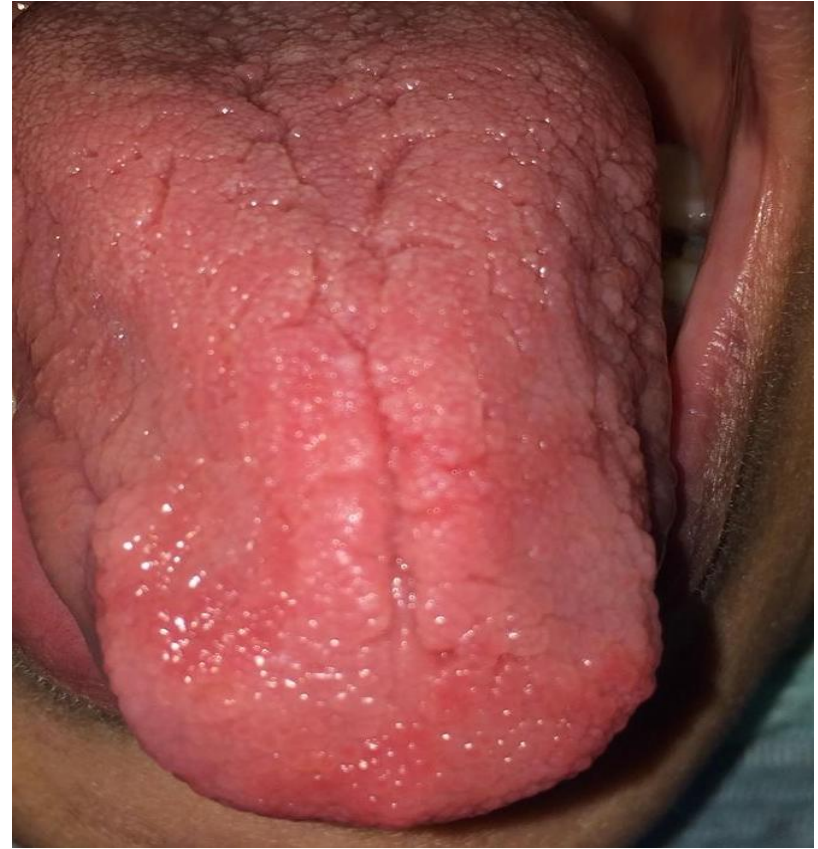
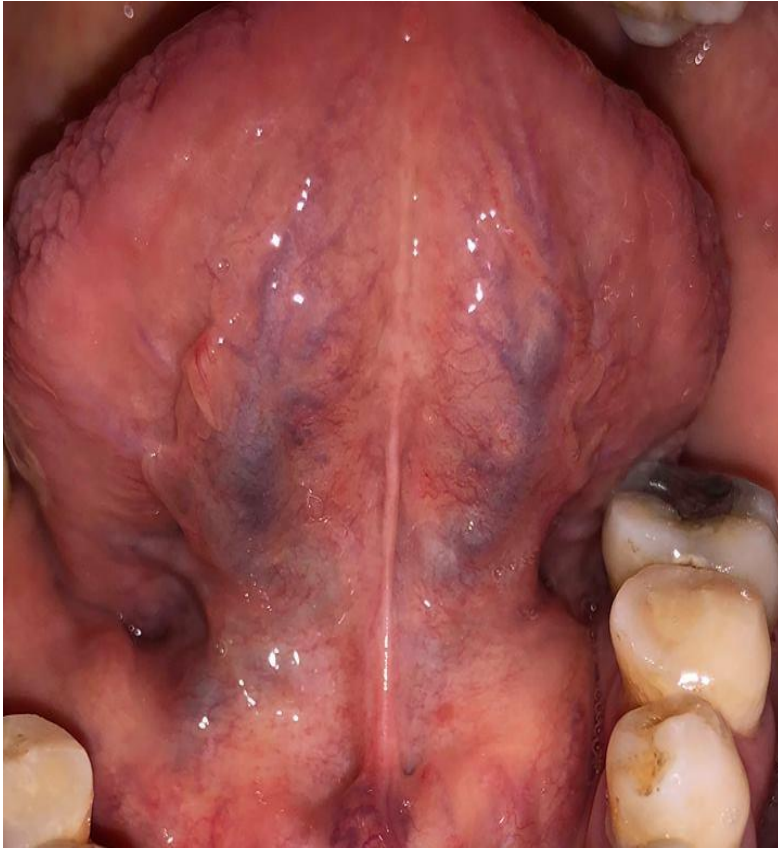Intra Oral Examination

Oral mucosa

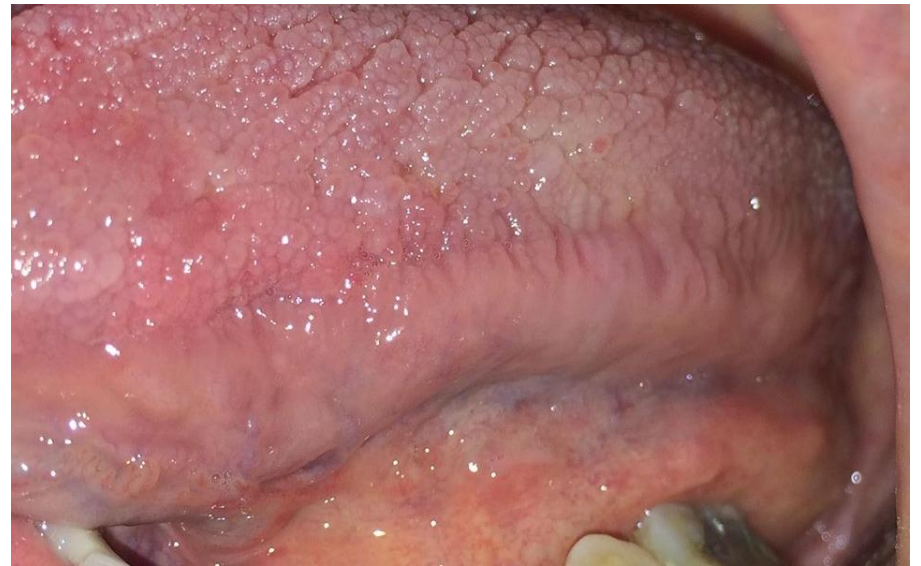
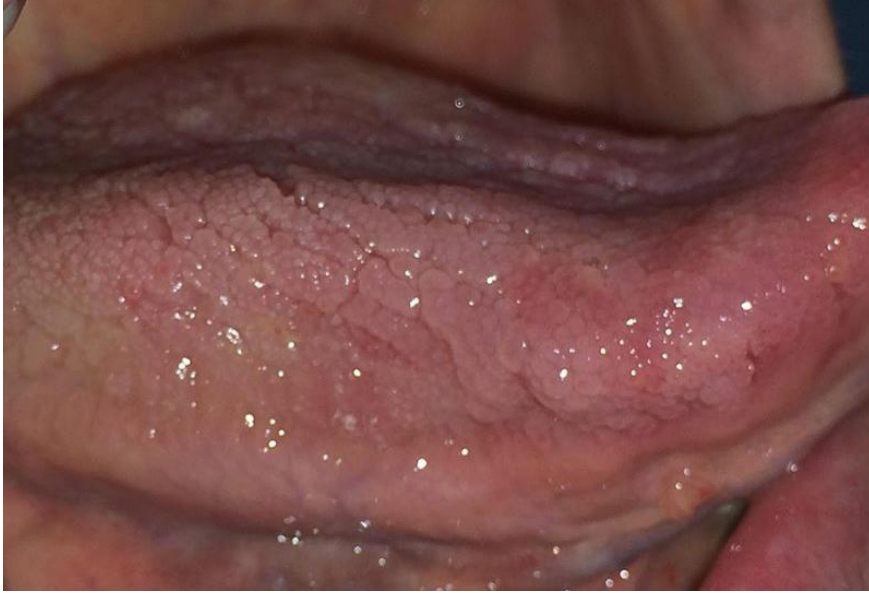
Floor of the mouth

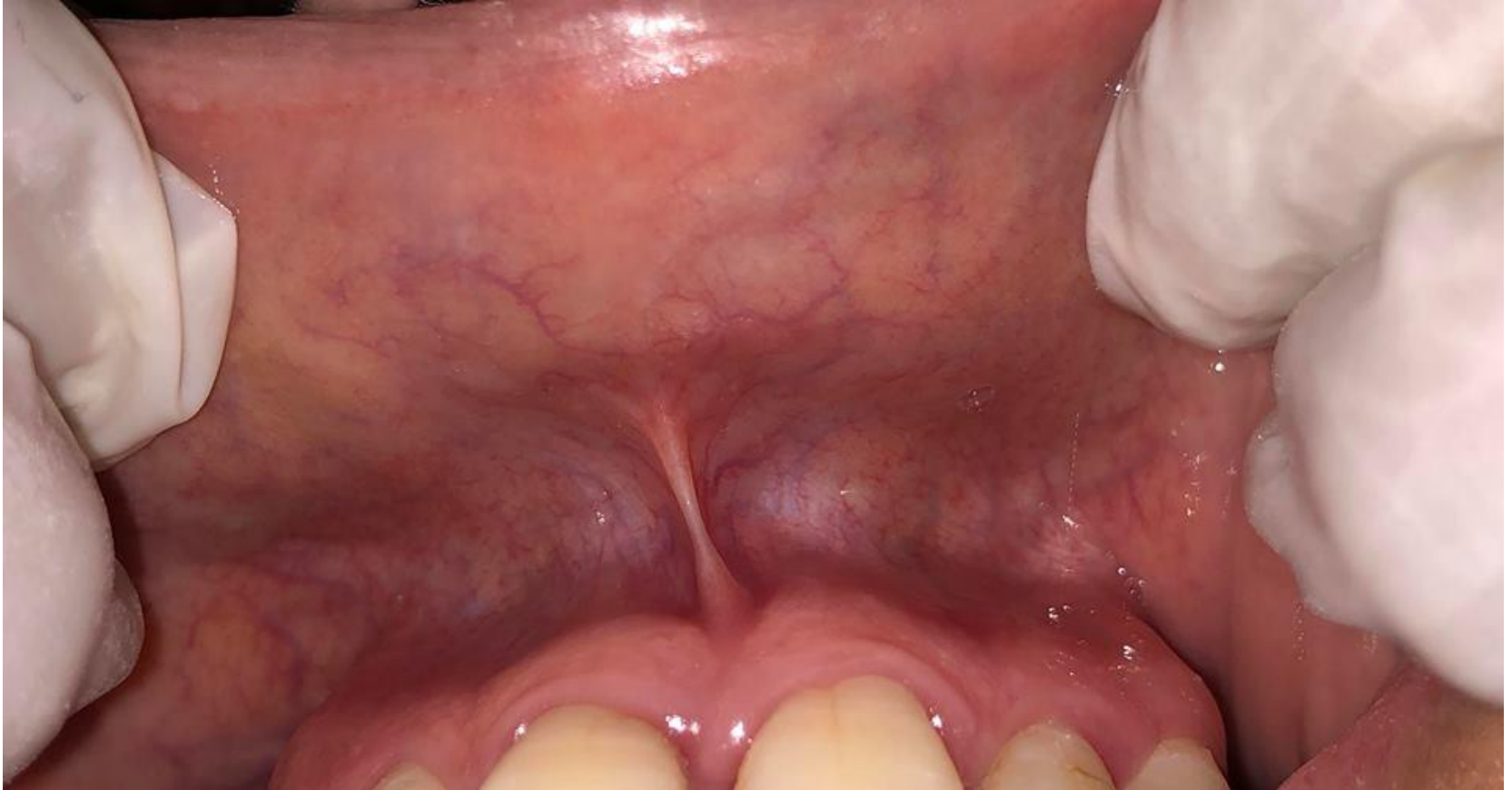dorsum of tongue



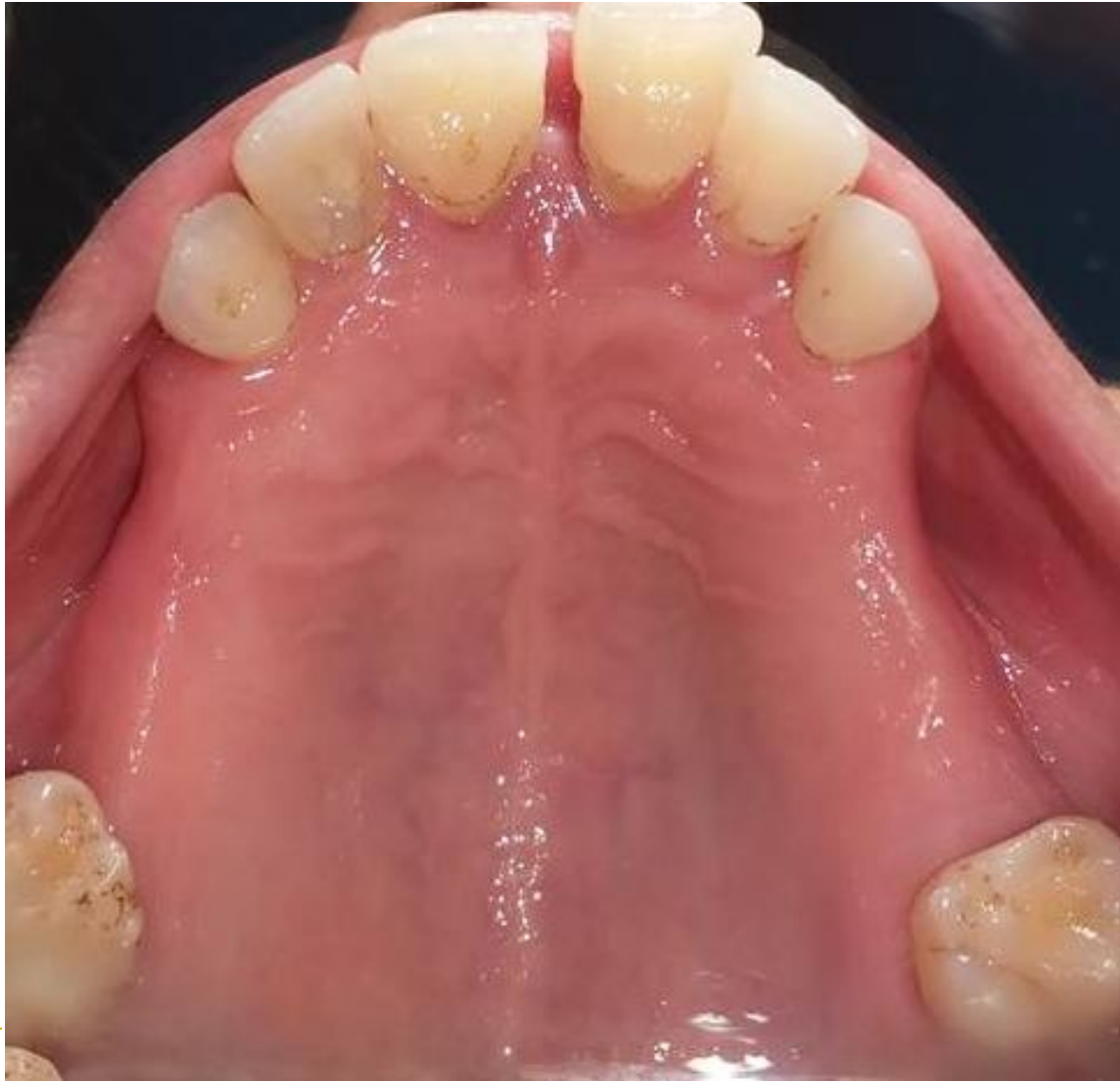LATERAL SIDE OF TONGUE



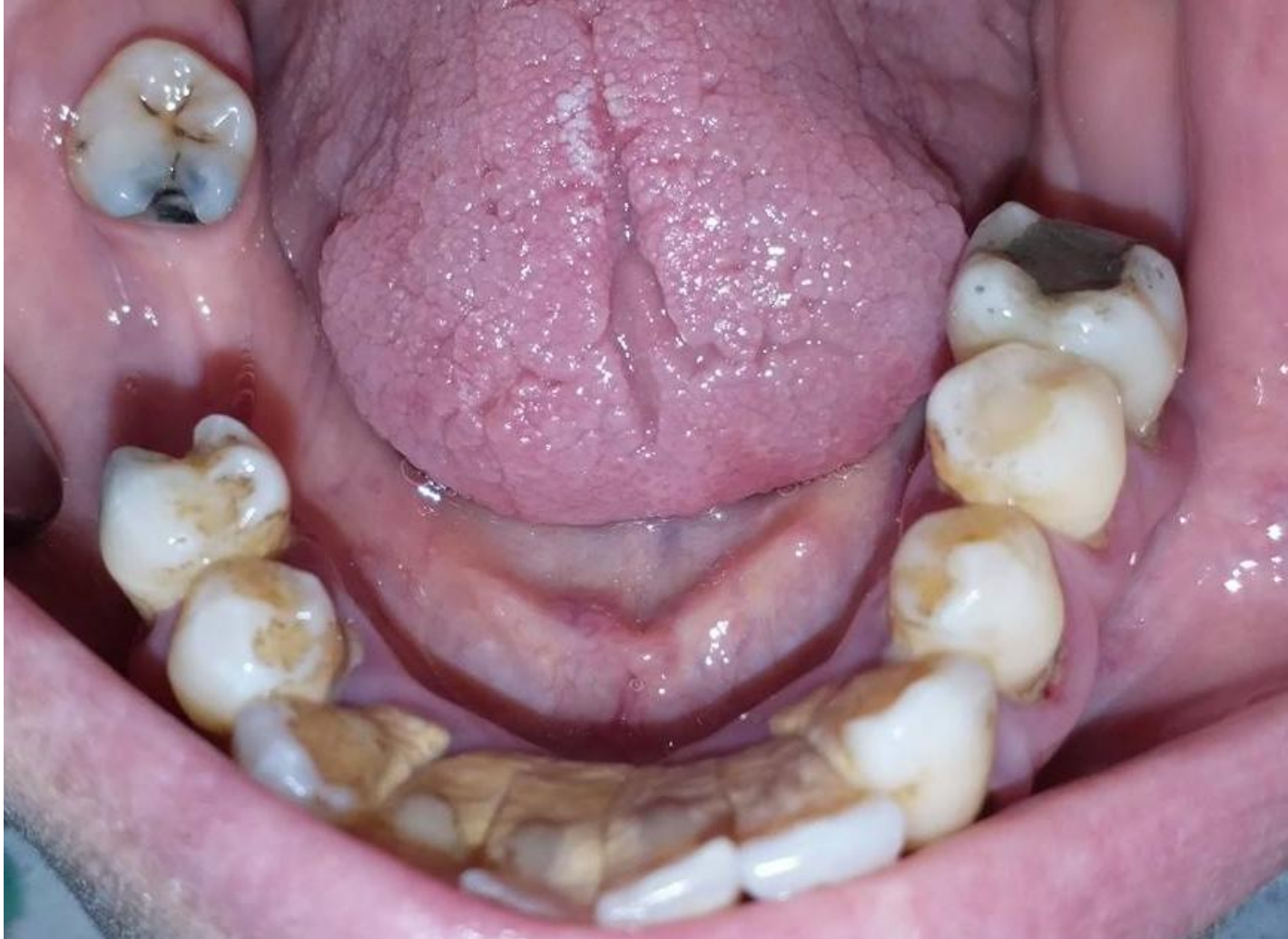Frenum



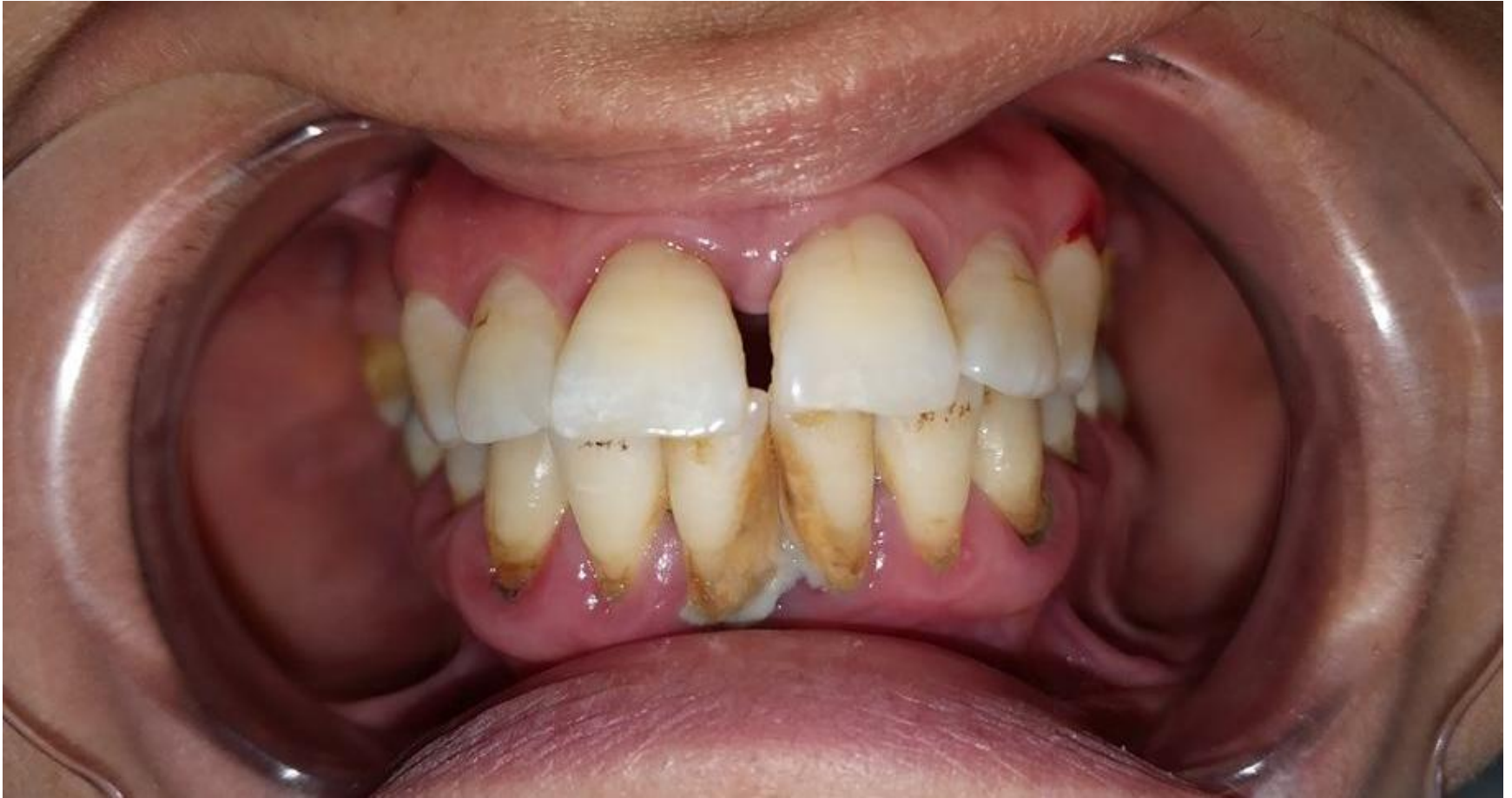Upper Arch



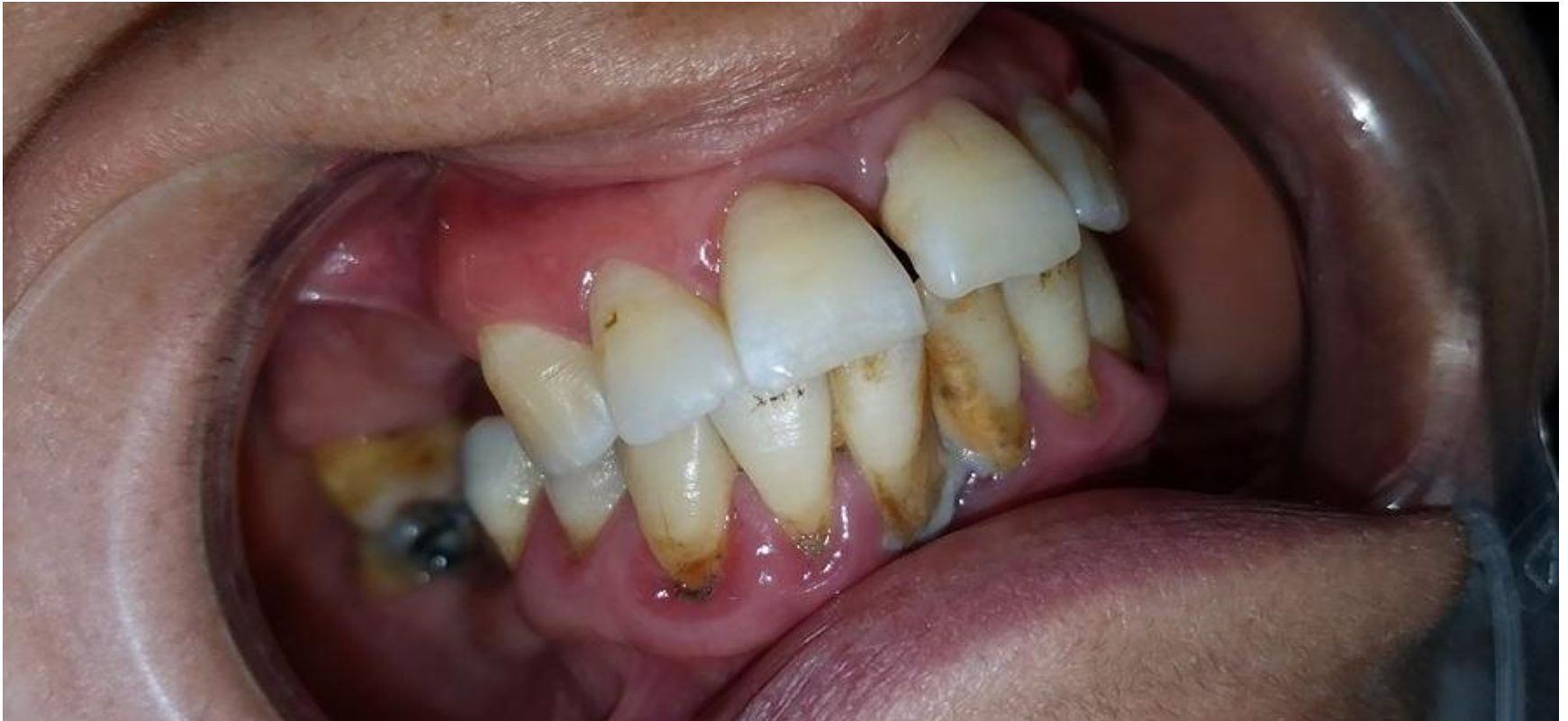Lower Arch



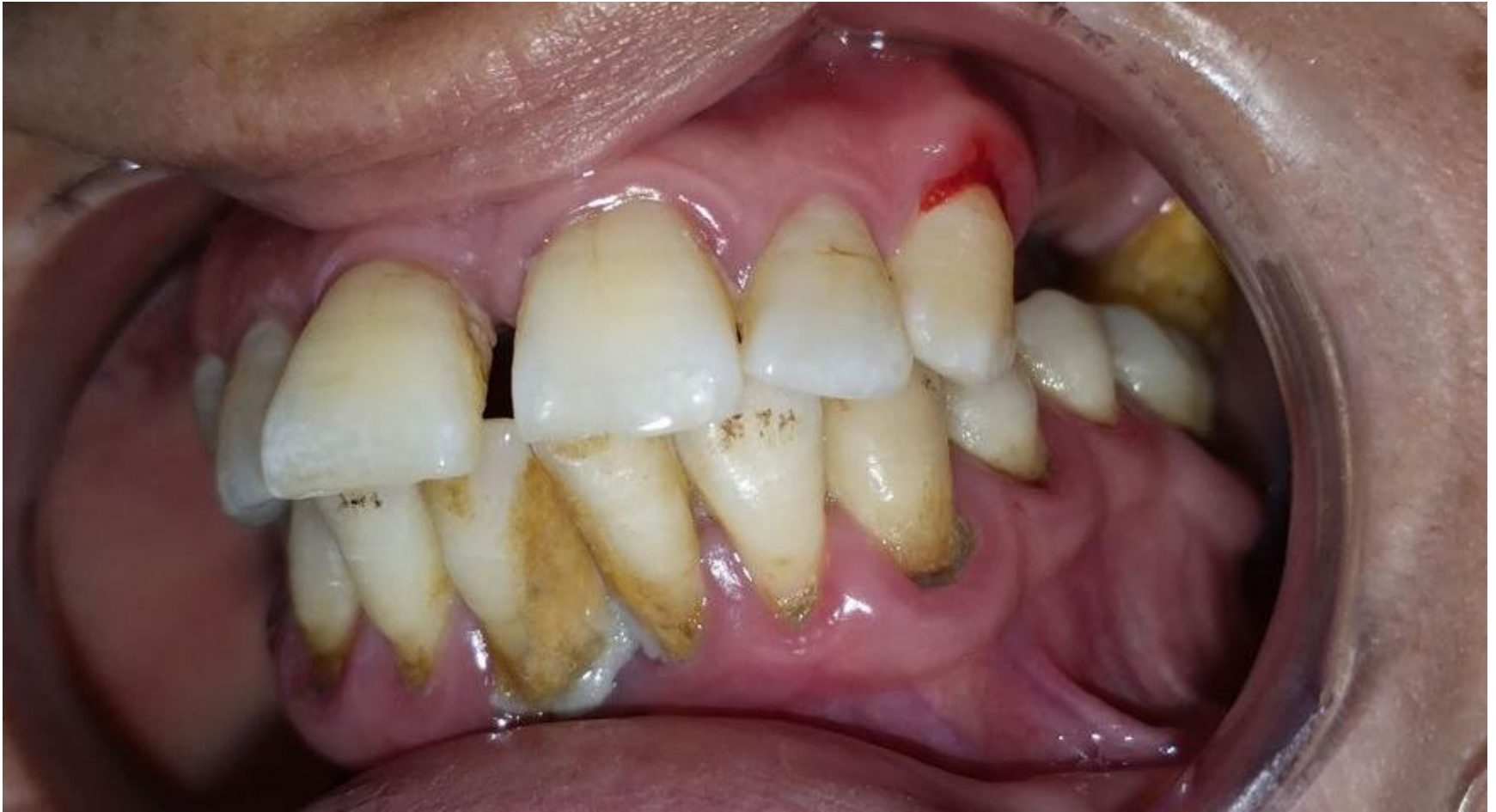FRONTAL VIEW



RIGHT VIEW

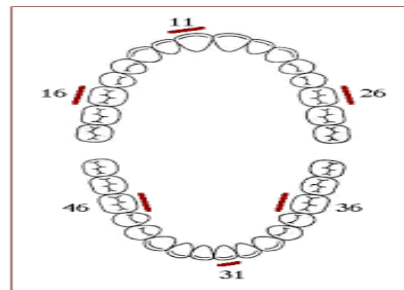
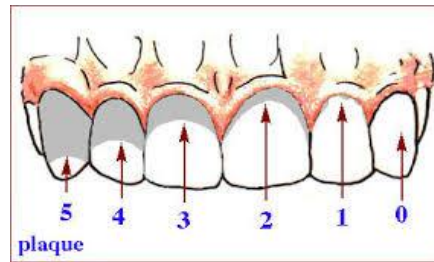


LEFT VIEW



ORAL Hygiene Index simplified

16	11	26
0	1	0
0	4	4
46	31	46

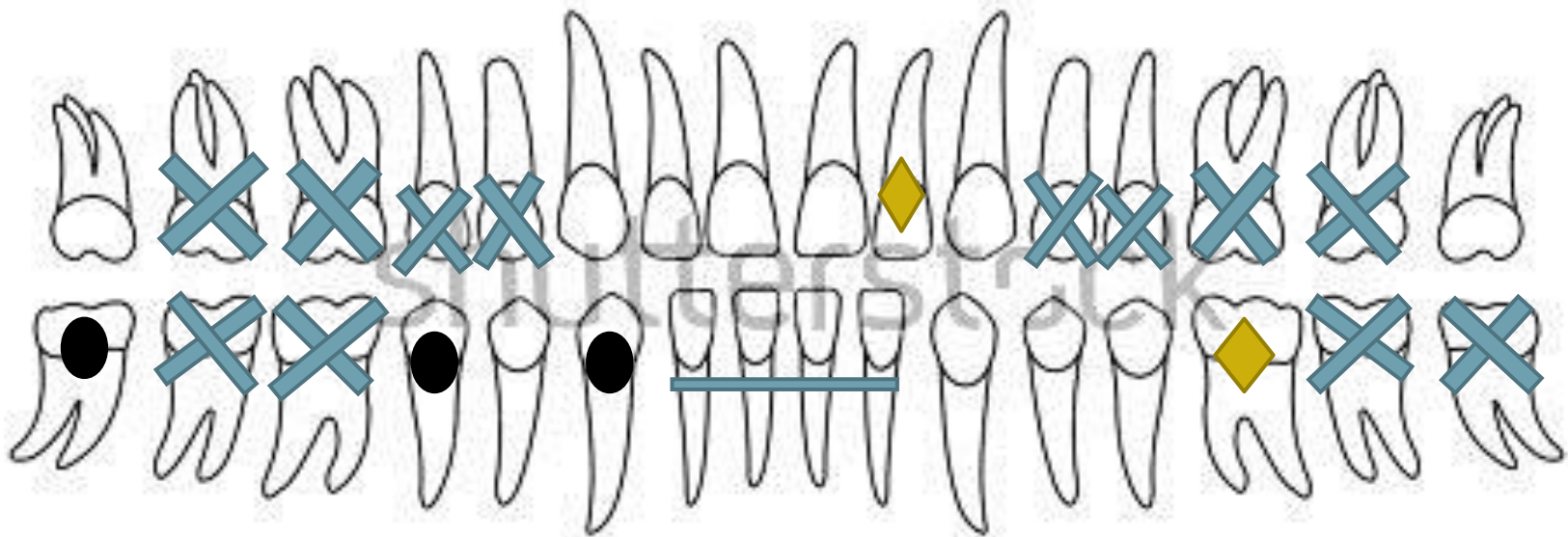


16	11	46
0	1	0
0	3	3
46	31	36

Poor



Intra Oral Examination



Missed



Carious



Filled



Periodontal health

Normal >>> firm to resilient gingiva with collar pink color, and normal scalloped margin, normal stippling with no enlargement or exudates . But blunt end IDP , and gingival bleeding on probing .

Calculus : 5 4 3 2 1 1 2 3 4 5

Mobility :

GRADE (I) 2 lower lateral incisors GRADE (III) lower 2 central incisors



Cont

P.D and L.A: 2 3 4 5 6 5 4 3 2

Recession : 1 2 3 4 5 3 2 1

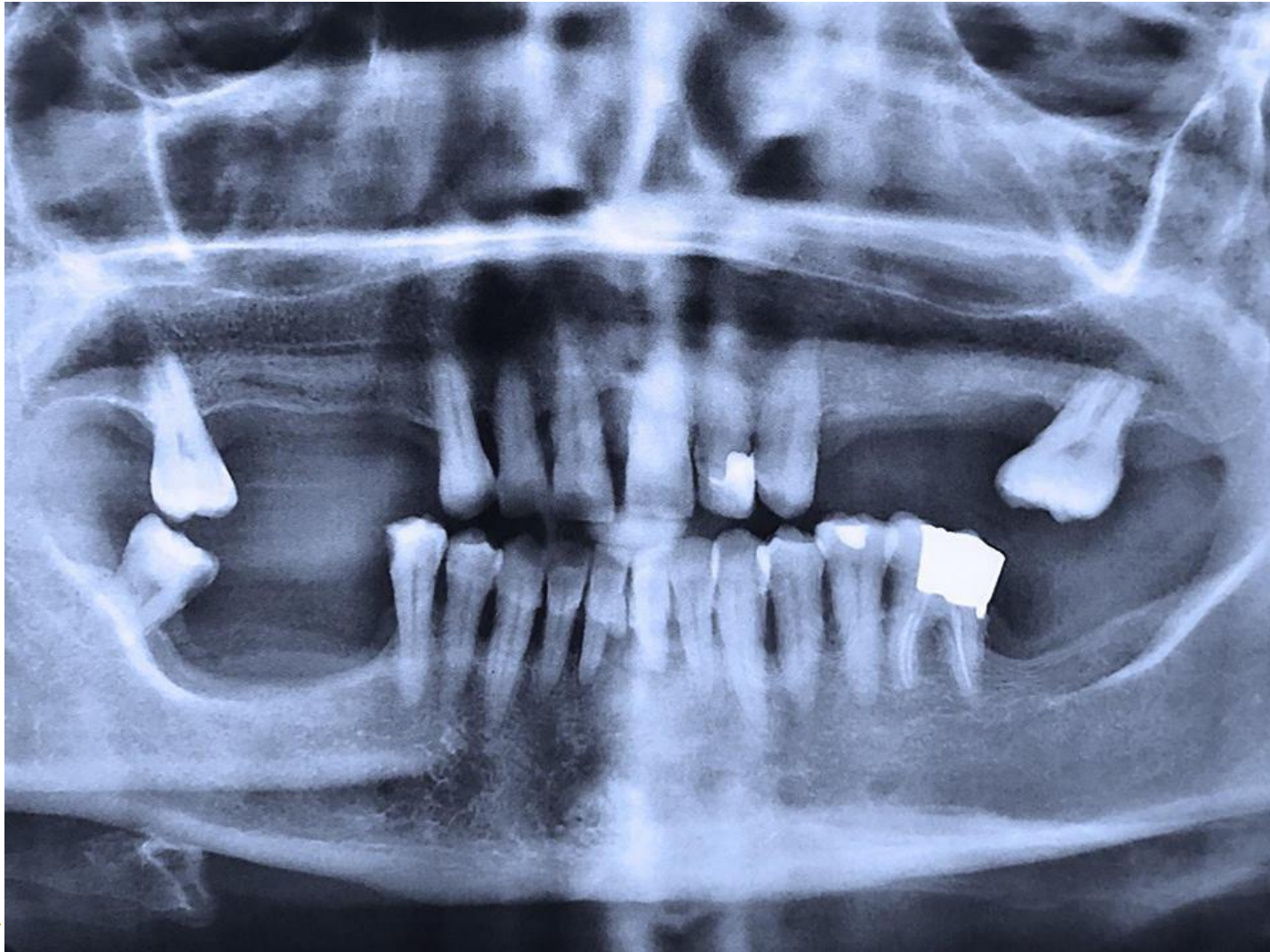


Differential diagnosis

- ▶ Generalized moderate to severe chronic periodontitis
- ▶ Aggressive periodontitis



orthopantomogram



Final Diagnosis

Generalized moderate to severe chronic periodontitis

Findings :

- Dental caries :

LR8 , LR5(Class II) LR3 (Class V)

- Mobility : LR1,LL1 (Grade III) LR2 , LL2 (Grade I)

KENNEDY classification Maxillary CLASS III Modifications
Mandibular Class II

Modification I

CLASS II MALOCCLUSION



Treatment plan

Phase I :

P.T motivation and education

O.H.I

Supra & Sub gingival scaling & Root planning

Impression for immediate denture to replace

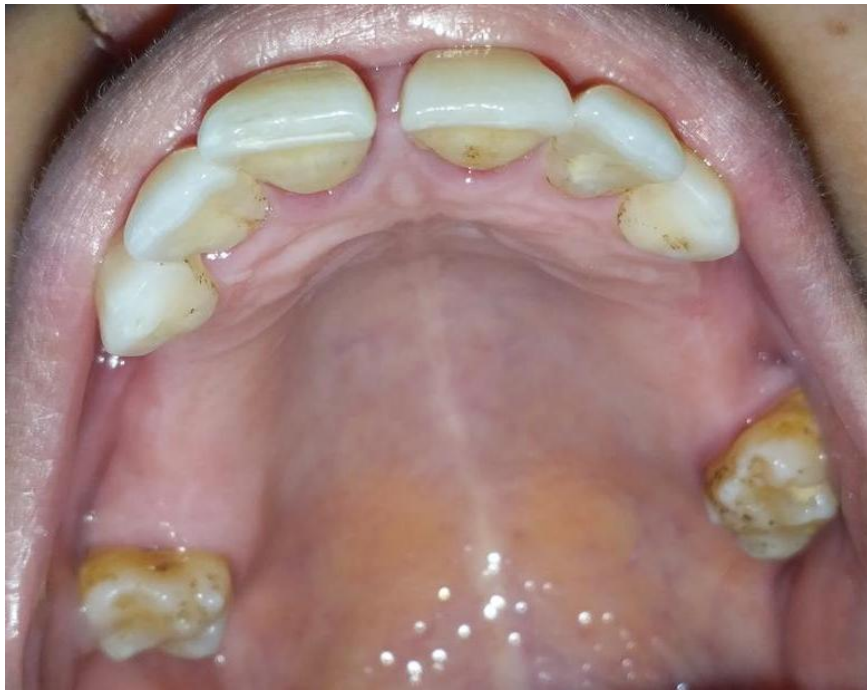LRI,LLI

Re - evaluation of Phase I and perio -
maintenance

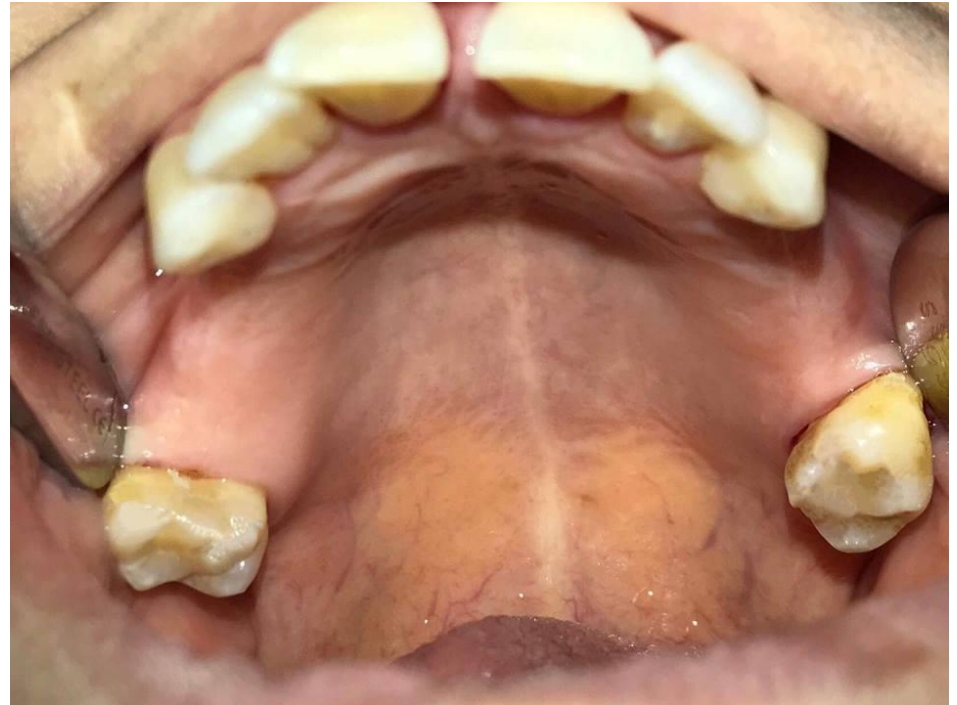

Supra & Sub gingival scaling & Root planning

Before

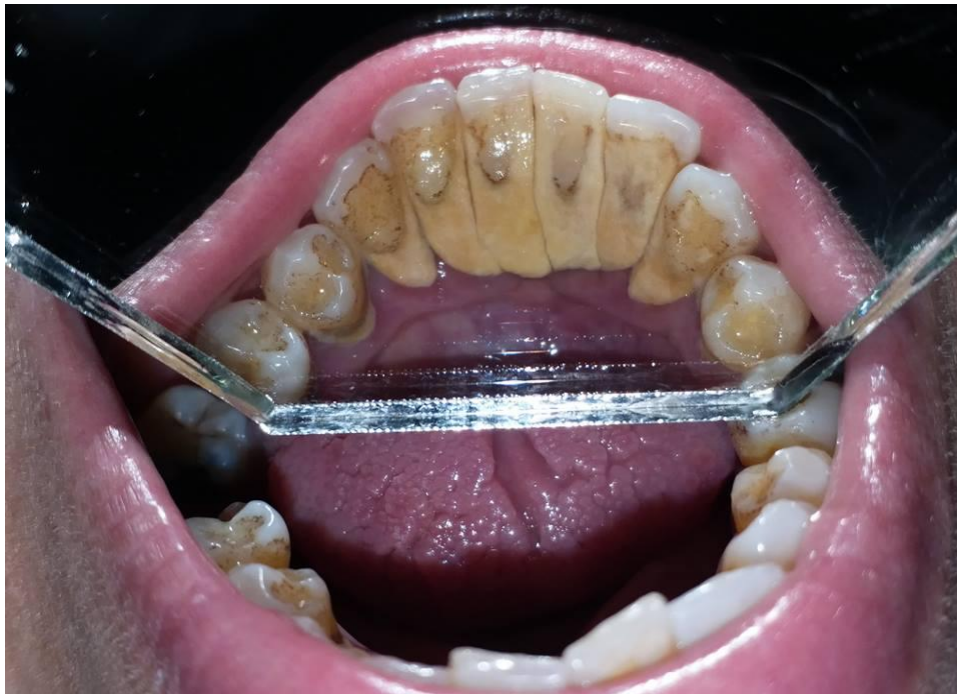

After

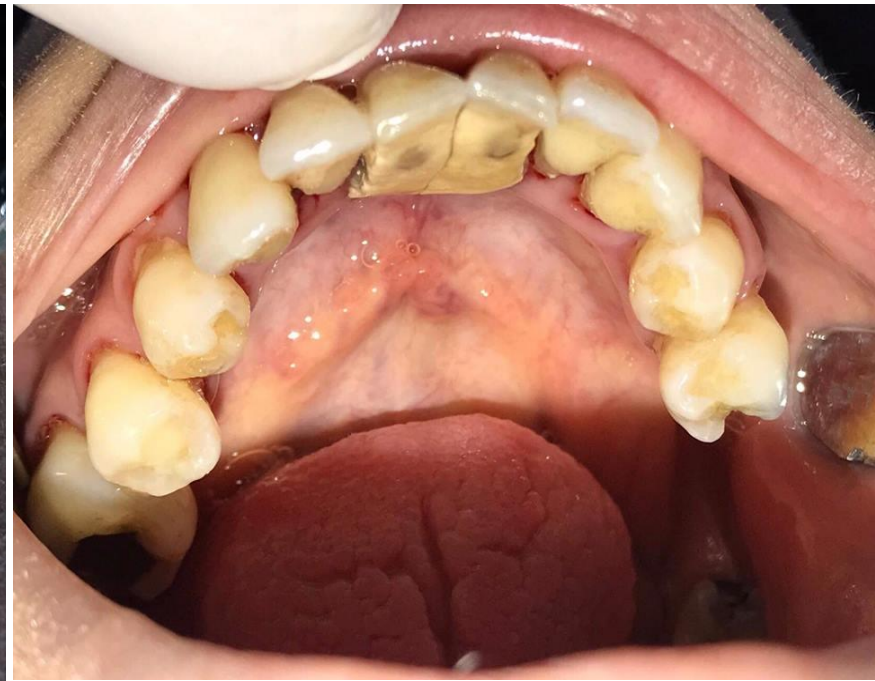

Supra & Sub gingival scaling & Root planning

Before



After



Cont ...

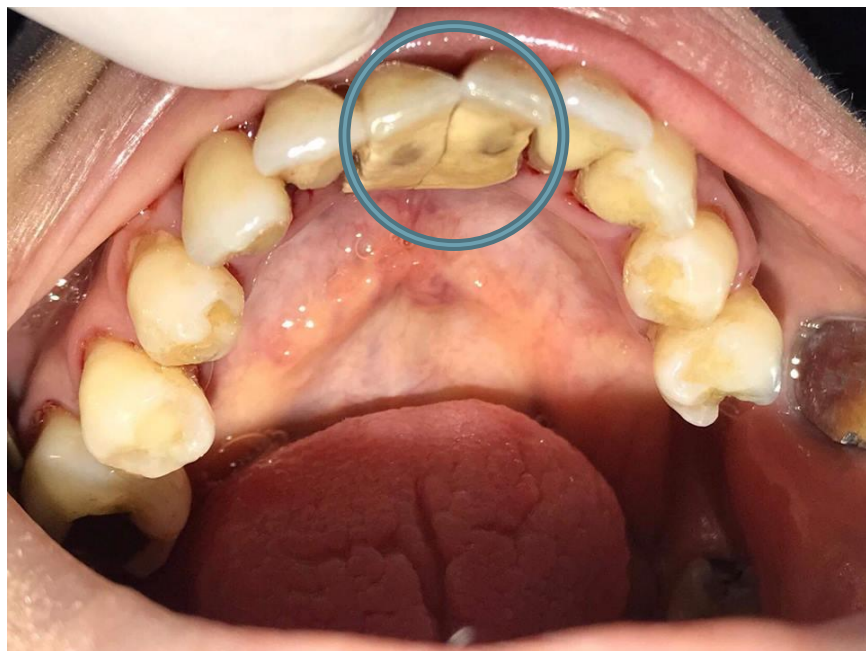
Phase II :

Extraction LRI,LLI

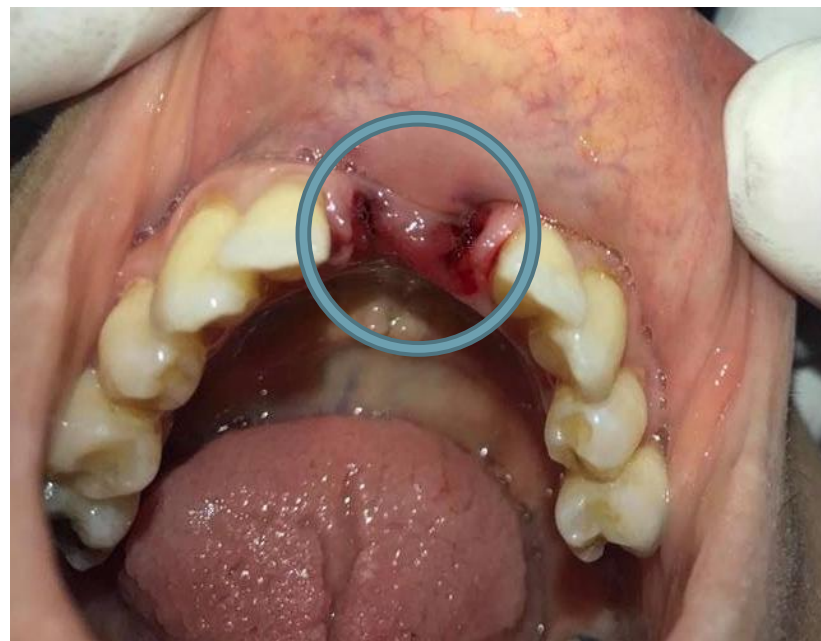


Extraction 2 lower central incisor

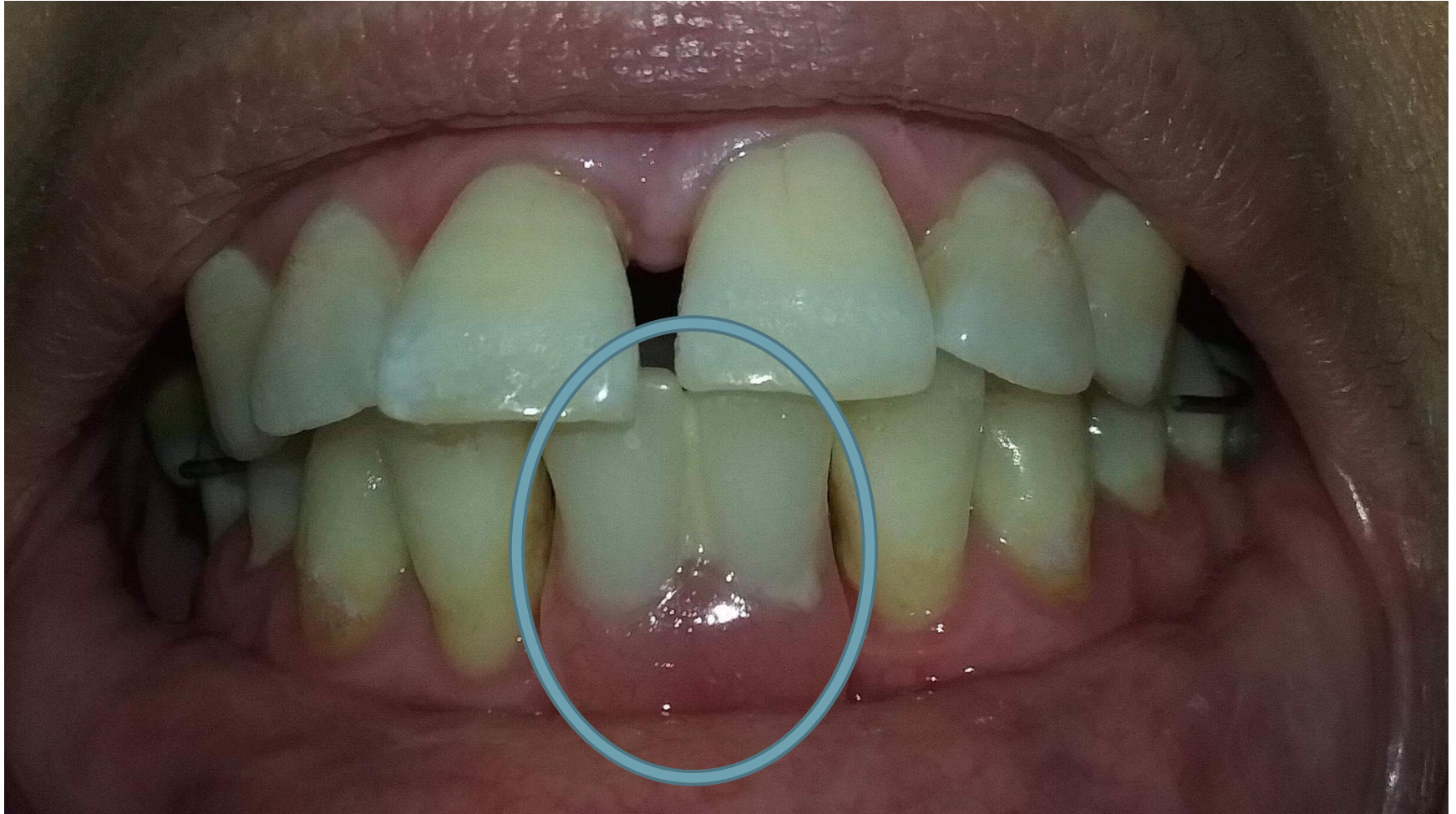Before



After



Immediate denture



Treatment plan options for Ph.III

Composite filling LR 8 5 3

- Implant
- Over denture
- Removable partial denture until the p.t can do implant



Removable partial denture -

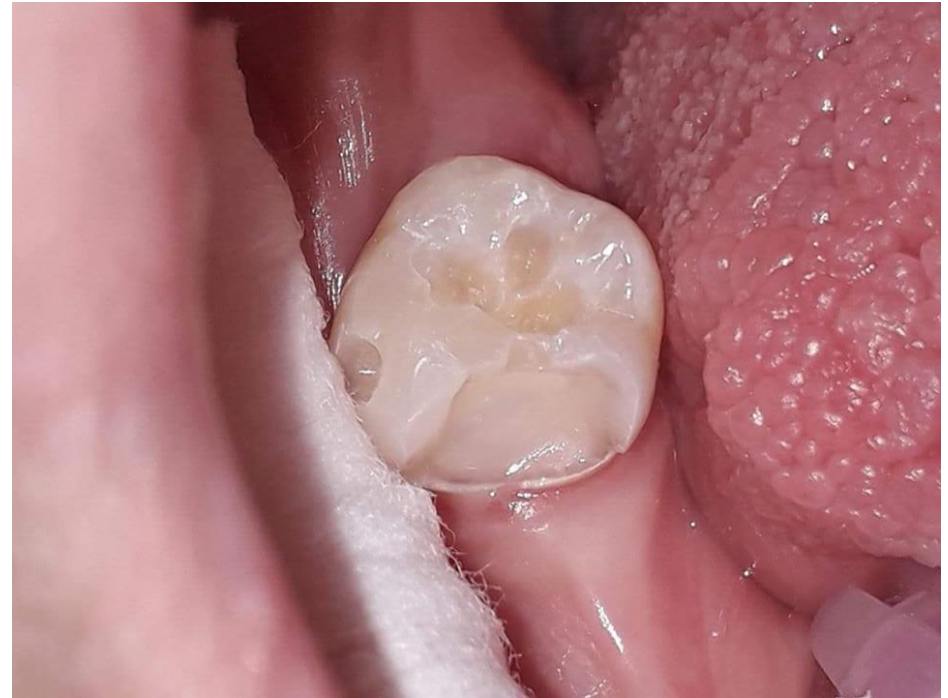
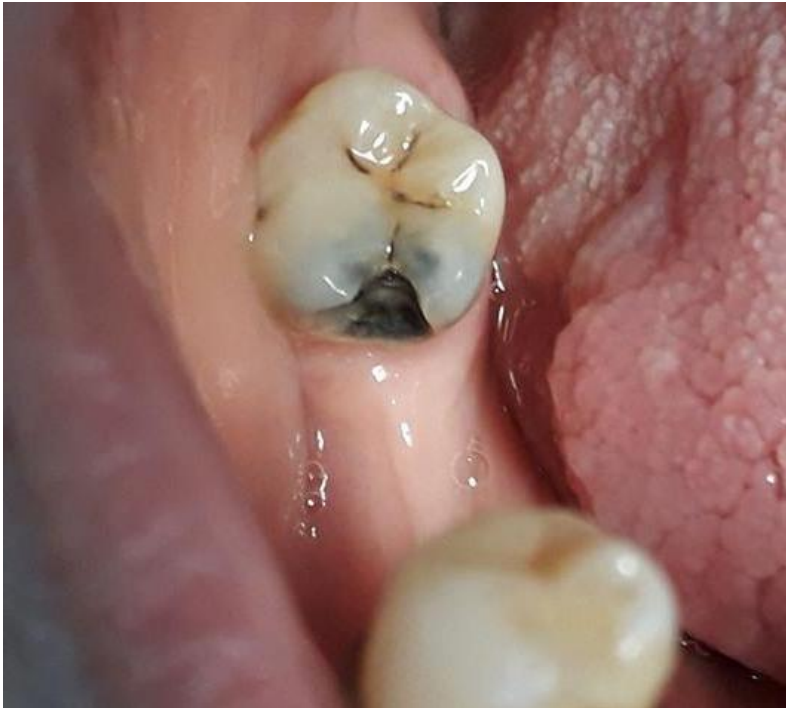
Restoration ▶



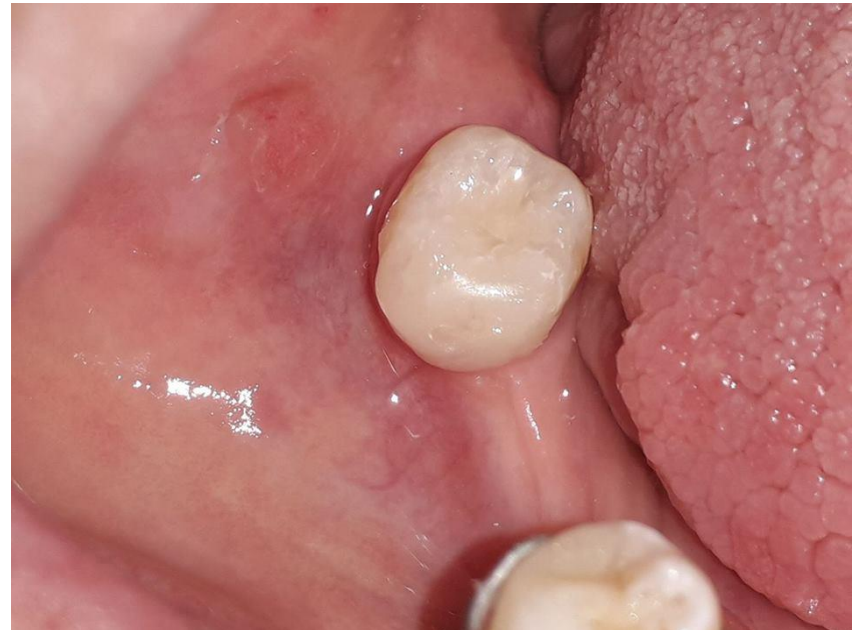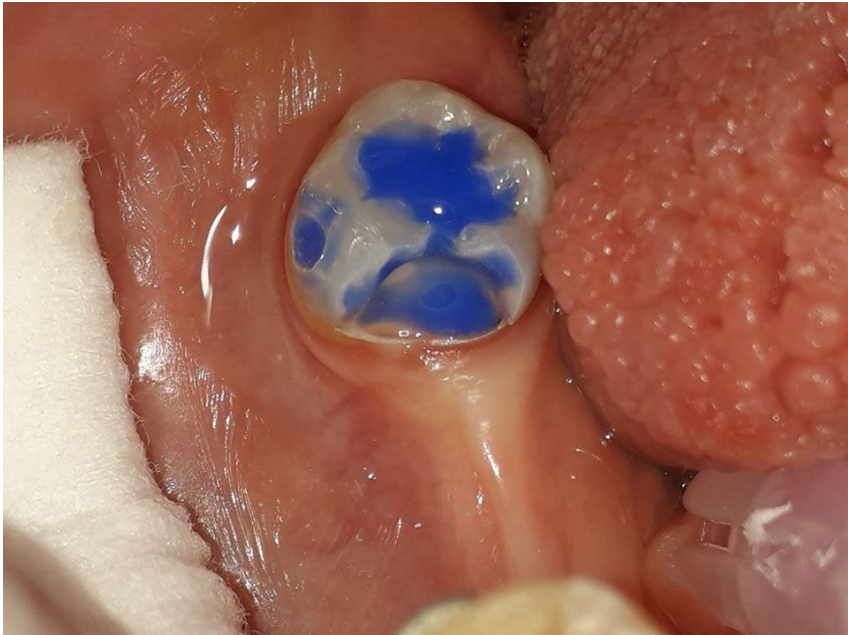Restorative class II lower 3rd molar

Before

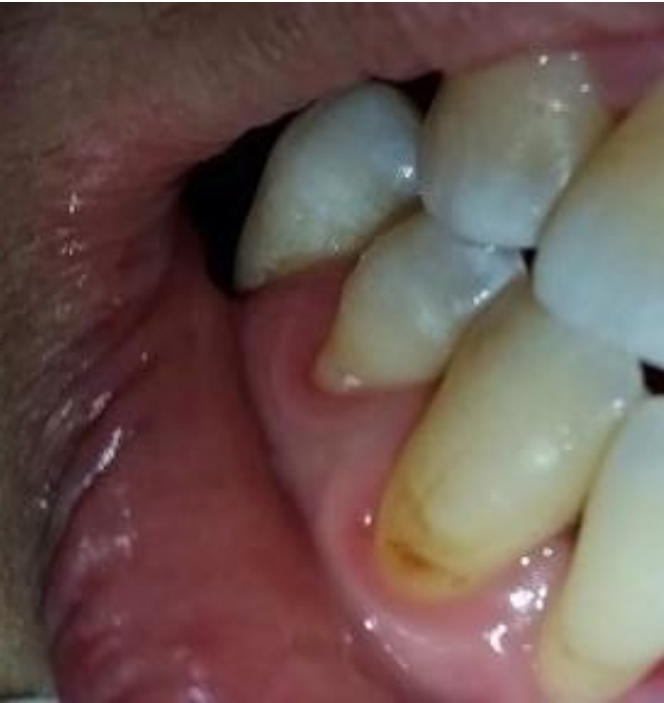

cont....

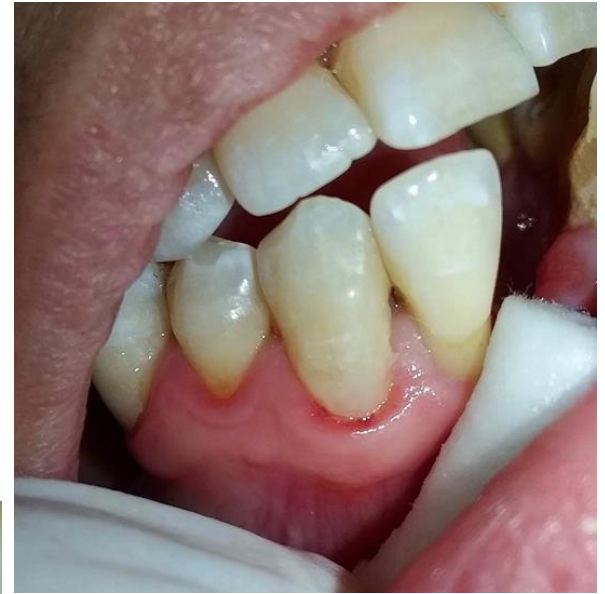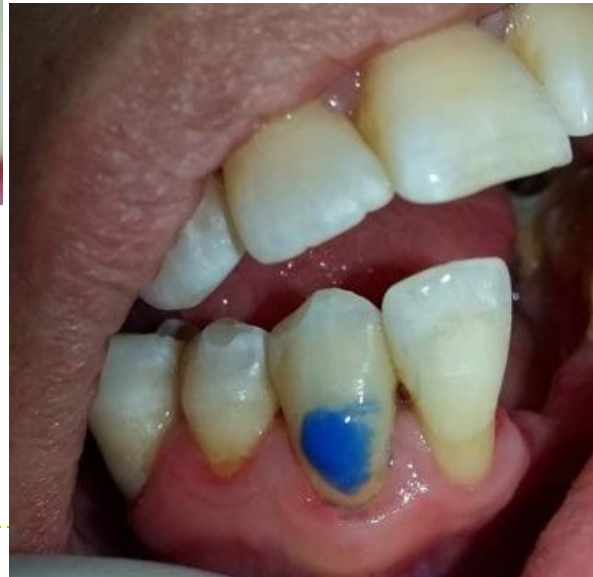After



Class V Lower right 3



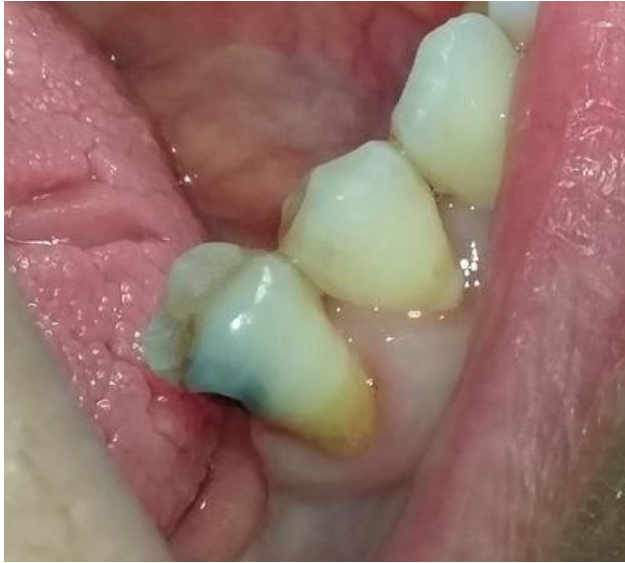Before



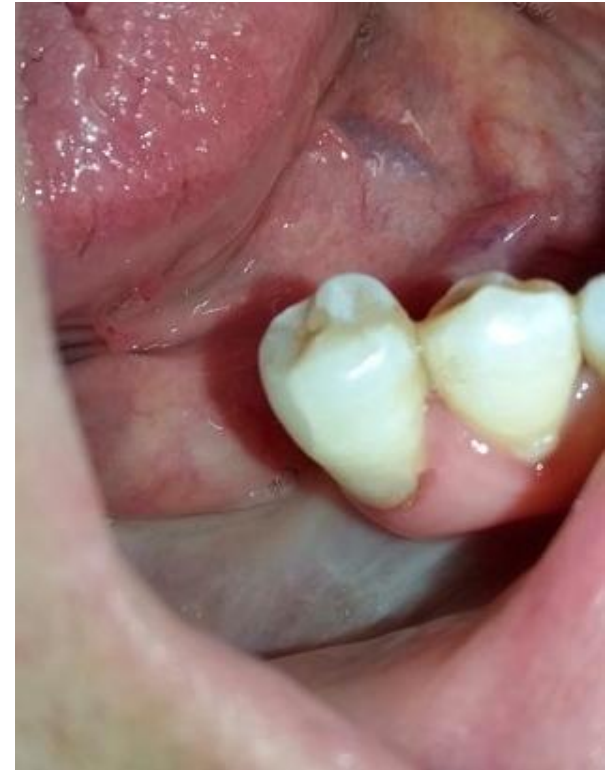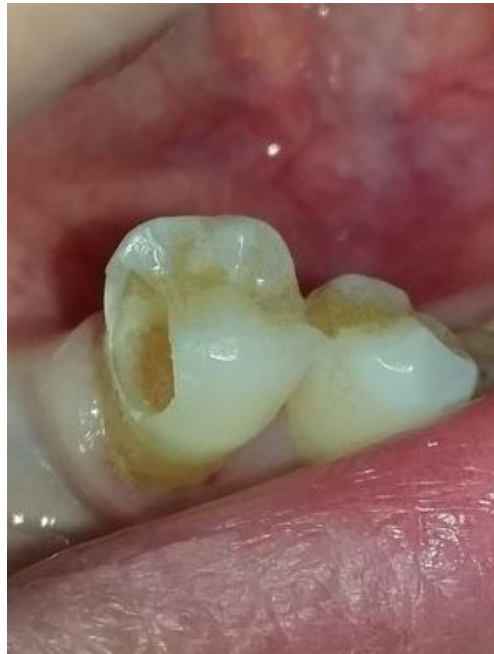After



Class II Lower right 5



Before



After

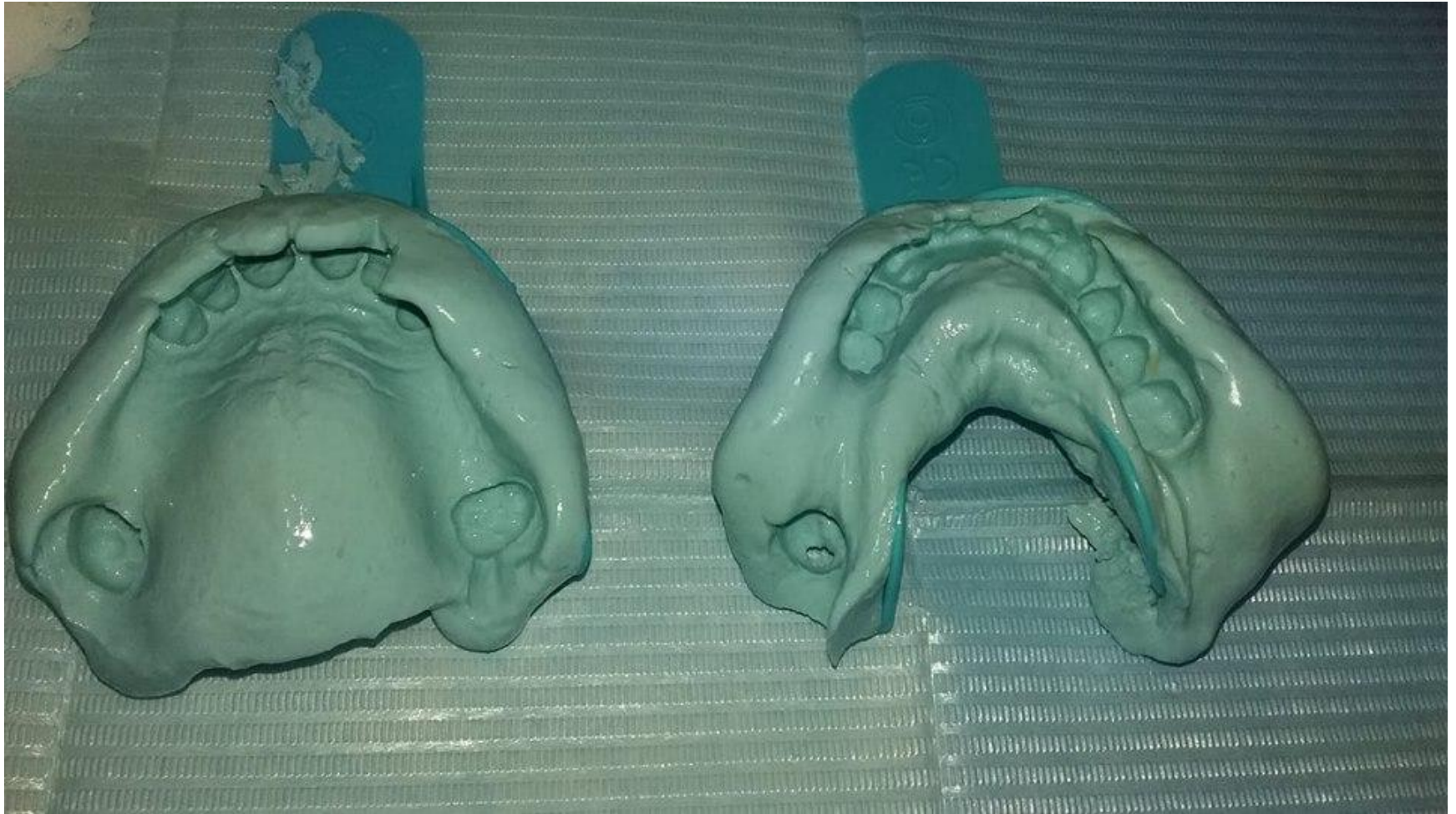

PROSTHATIC

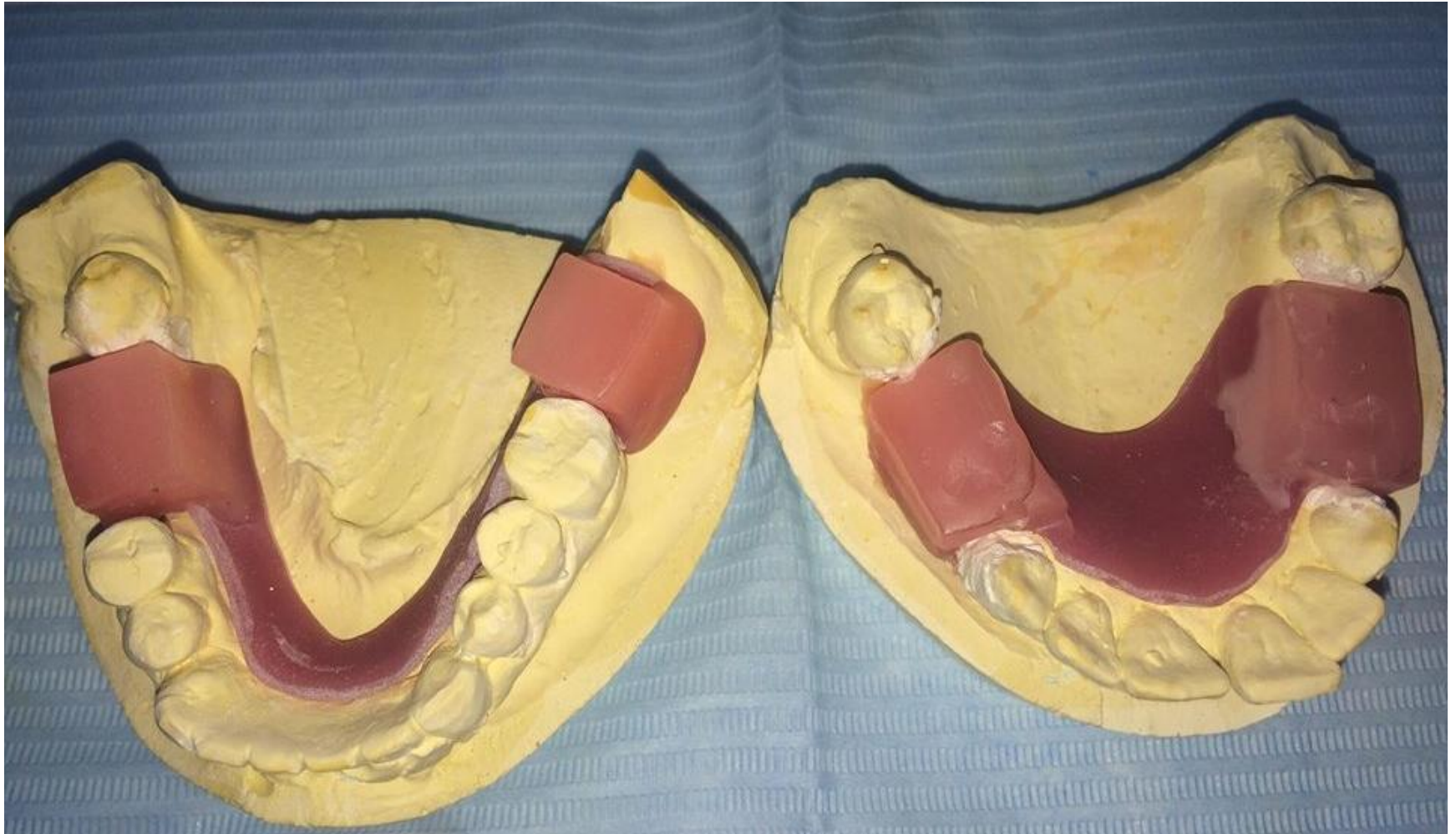Removable partial denture ▶

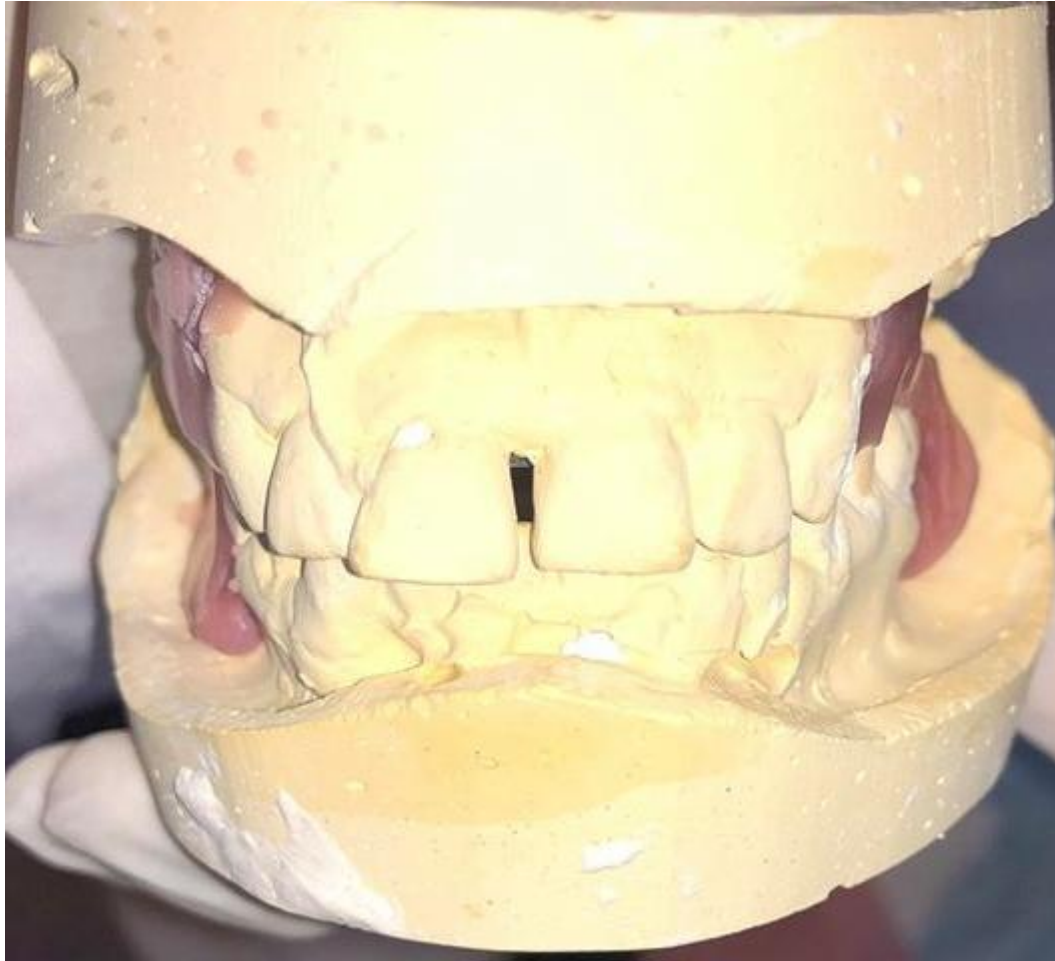

Impression upper and lower

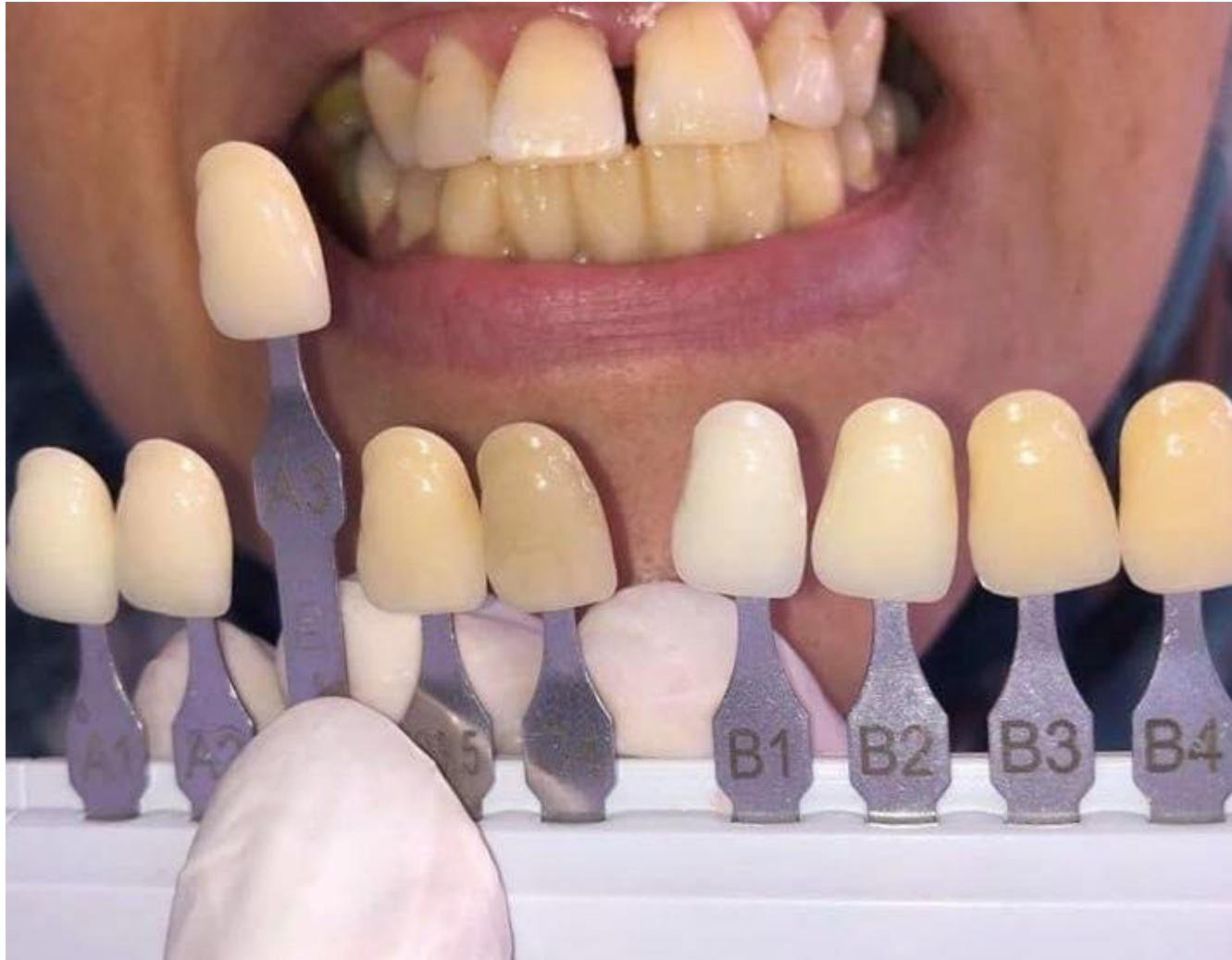

Record block

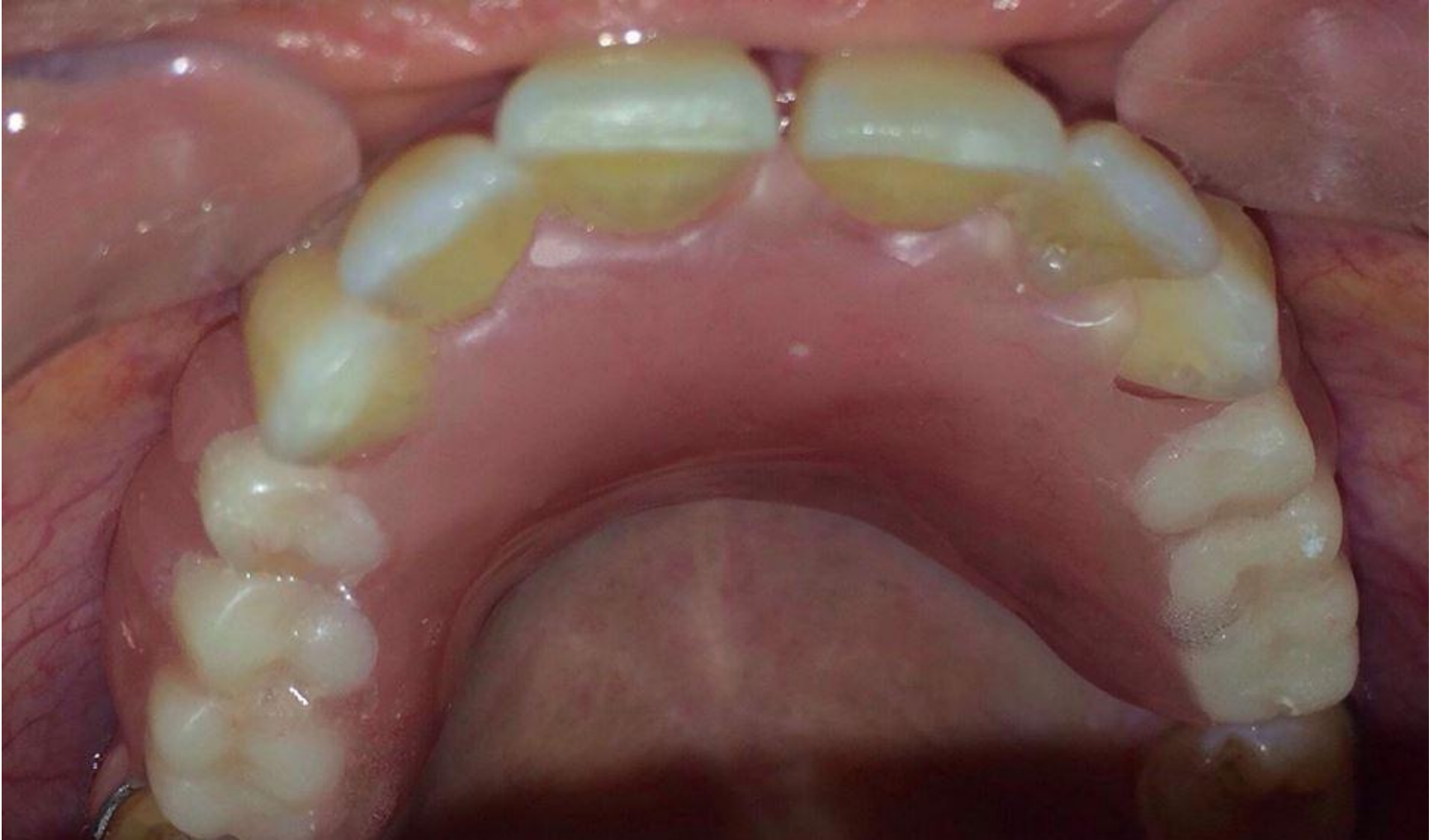



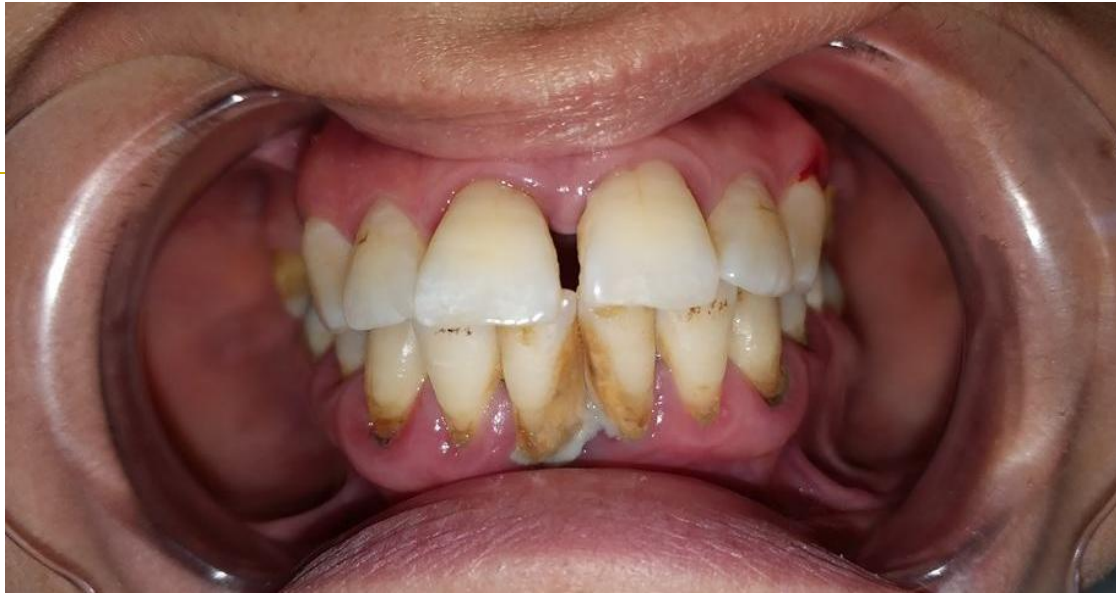Shade selection



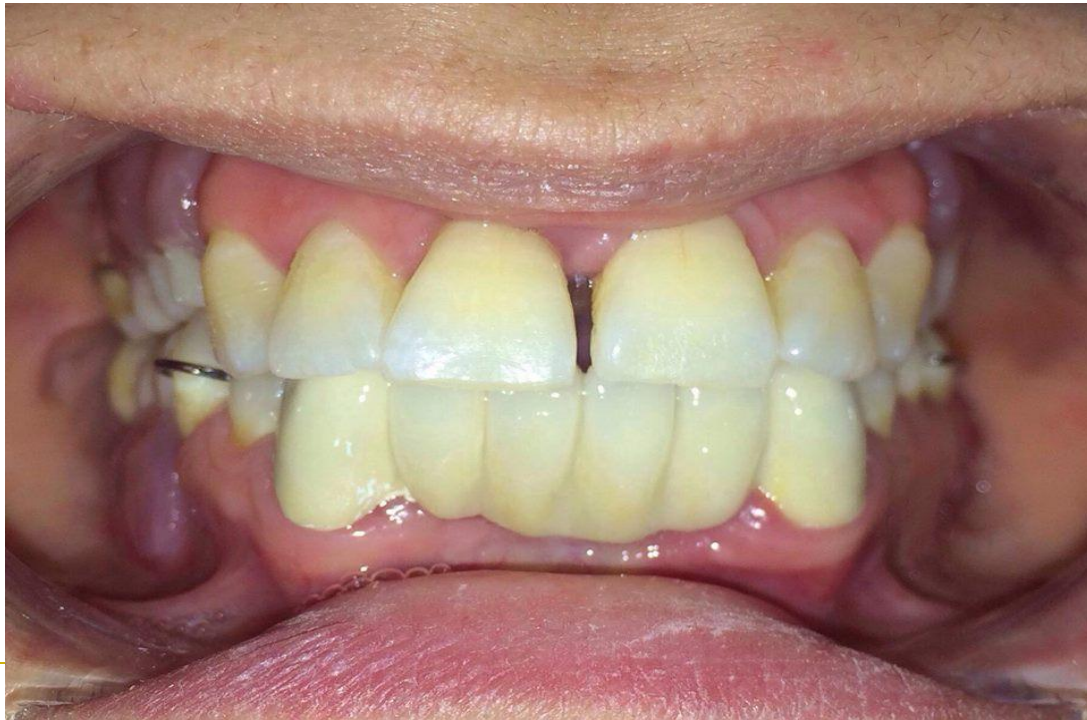Insertion



Before



After



Phase V :

Maintenance

**Check up every 3 months 1st
year and 6 months every**



A top-down view of a wooden desk with a typewriter, a notebook, a pinecone, glasses, and a box of color slides.

Thank You
== For Your Attention ==