



Libyan International Medical University  
الجامعة الليبية الدولية للعلوم الطبية



# Comprehensive case presentation



By : Manar Saleh Abdali  
ID : 1556

This work was achieved in  
LIMU dental clinic Under  
supervision of:

- Dr. Rafik Alkwafi
- Dr. Abdelmonem Abdelnabi
- Dr. Ali Bosnina
- Dr. Omar Elhuny
- Dr. Masoud Dihoum
- Dr. Khadija Elfallah
- Dr. Nada Kashbour
- Dr. Hashem Alaraiby
- Dr. Randa El-hassy
- Dr. Amal Alawami
- Dr. Marwa Alsharkasi
- Dr. Sara Alkelani



# Patient details:

- initial: F.E.A
- Date of birth: 1972.3.20
- Sex: female
- occupation: nurse
- Nationality: Libyan



# Chief complaint:

Pain in the lower left side of the jaw since one month.

# History of chief complaint:

Mild intermitted localized throbbing pain increase during eating and drinking cold drinks, relieved by analgesic's, not interfere sleep no associated symptoms. Pain start from 3 months severe spontaneous localized increase with hot and cold drinks reduce with analgesics, interfere sleep, associated symptoms headache.



## Medical history:

no history of any medical condition ,surgical procedure or hospital administration.

Drug history: NOS.

Allergic history: NOS.



# Dental history:

- RCT from 4 months
- Extraction  
‘no complication associated’.



# Family history:

- Diabetes mellitus.
- Hyper tension.  
    ‘from mother side’

# Social history:

- Married with 5 children.
- Not smoker.

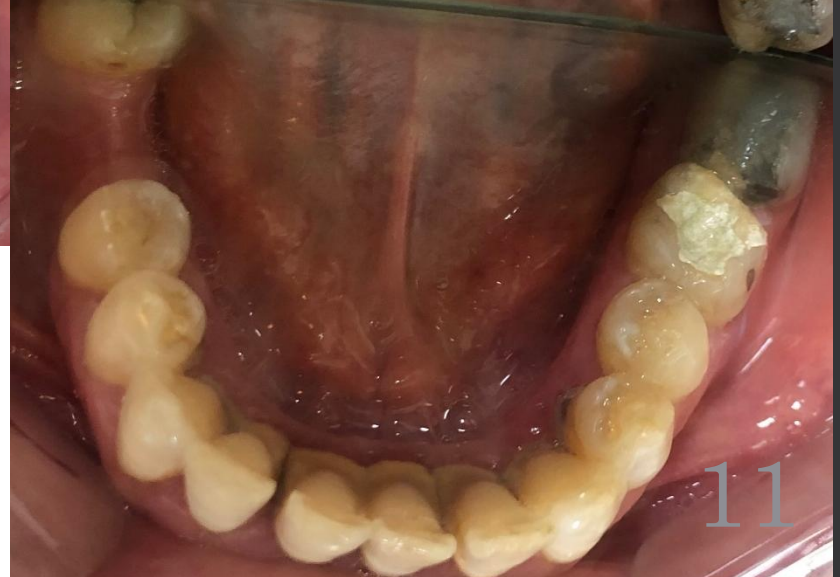
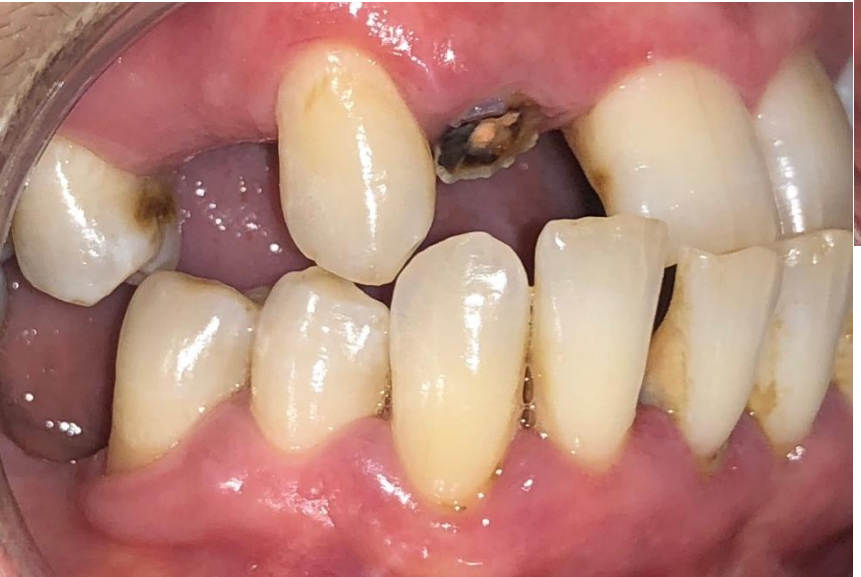
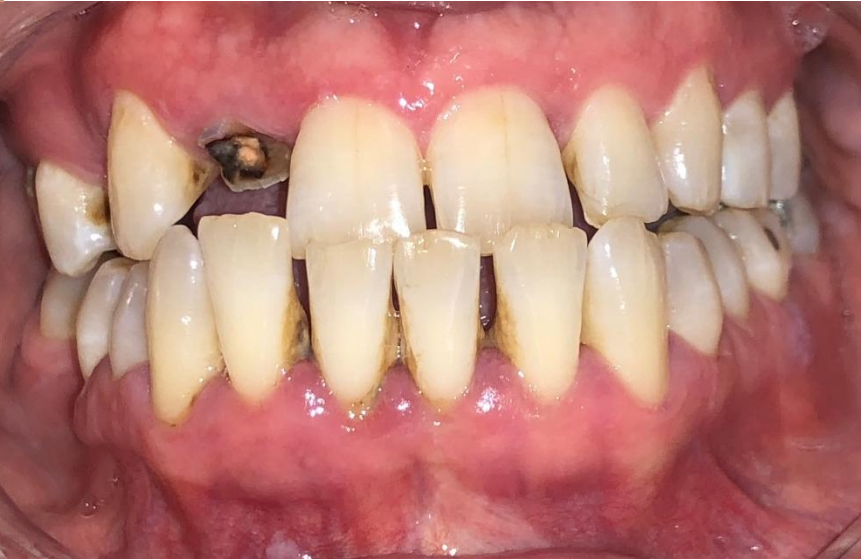
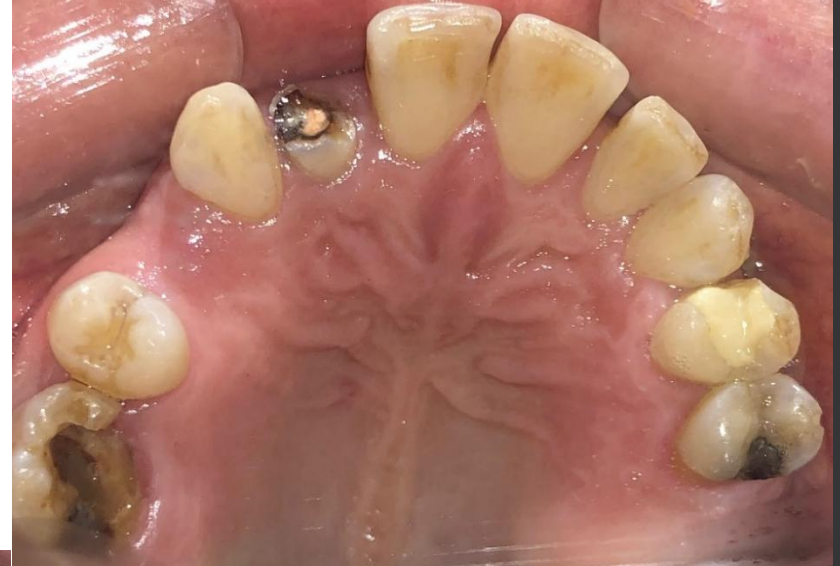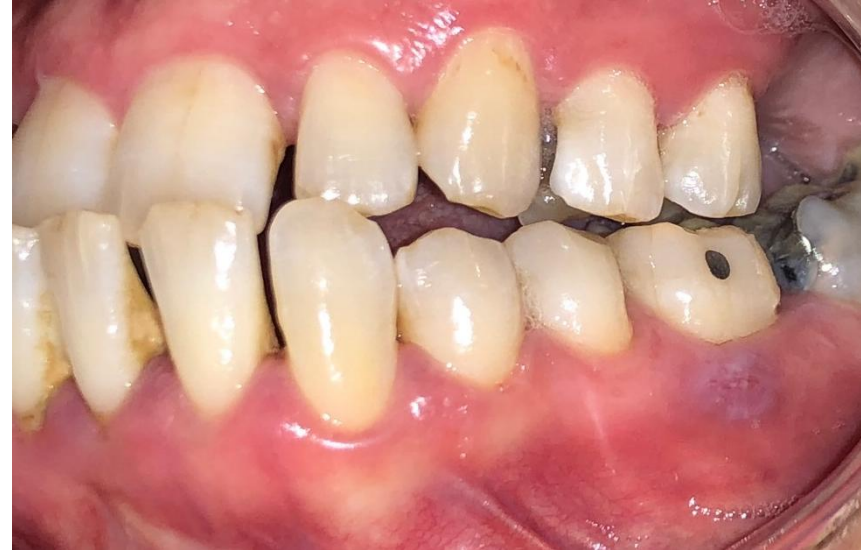extra-oral examination:



- Face: symmetrical.
- Skin: fair , no lesions
- TMJ : no clicking ,no deviation, no subluxation, and not tender to palpation.
- Lymph node: not palpable, not tender to palpation.

intra-oral examination:



# Soft tissue:

- Lips: in-competent
- Labial and buccal mucosa: NOS.
- Hard and soft palate: NOS.
- Tongue : fissured.
- Floor of mouth: NOS.
- Gingiva: generalized rounded margins red edematous, swelling and sinus discharge in lower left side related to lower left 6.

# Oral hygiene index simplification

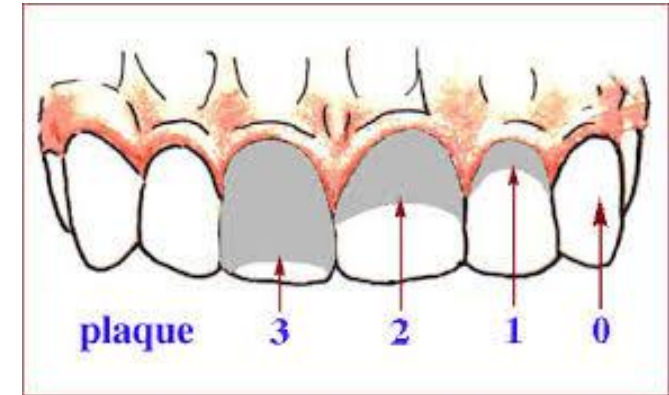


plaque

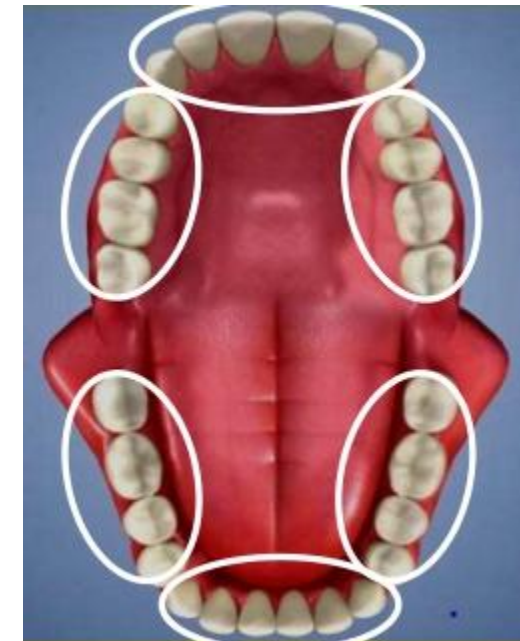16	11	26
	0	1
1	0	1
46	31	36

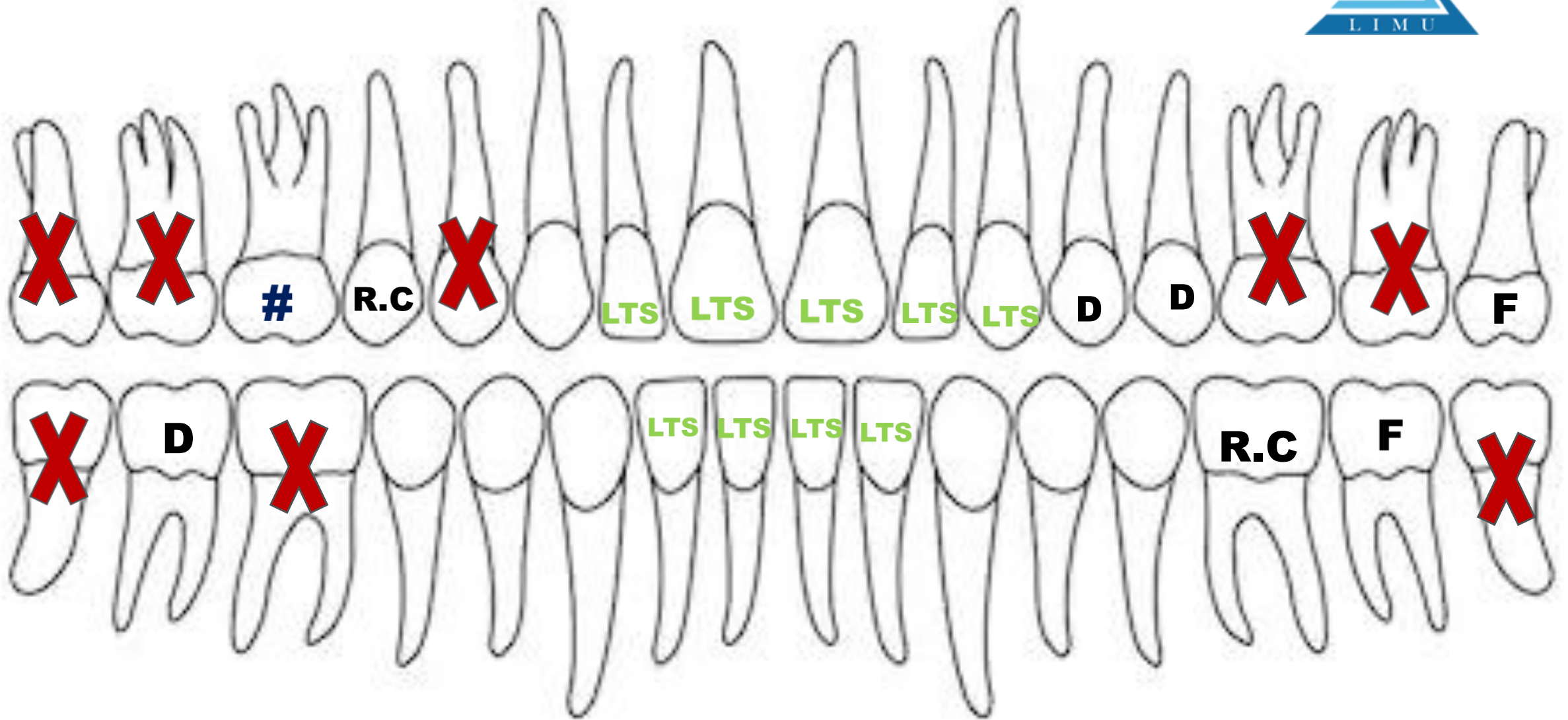
calculus

16	11	26
2	0	1
2	0	2
46	31	36



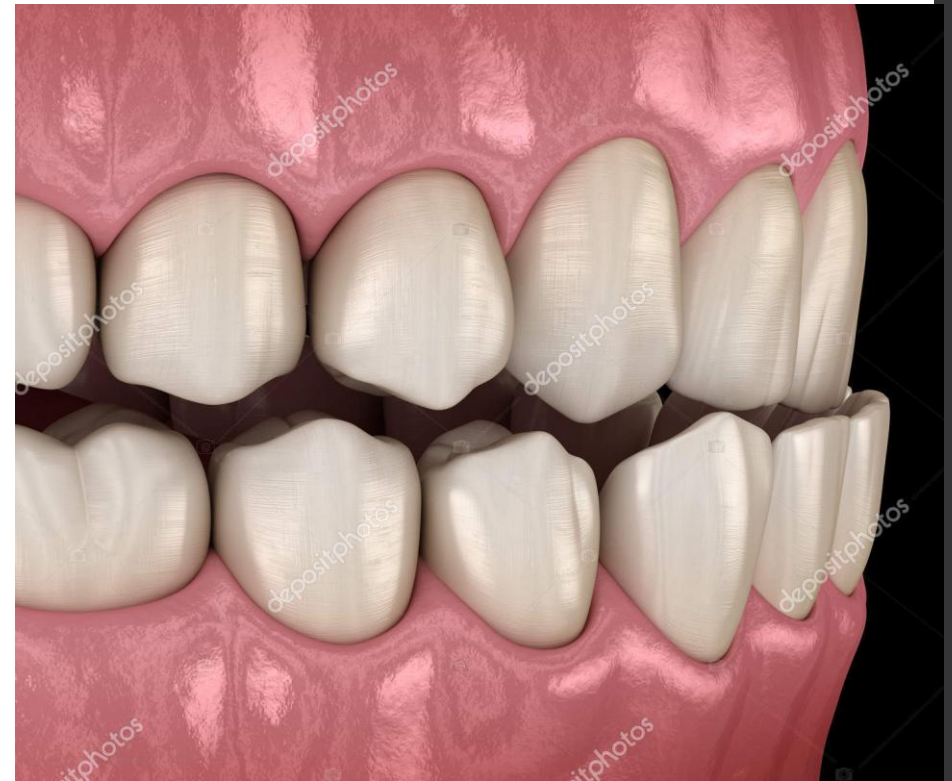Result: 1.66 (fair)





# Hard tissue examination:

- Upper arch: spacing.
- Lower arch: spacing.
- Incisal relationship: class III.
- O.J: -2mm.
- O.B: 2mm



# Hard-tissue examination:

- Canine relationship:

  - Right → class I .

  - left → class II .

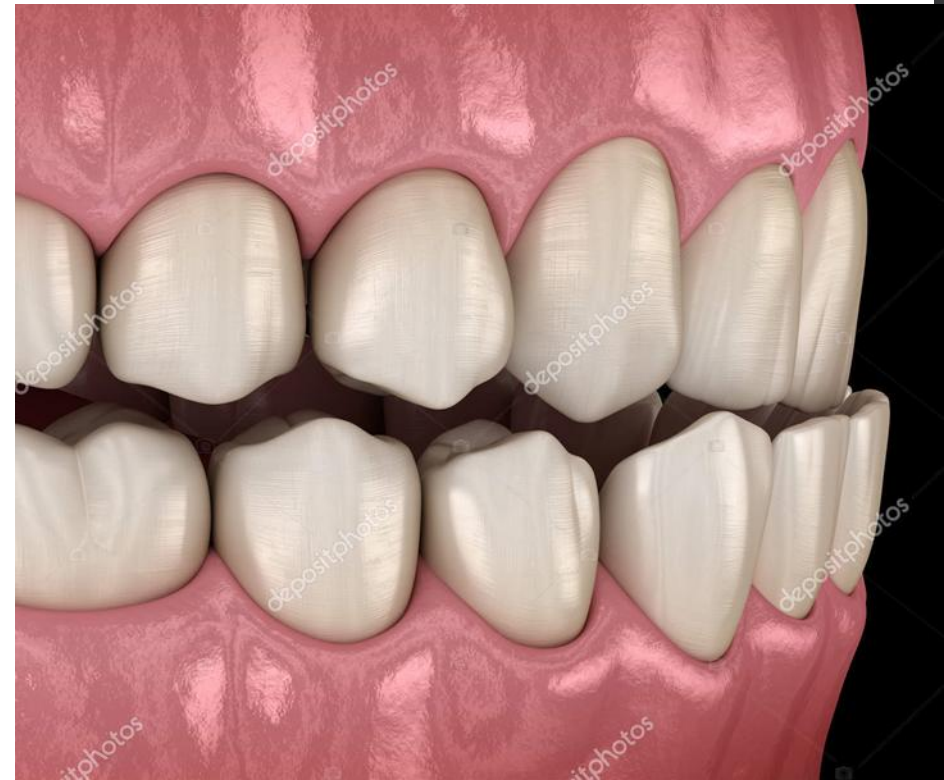- Molar relationship:

  - Can not be detected.

- Central line:

  - upper → coincidence

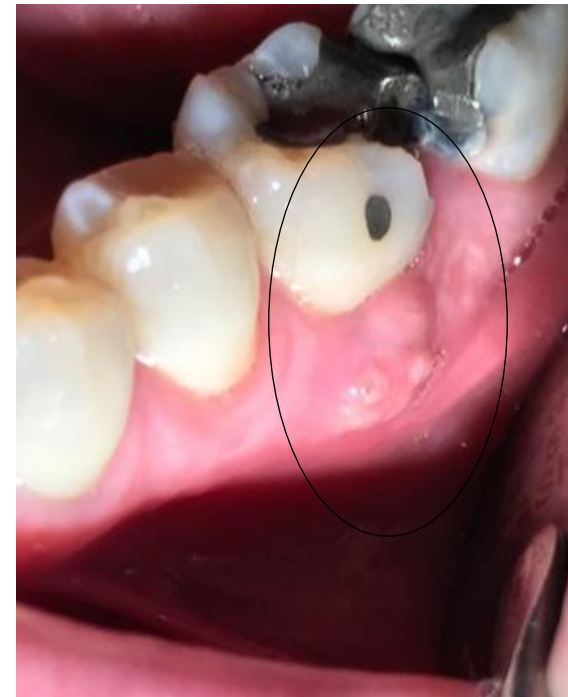  - lower → shift to the right 3mm.





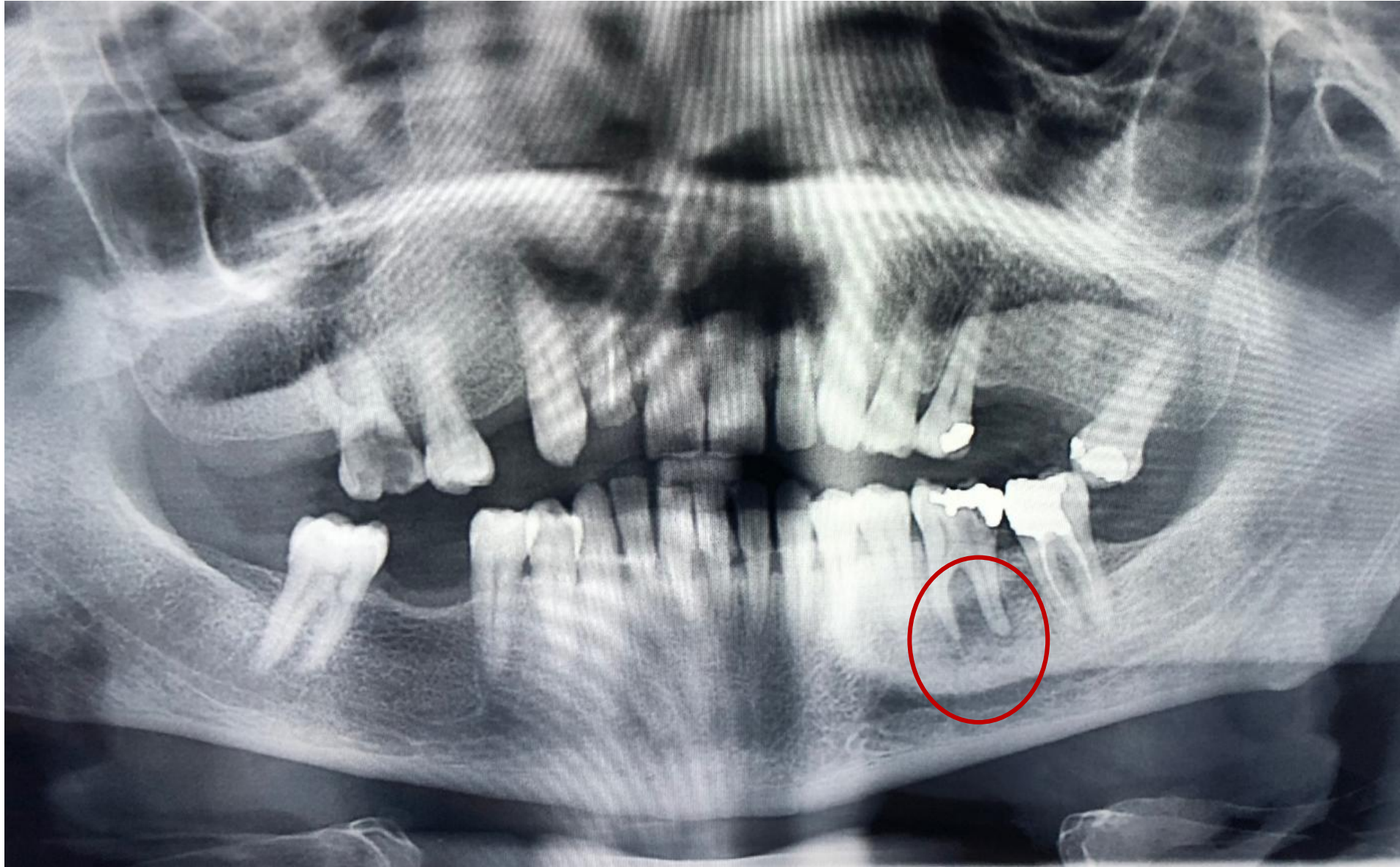
# Differential diagnosis of chief complaint:

- chronic periapical abscess.
- Radicular cyst.
- Osteomyelitis.

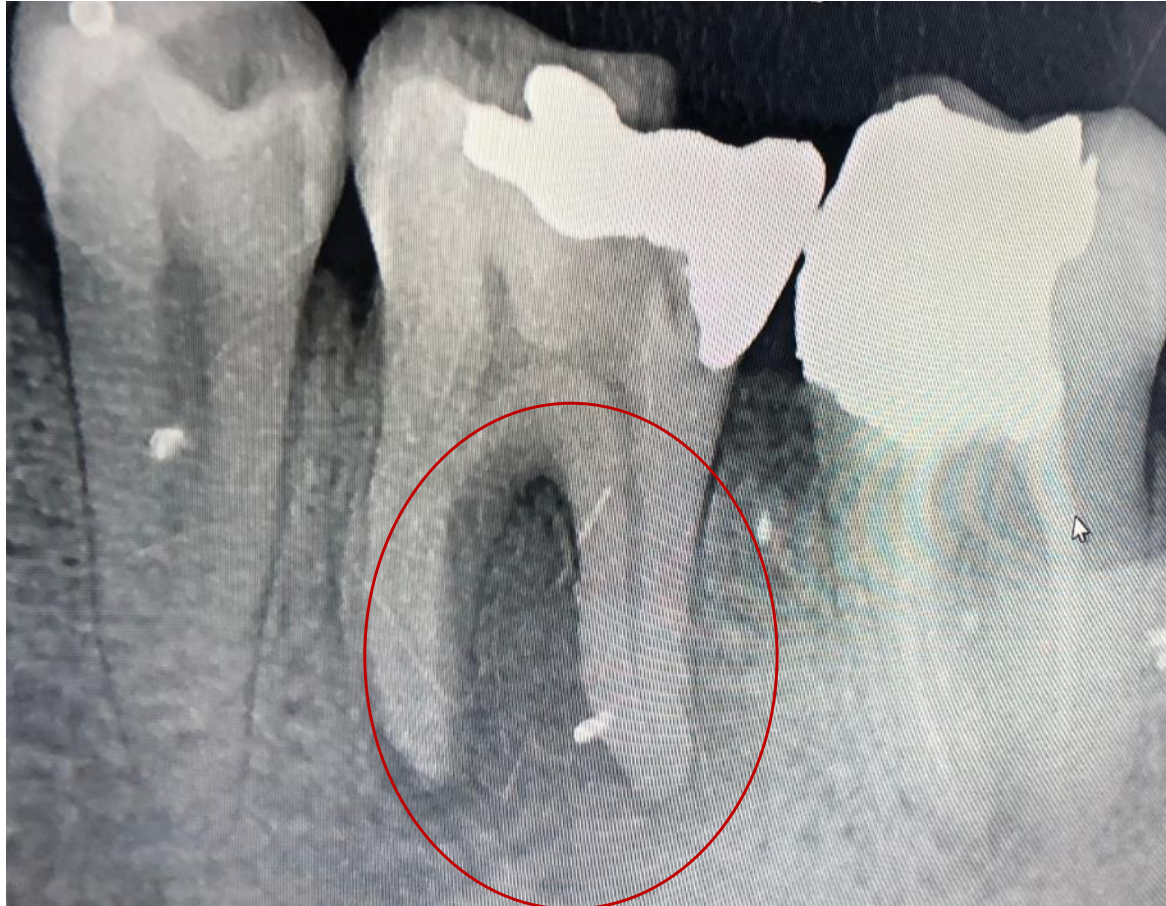


# Diagnostic radiographs

# OPG



# IOPA



## Provisional diagnosis of chief complaint:

- Chronic periapical abscess

# Final diagnosis:

1. Chronic periapical abscess  $\frac{\quad}{6}$
  
2. Generalized mild to moderate chronic periodontitis.
  
3. Failure of RCT  $\frac{2}{\quad}$
  
4. Dental caries  $\frac{5}{7} \frac{4}{5}$

# Final diagnosis:

• Fractured  $\frac{6}{\quad}$

• missing  $\frac{74}{6} \mid \frac{67}{\quad}$

# Treatment plan:

- Emergency phase:

root canal treatment  $\frac{\quad}{6}$

- phase I :

scaling, root planning, OHI, patient education and motivation.

- Phase II :

extraction of  $\frac{6}{\quad}$



# Treatment plan:

- phase III :

endo-dontic re-treatment  $\frac{2}{|}$

Restoration :  $\frac{5 | 4 5}{7 |}$

replacement of missing teeth :  $\frac{7 6 4 | 6 7}{6 |}$

coronal restauration for endo-dontic treated tooth  $\frac{2}{|}$

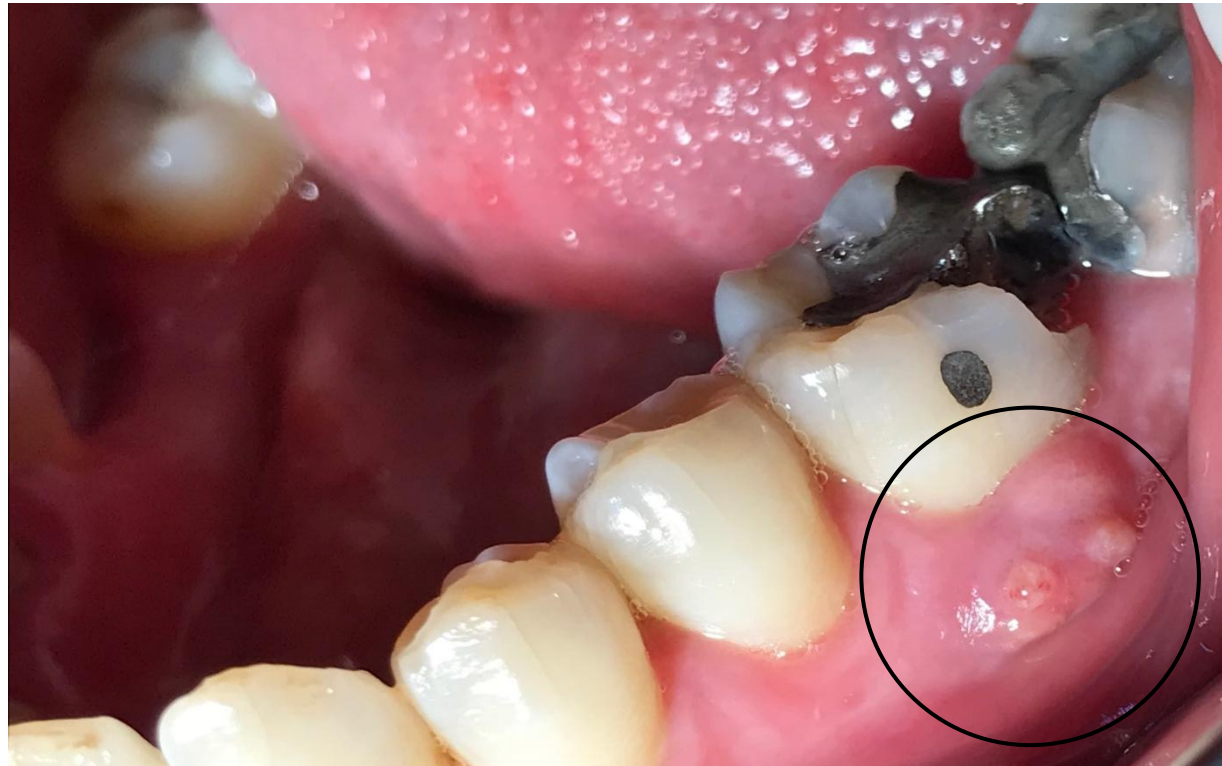
# Treatment plan:

- Phase IV ;  
Maintenance and follow up.
- Orthognathic surgery and Orthodontic treatment.

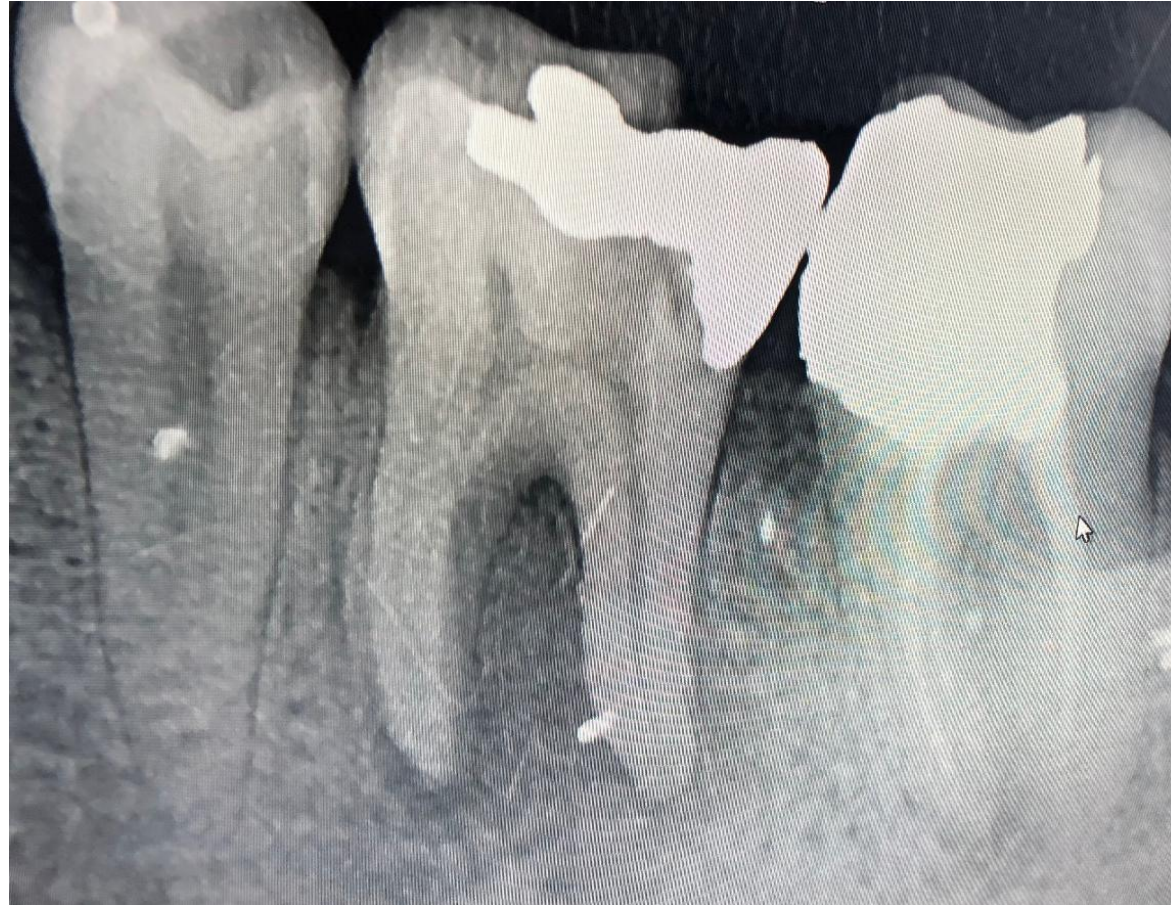
Emergency Phase



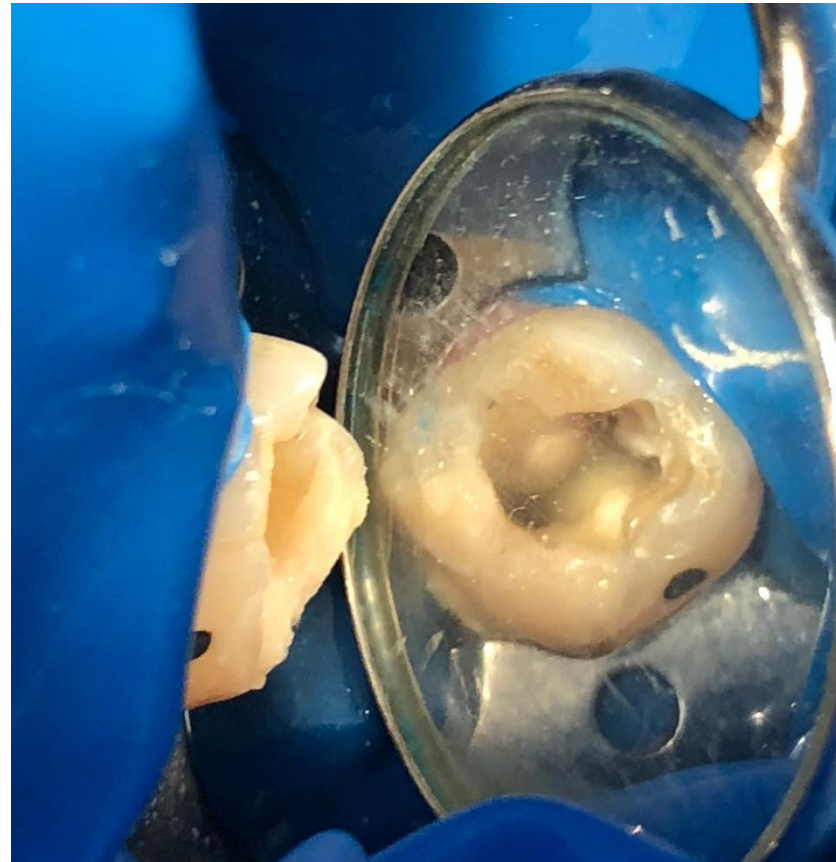
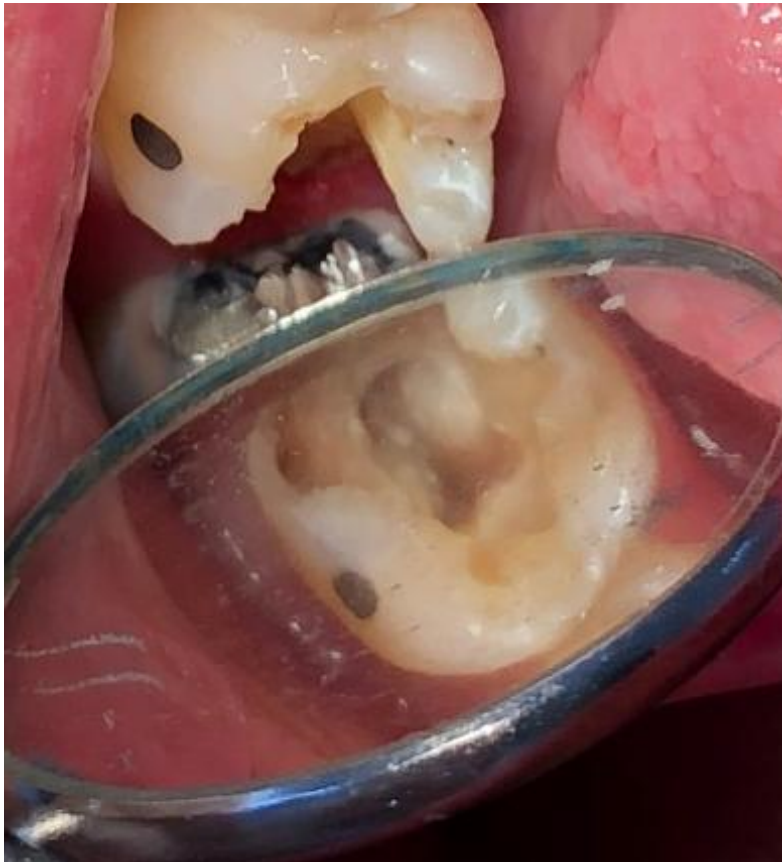# Clinical picture



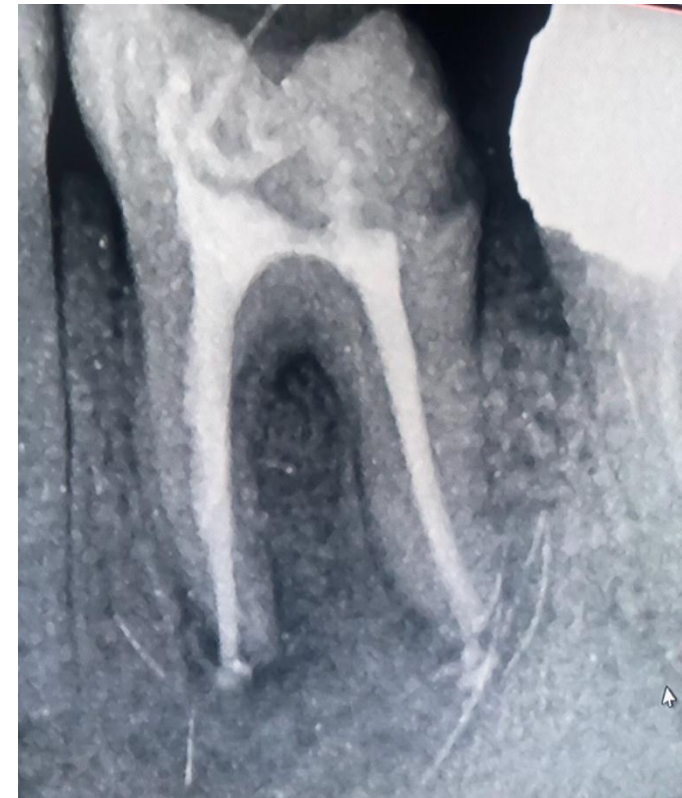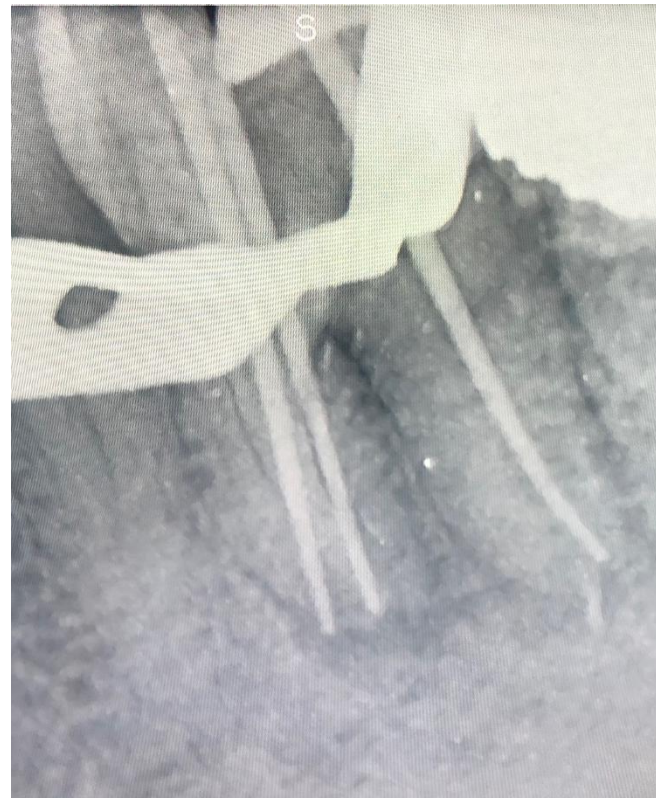
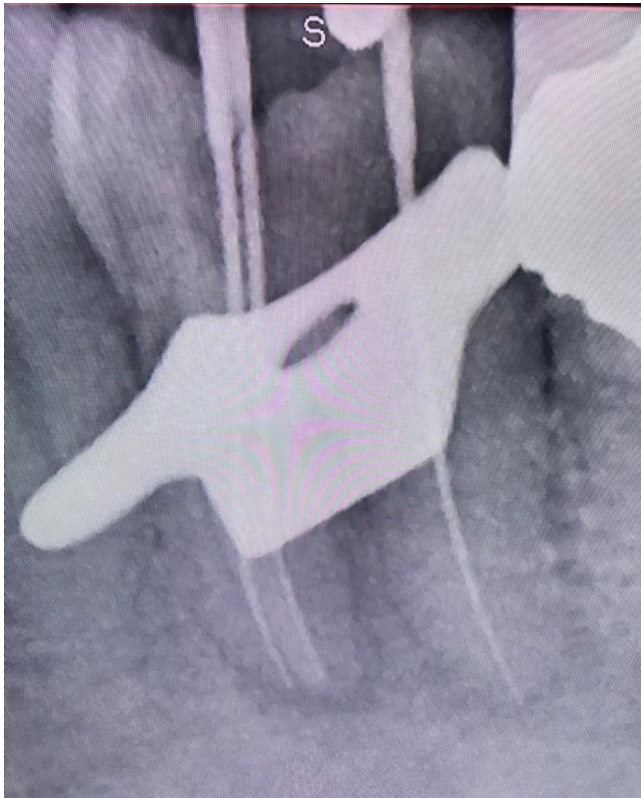# Radiograph

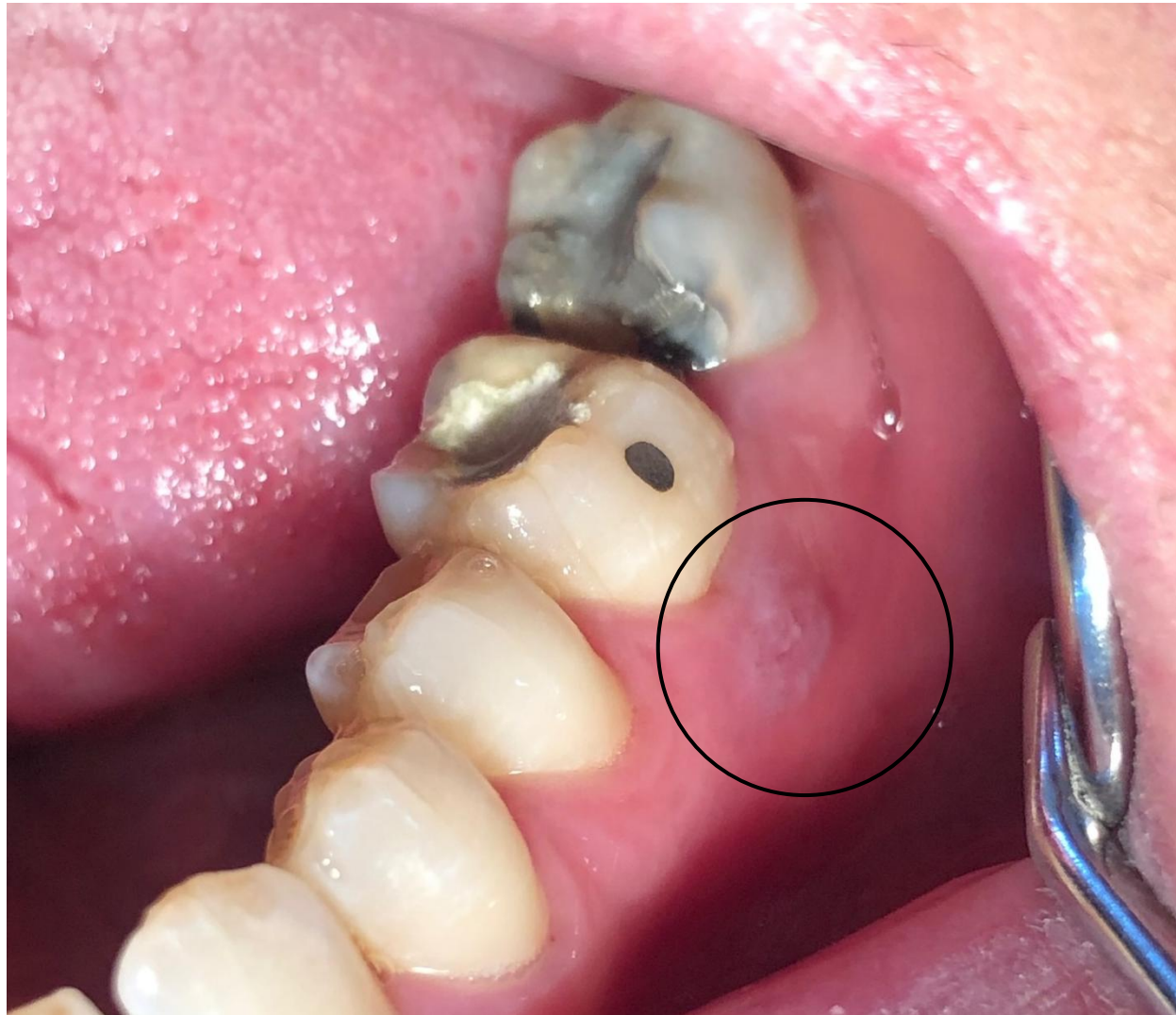

# Access cavity



# Endo treatment







# Phase I



# Oral hygiene practice:

tooth brush: soft

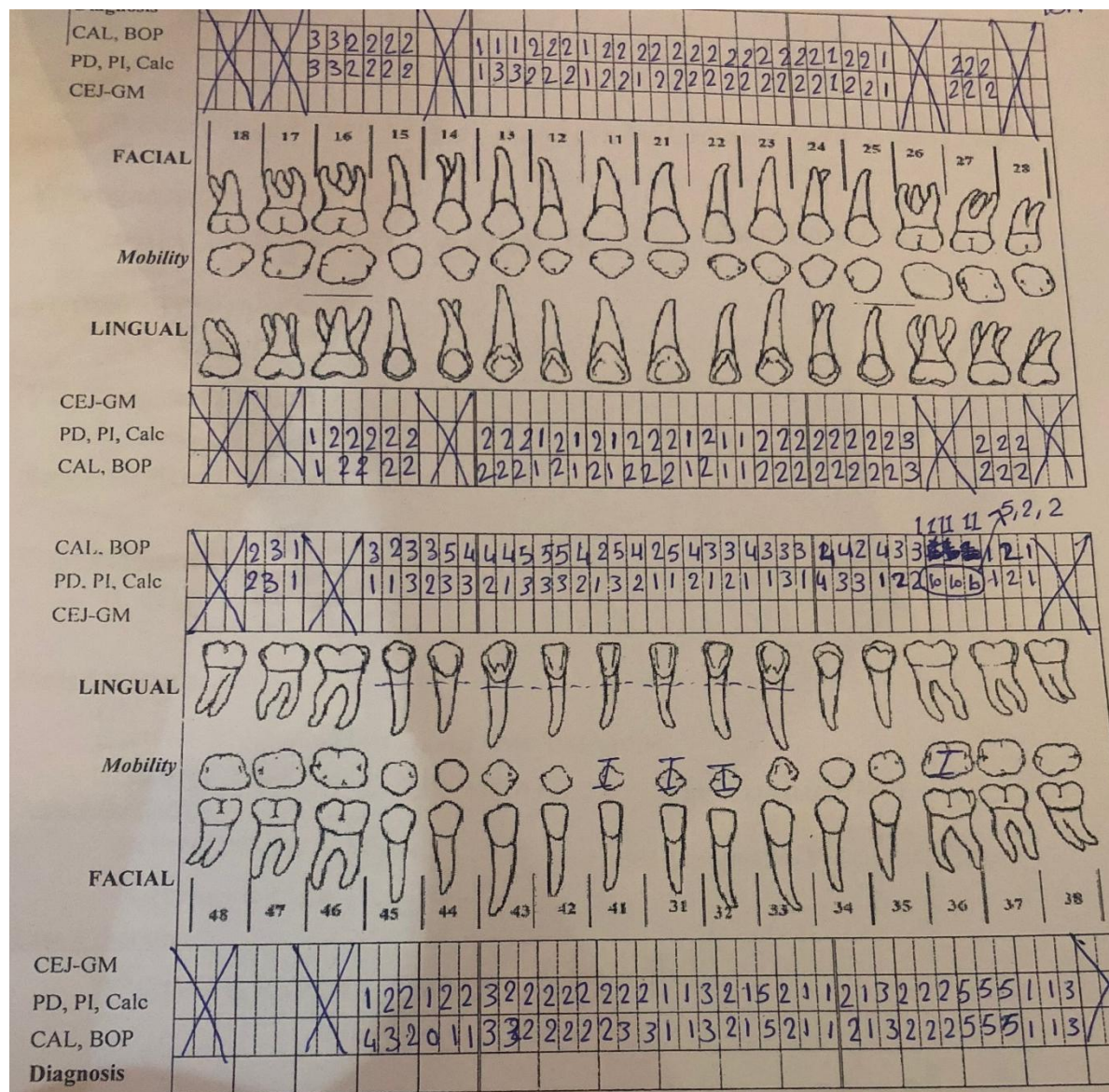
Brushing method: horizontal

Type of dentifrice : regular tooth paste “ crest”

Frequently: occasionally

Any other : no

# Periodontal chart:



GM- Gingival Margin. CAL- Clinical Attachment Loss. CEJ- Cementoenamel Junction. PD- Probing Depth  
 PI- Plaque, if presents put \* Calc- Calculus, if presents put \*. BOP- Bleeding on probing, if presents put red

# Periodontal status: (clinical examination)

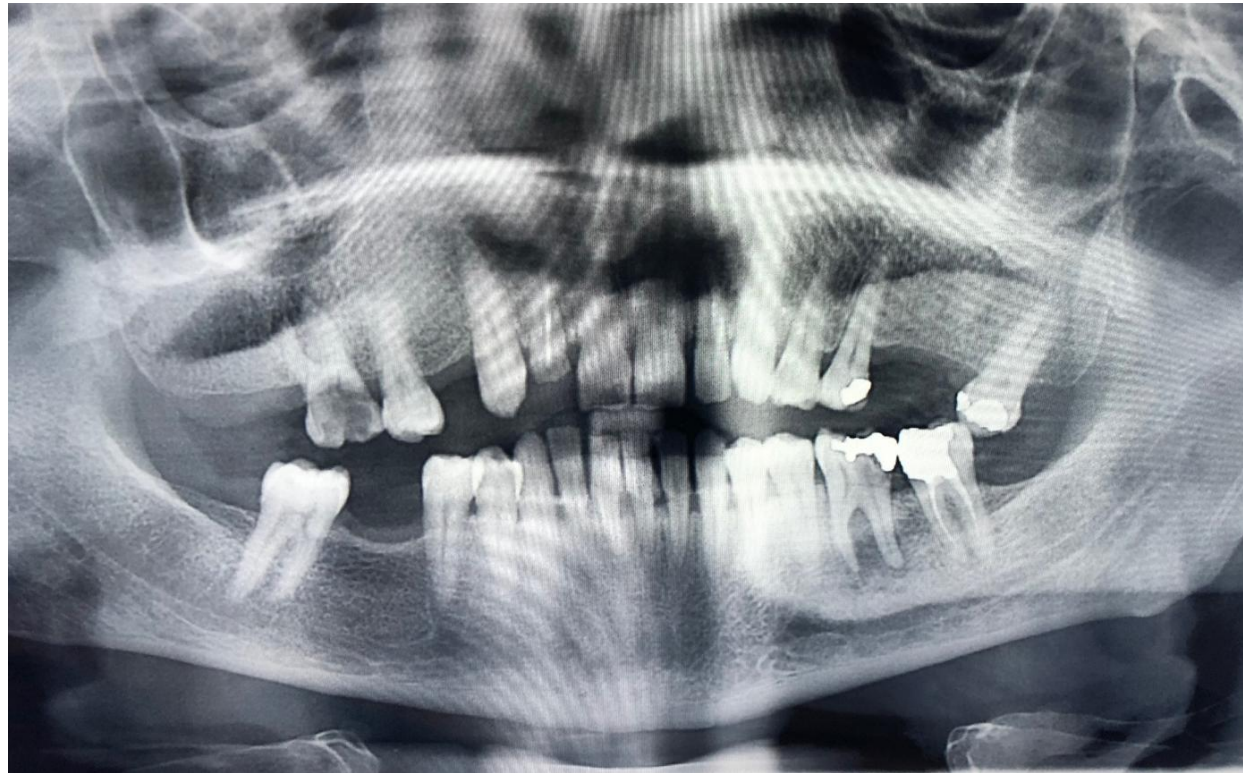- Mild to moderate Generalized attachment loss

- Severe attachment loose related to  $\frac{\quad}{3\ 2\ 1\ | \ 1\ 6}$

- Mobility grade I related to :  $\frac{\quad}{1\ | \ 1\ 2}$  , Mobility grade II  $\frac{\quad}{\quad\quad\quad | \ 6}$

furcation involvement: absent

# Radiographic examination:



Generalized mild to moderate horizontal bone loss

# Diagnosis:

Generalized mild to moderate chronic  
periodontitis

# Prognosis:

- Good prognosis to all teeth , except ;

$\frac{\quad}{6}$  questionable .

- Over-all prognosis : **Good**

# Treatment:

- Scaling.
- Root planning.
- OHI.
- Patient education and motivation



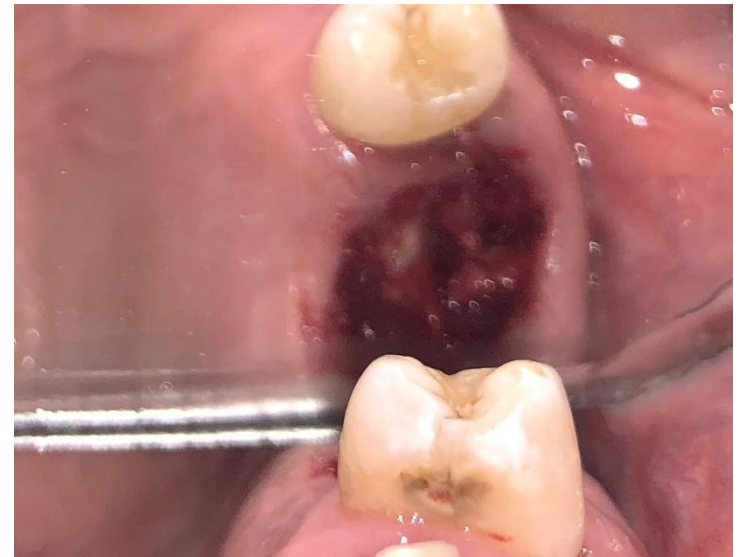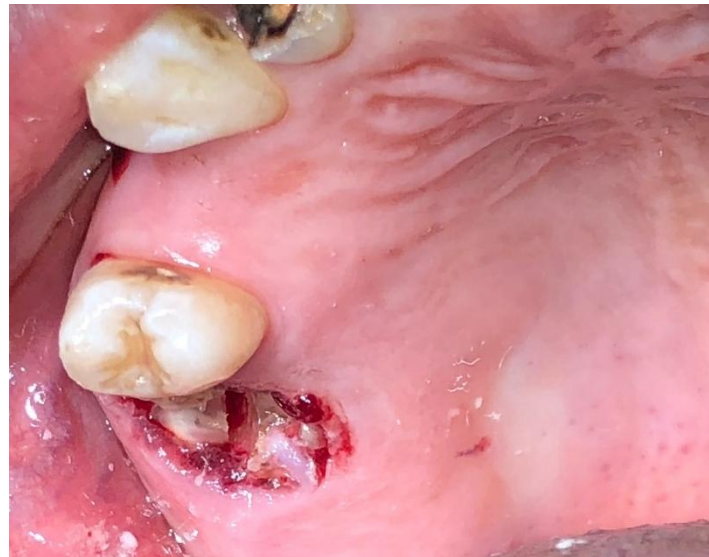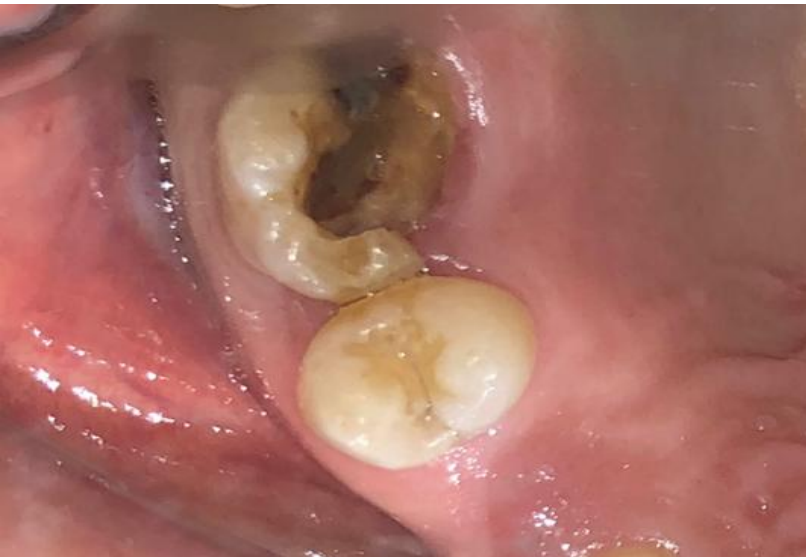# Re- evaluation after 3 weeks:

- “Generalized decrease in CAL.
- improvement in oral hygiene.
- Gingival curettage to pocket related to  $\frac{\quad}{6}$

# Phase II

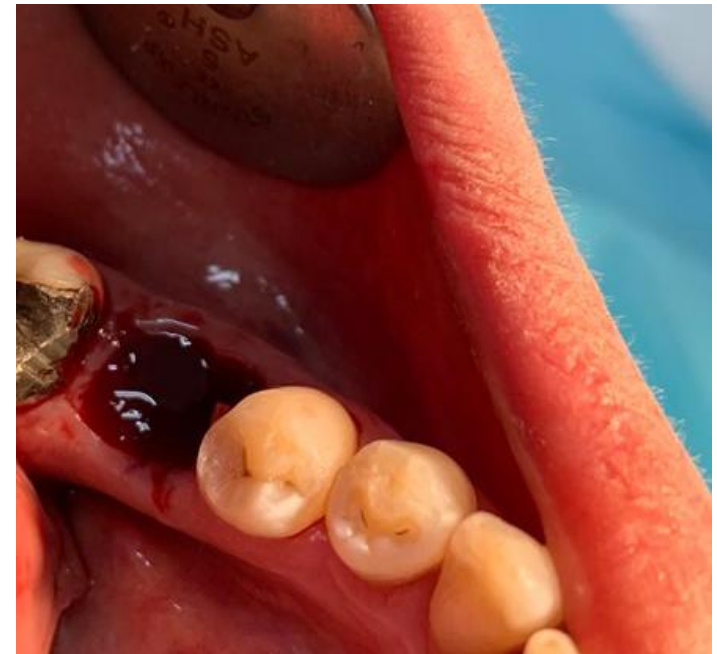
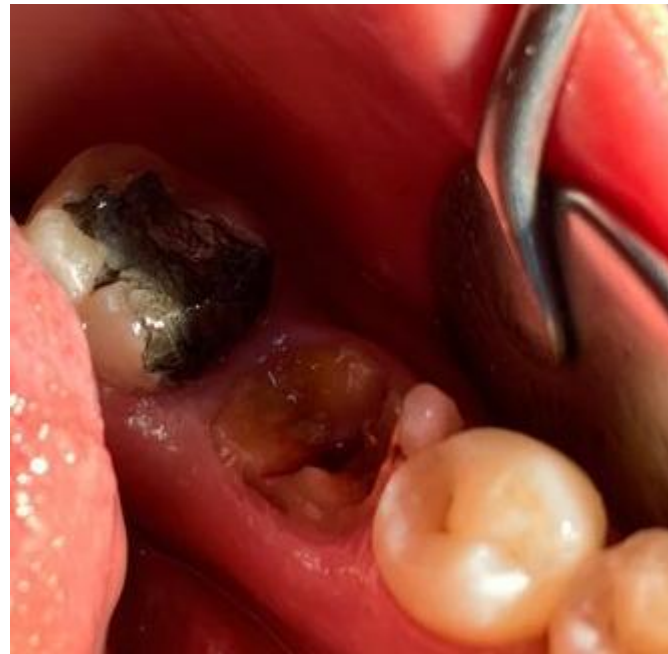
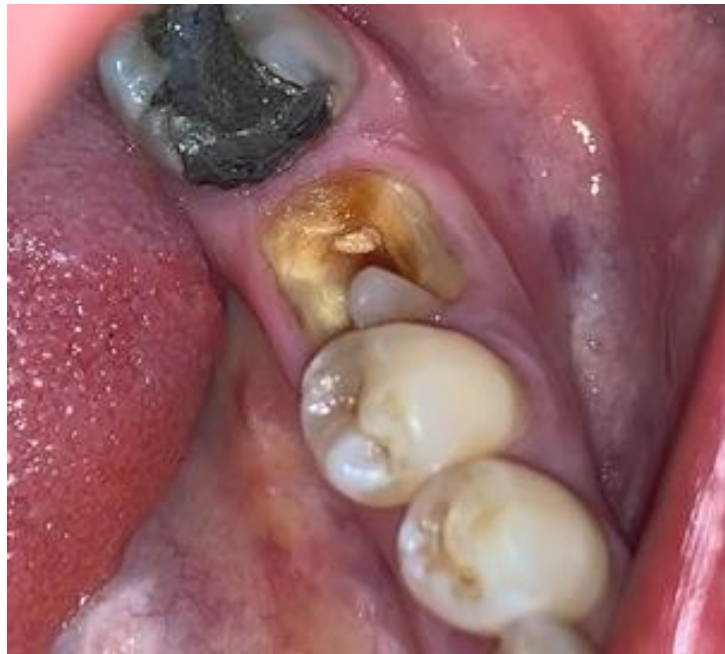Extraction of  $\frac{6}{+}$



extraction

$$\frac{\quad}{6}$$



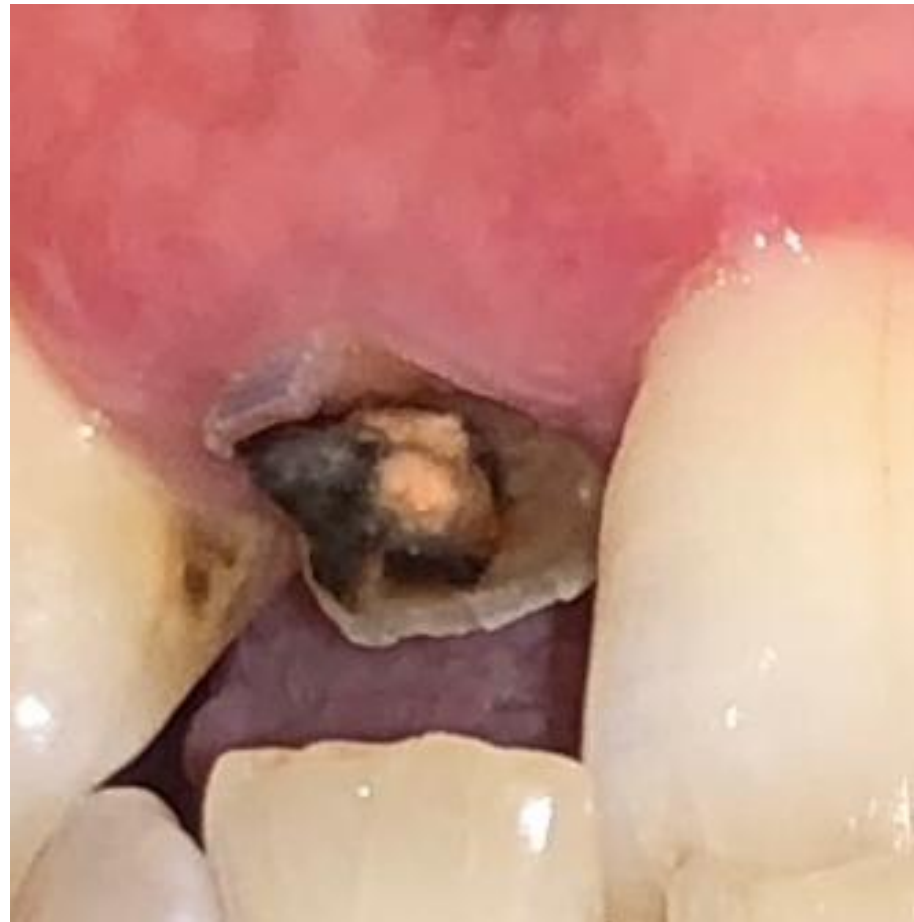# Phase III

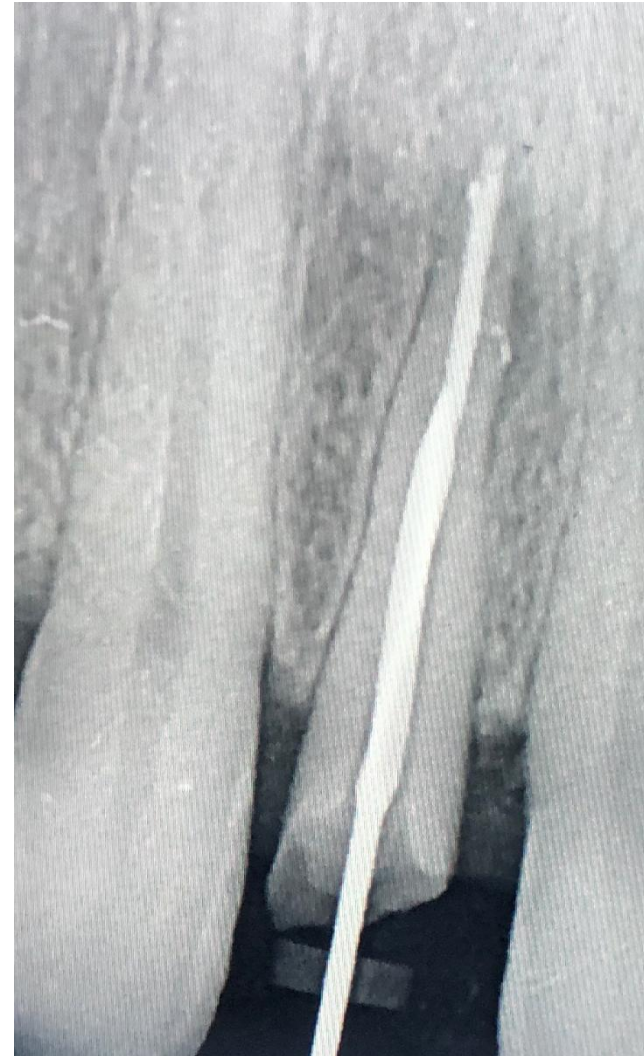
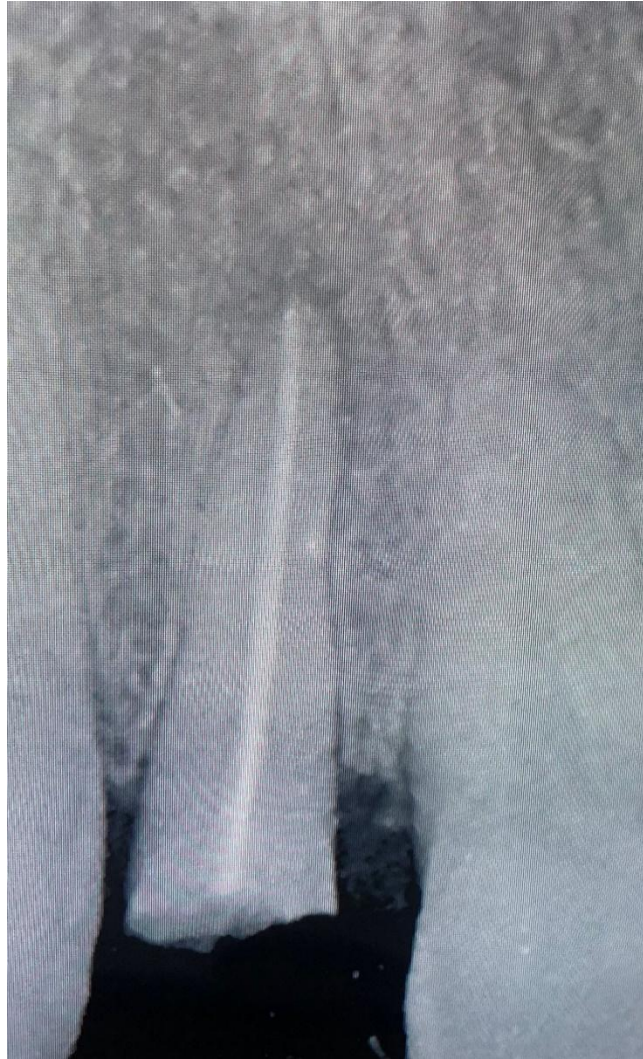

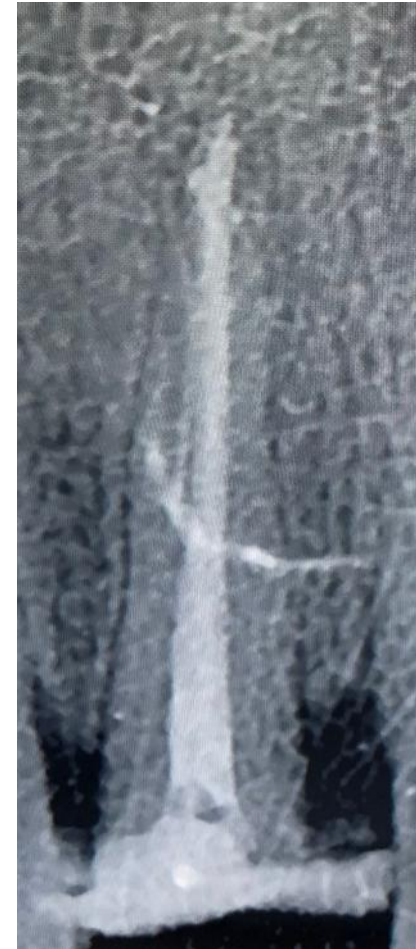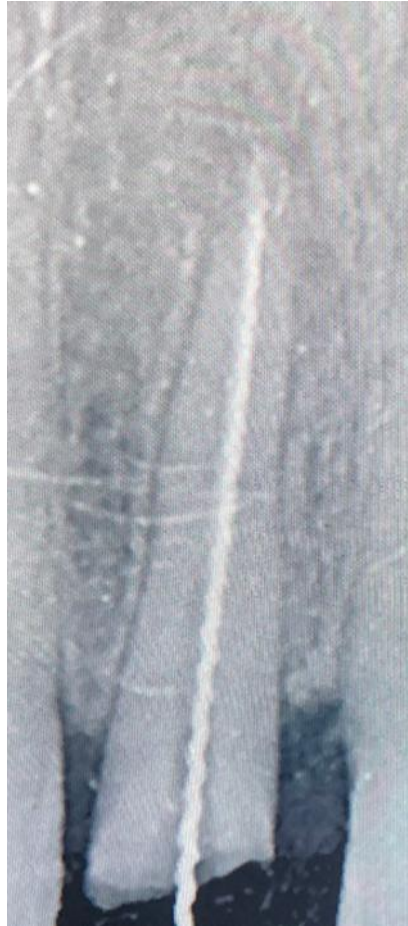# Endodontic re-treatment $\frac{2}{|}$



# Clinical photograph

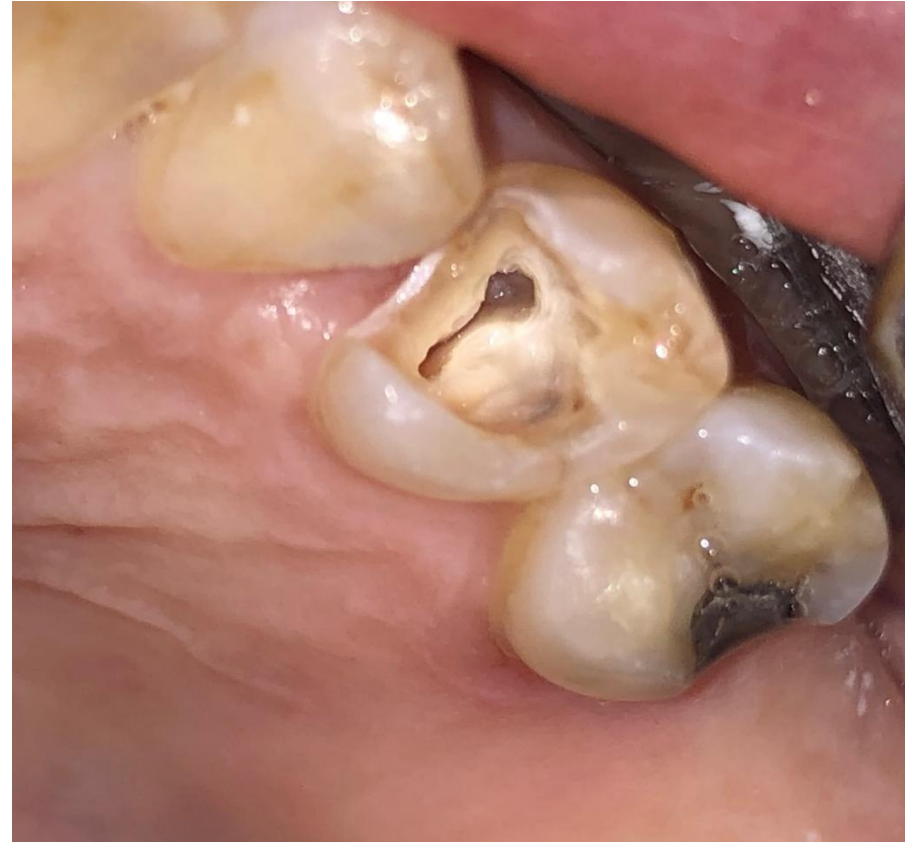
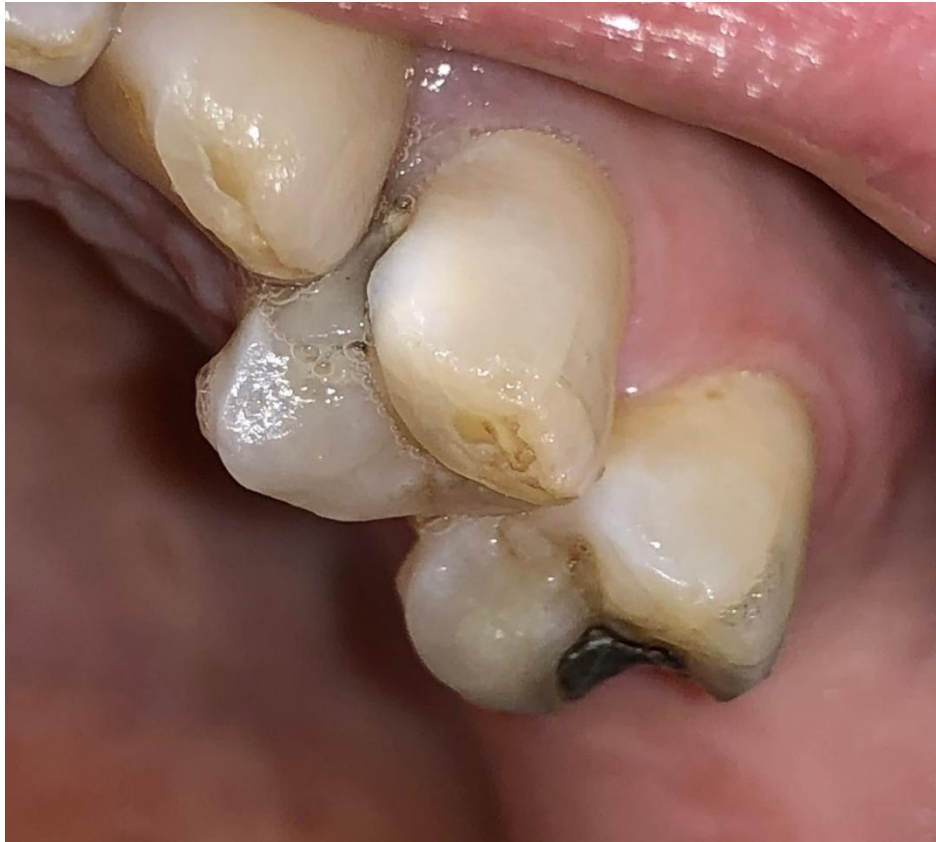




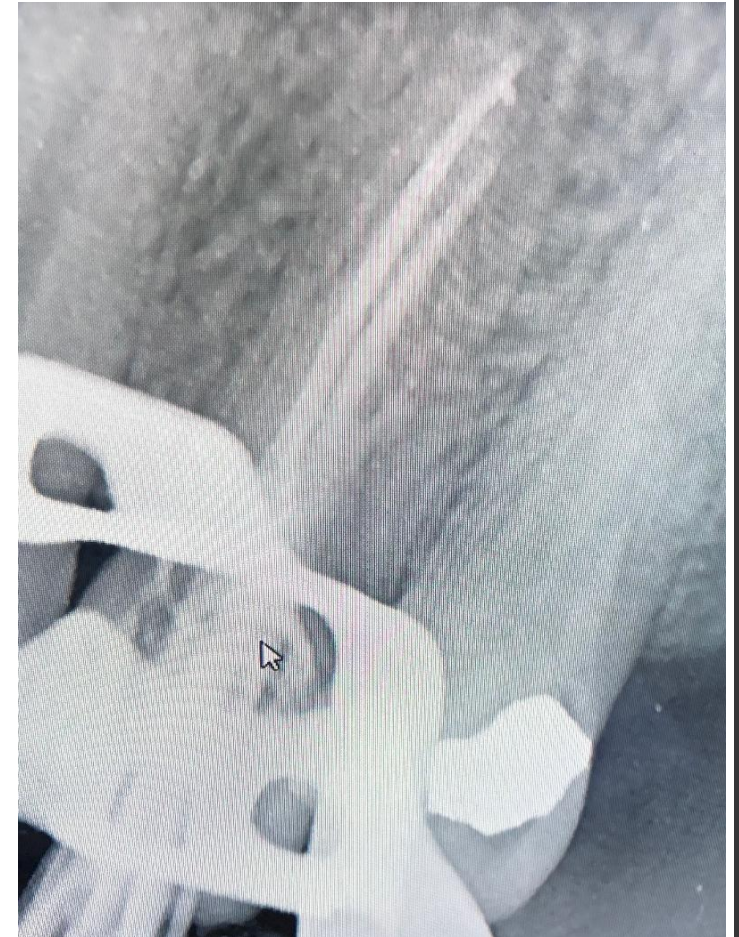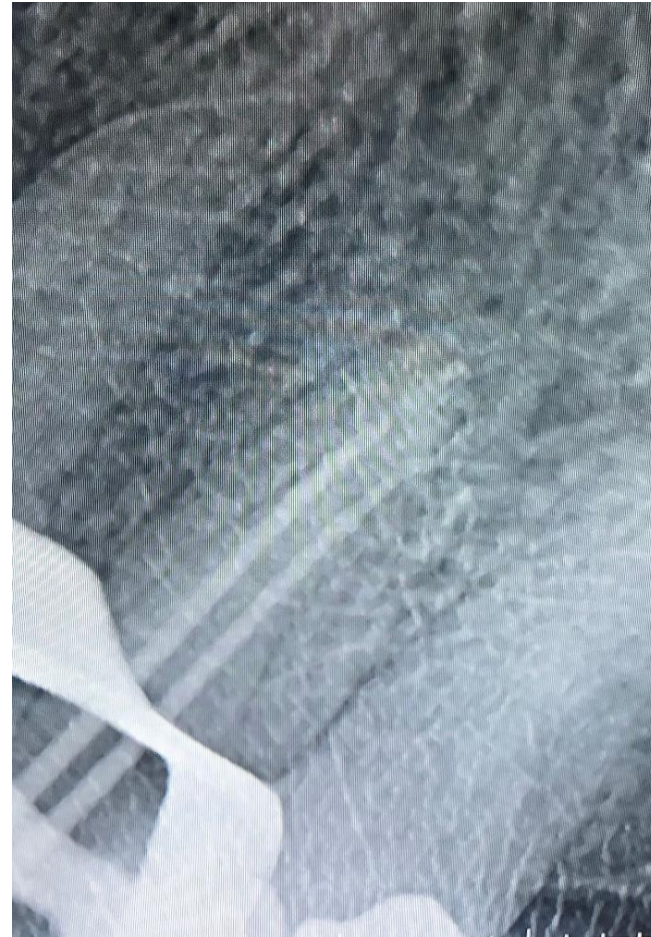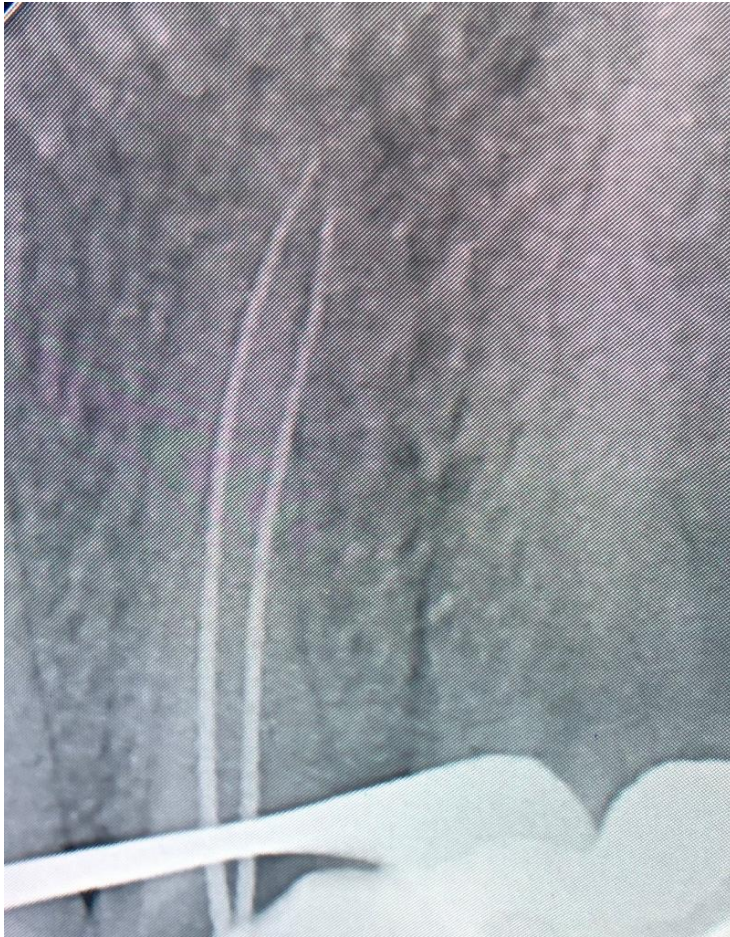Endodontic treatment  $\frac{\quad}{4}$

# Access cavity

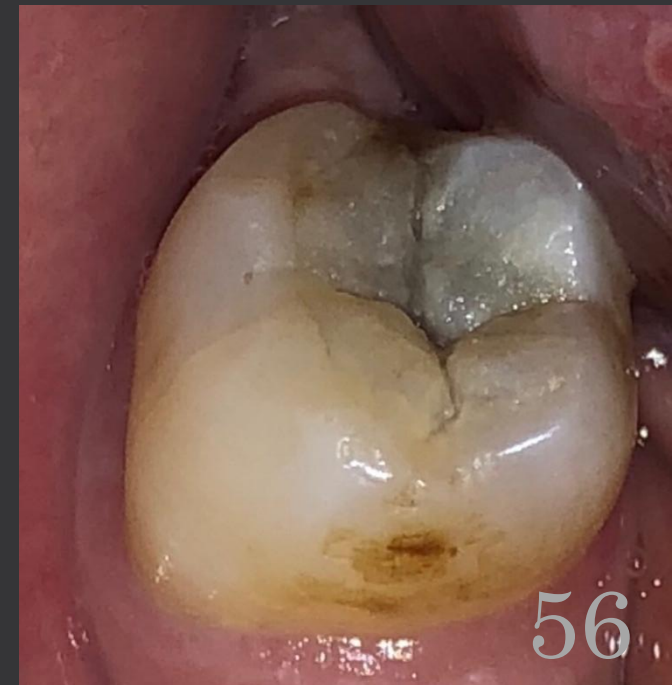

# Endodontic treatment

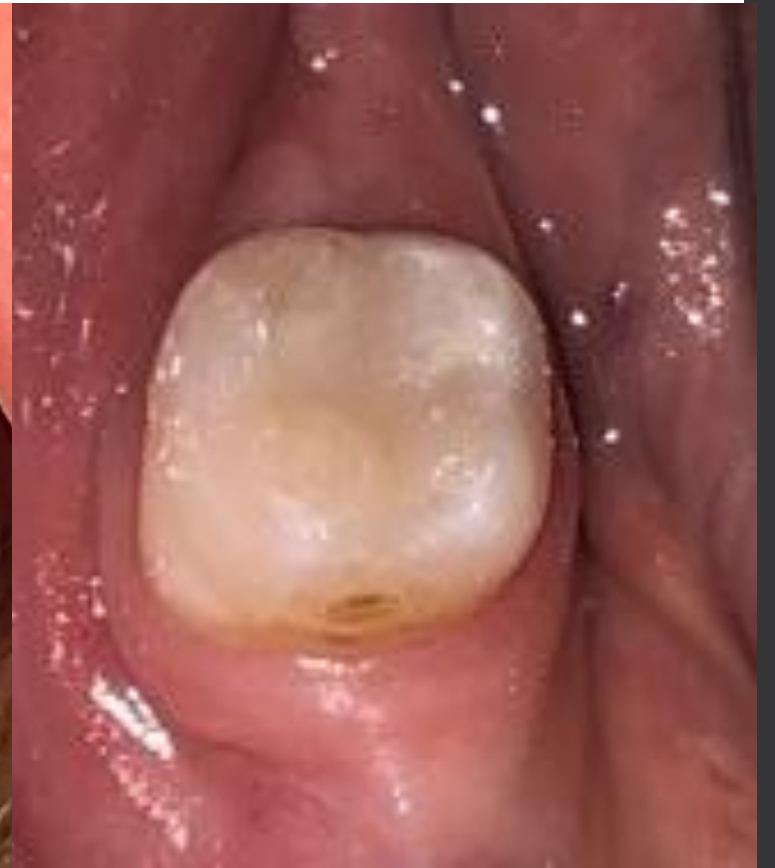
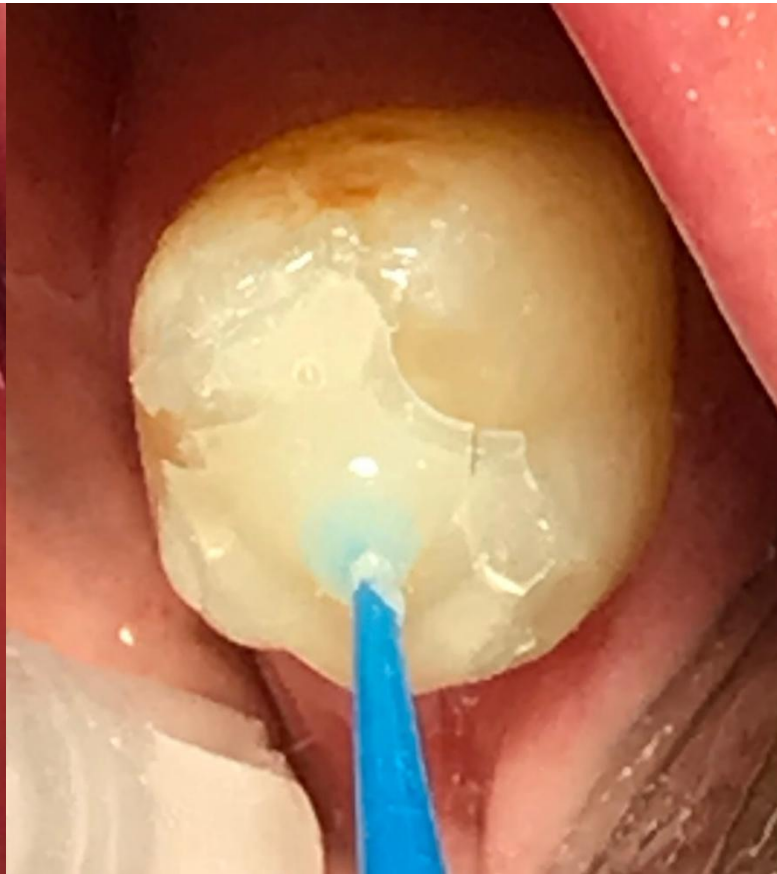
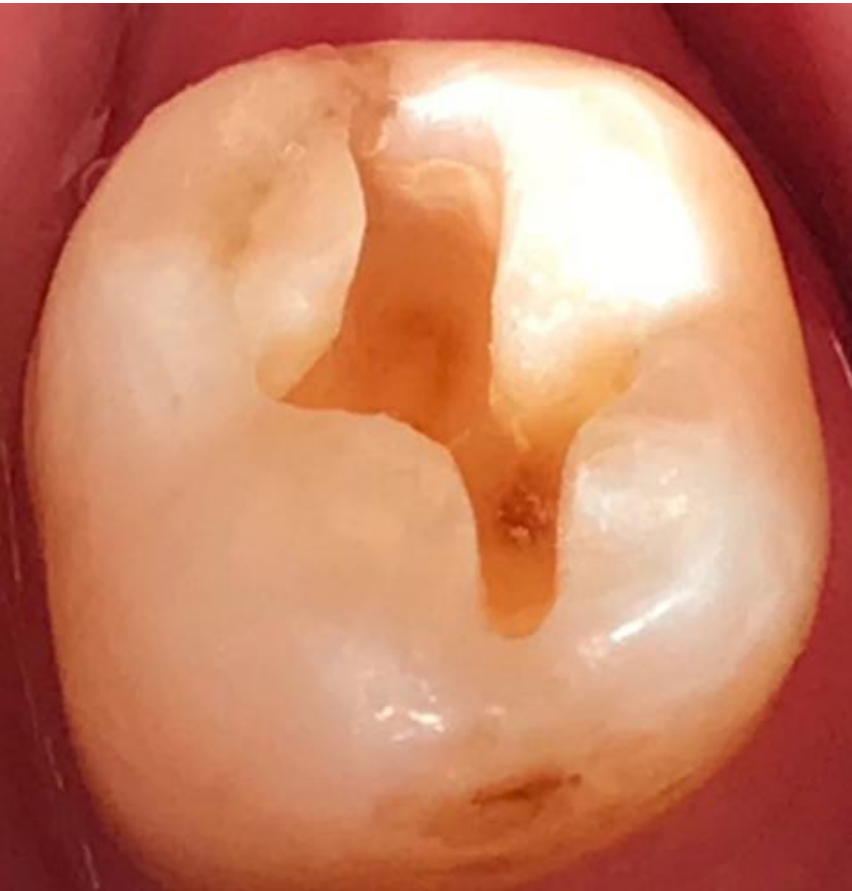# Composite restoration

Composite restoration  $\frac{7}{|}$   
“by using stamp technique”

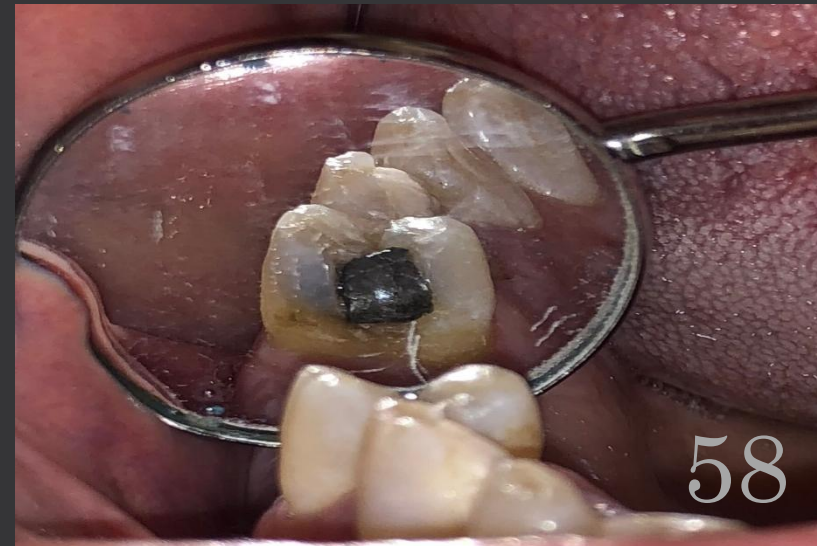




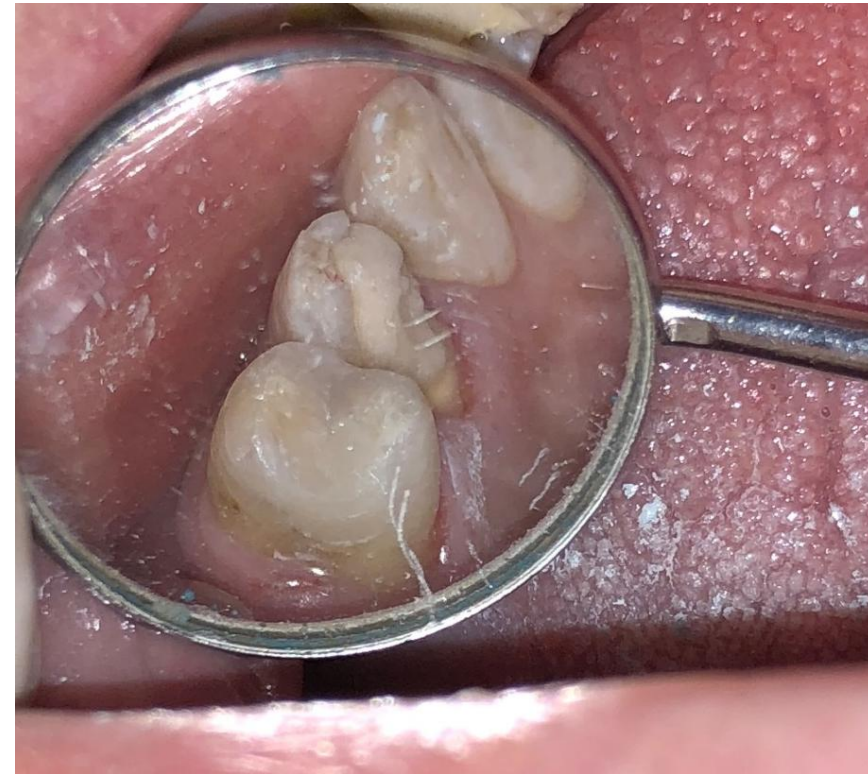
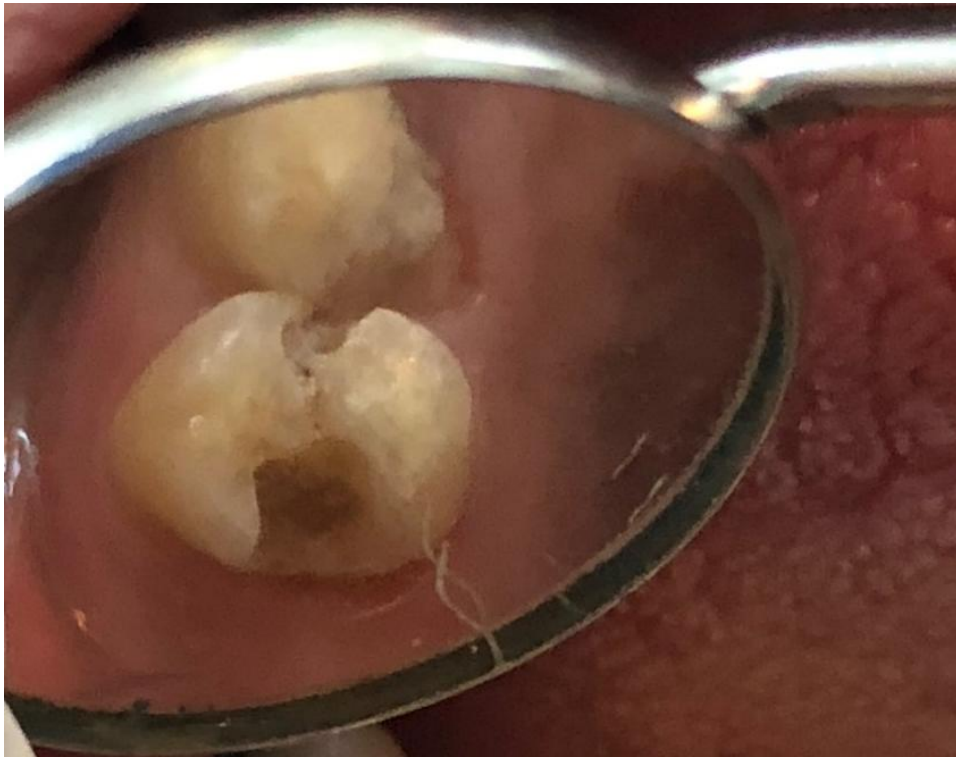Composite restoration

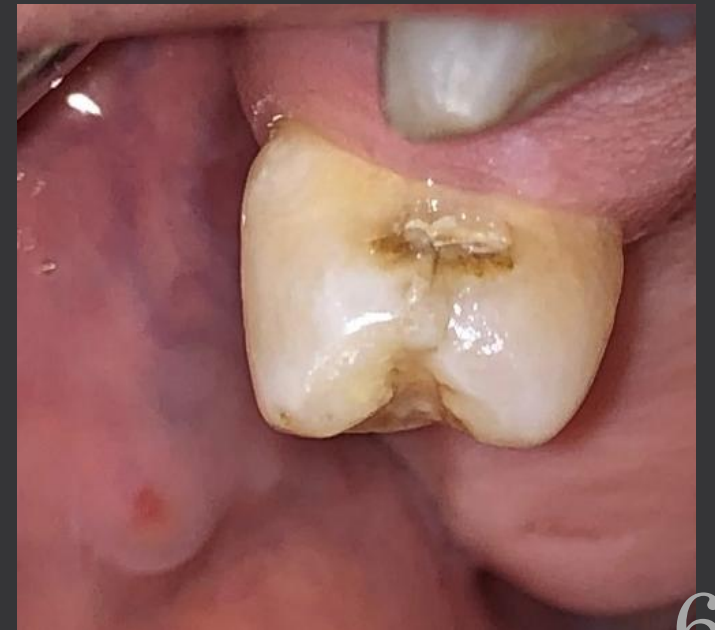5

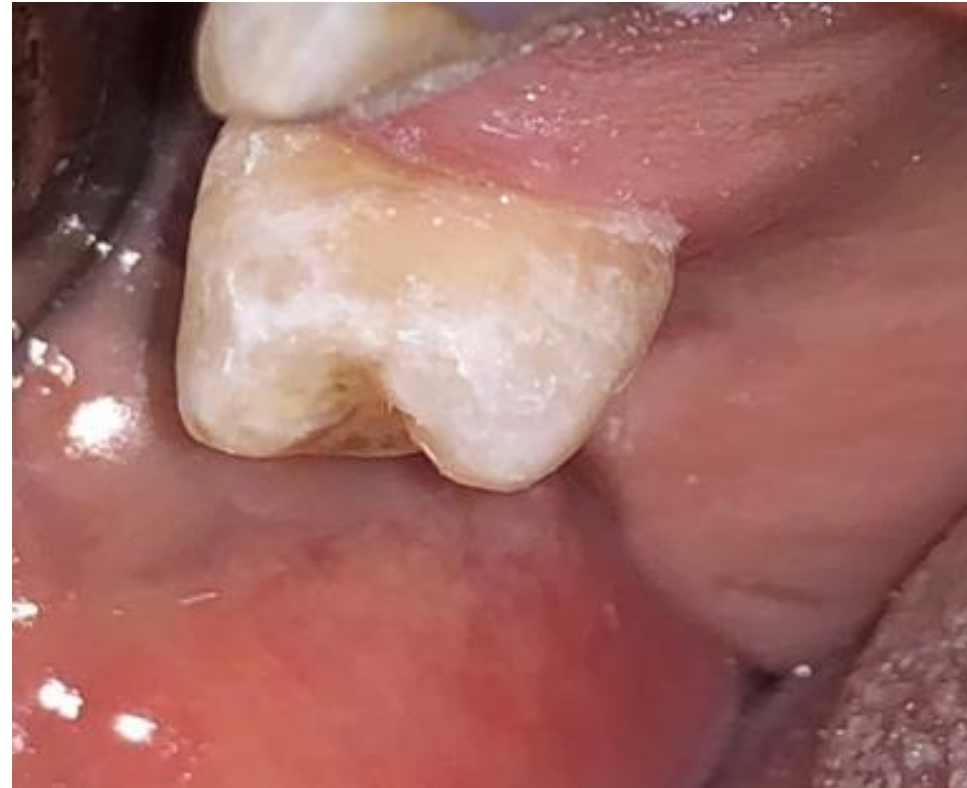
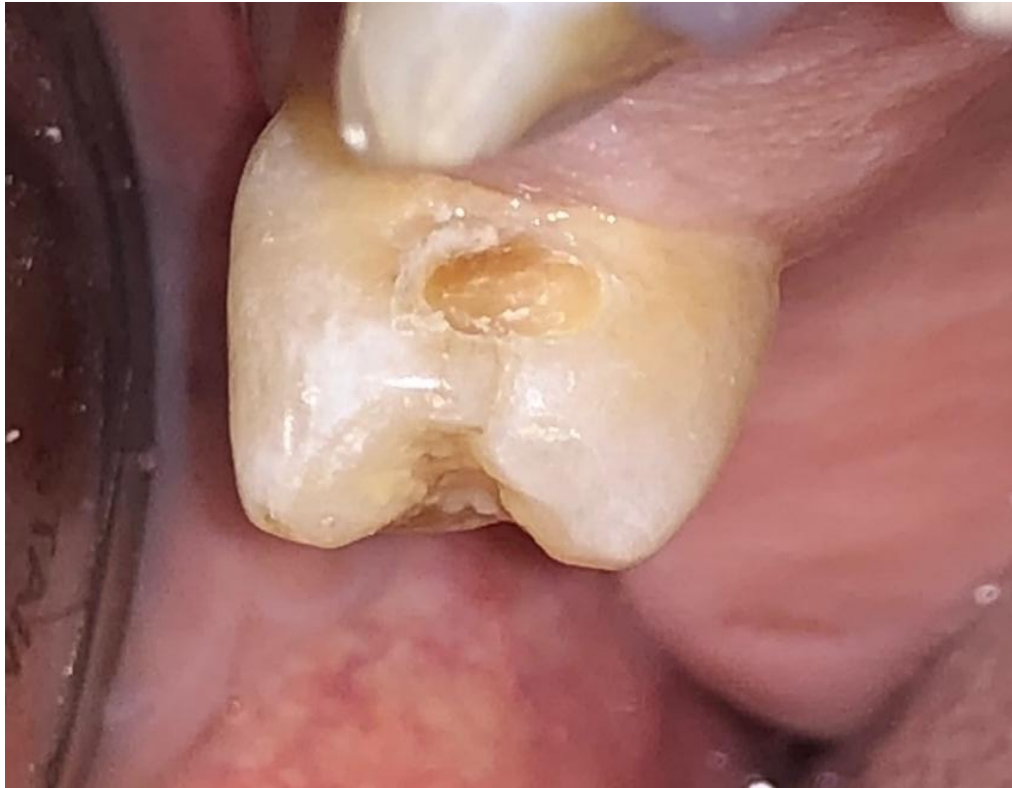
58

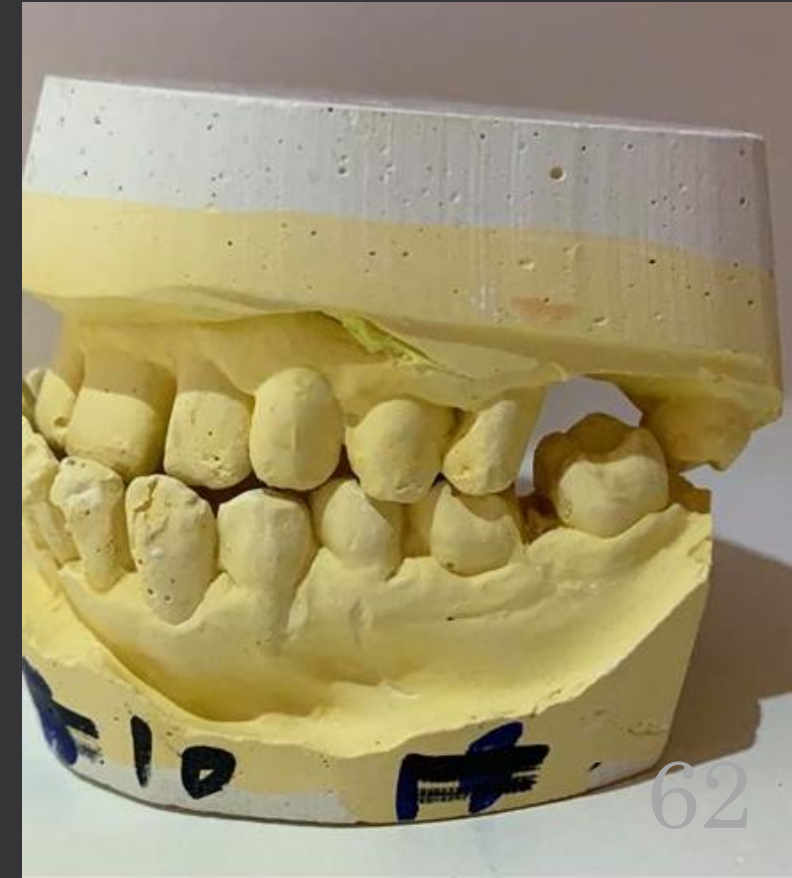

Composite restoration 5

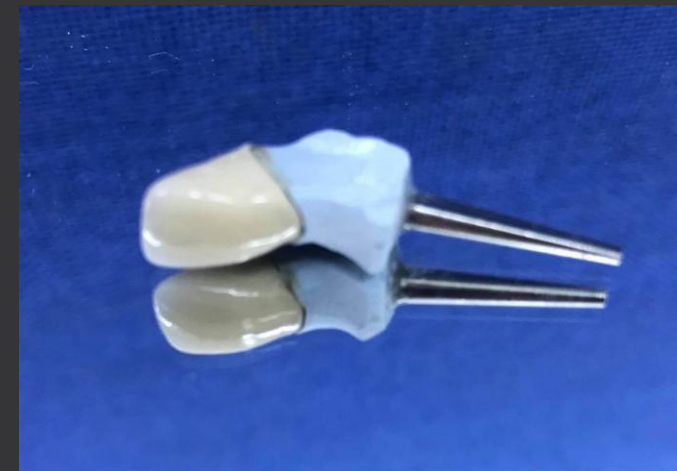




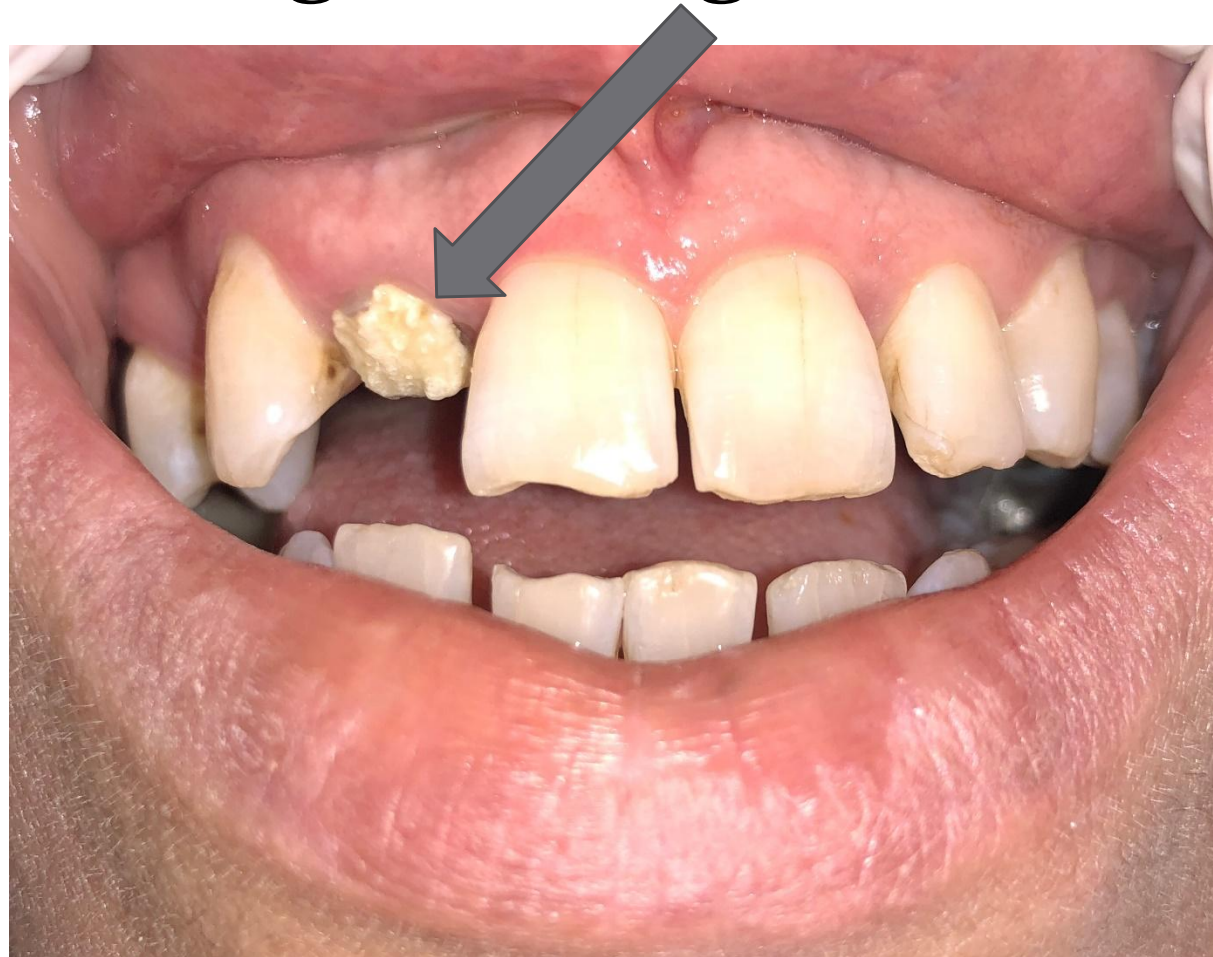# Fixed prosthodontic



PFM crown for the  $\frac{2}{|}$

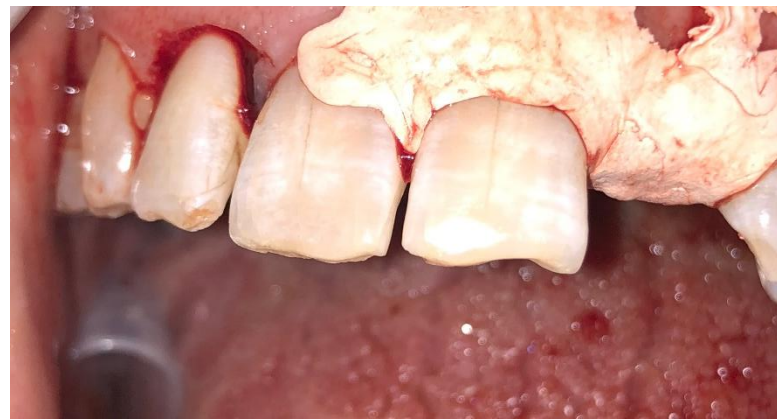
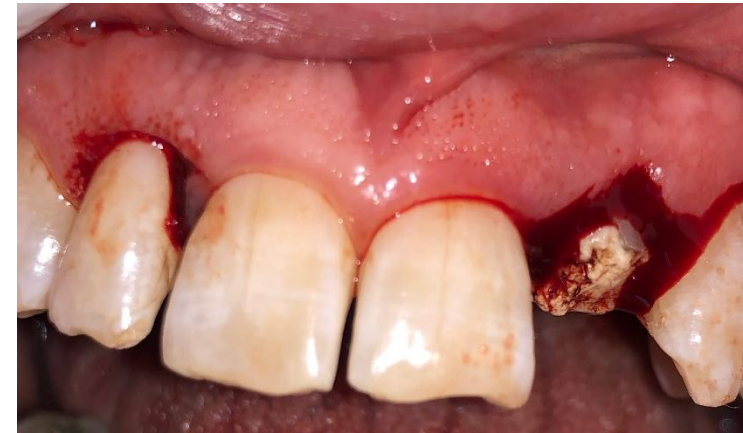
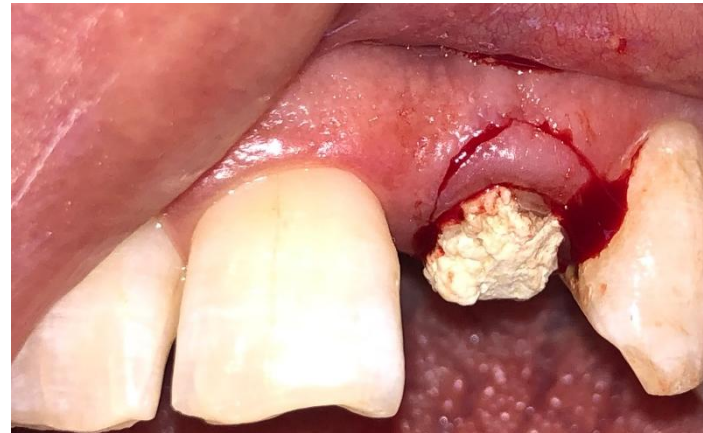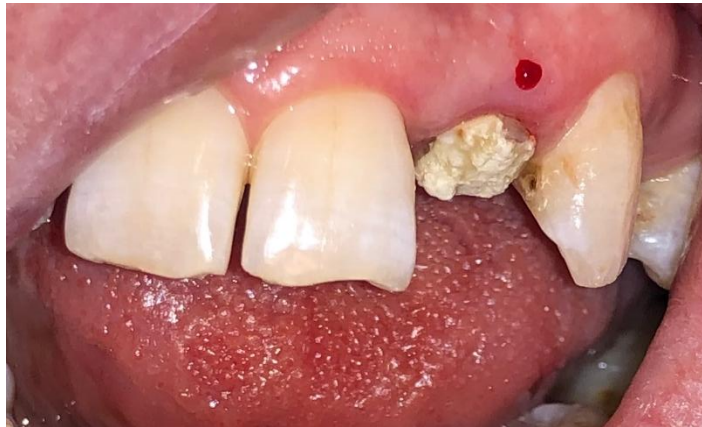# Crown lengthening

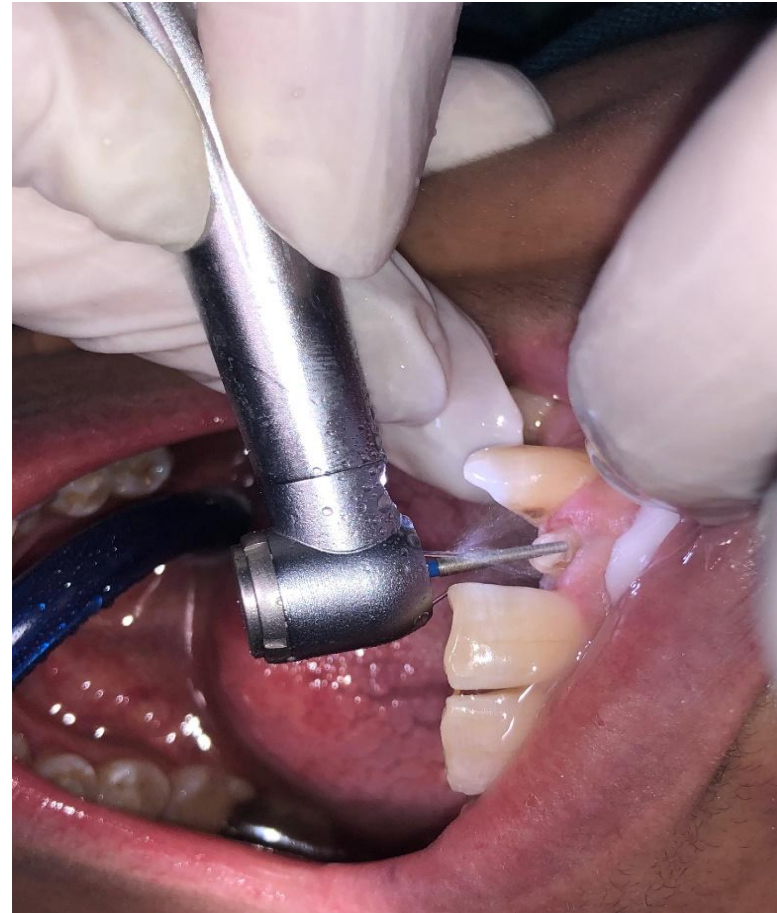



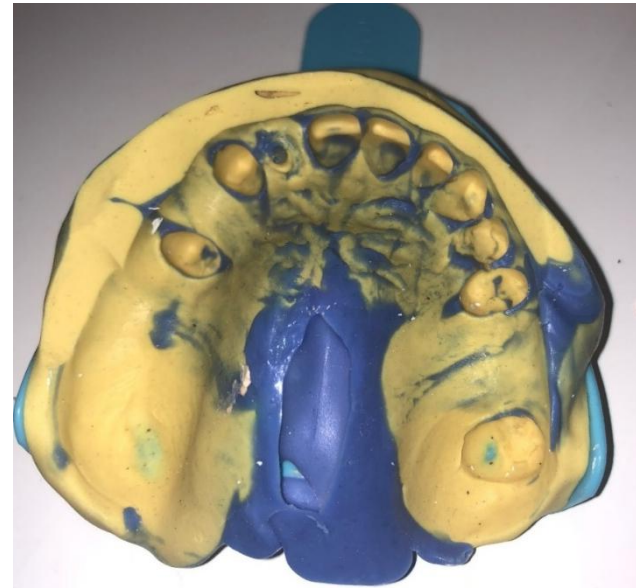
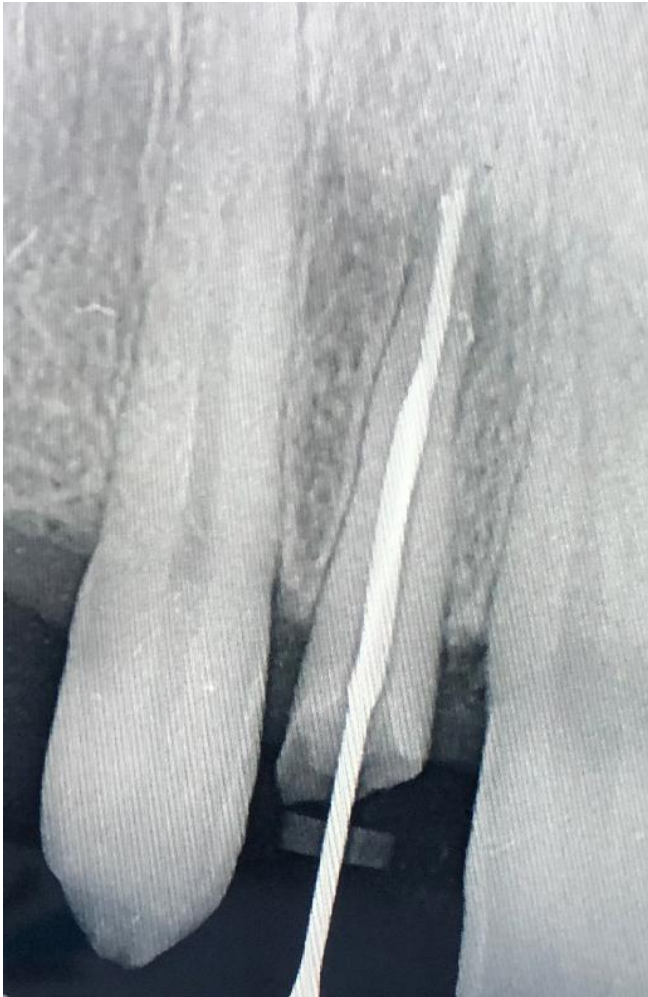# Procedure



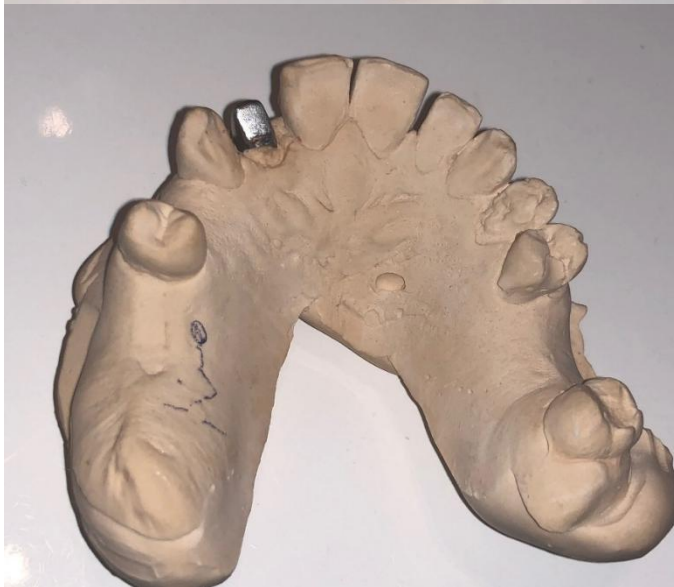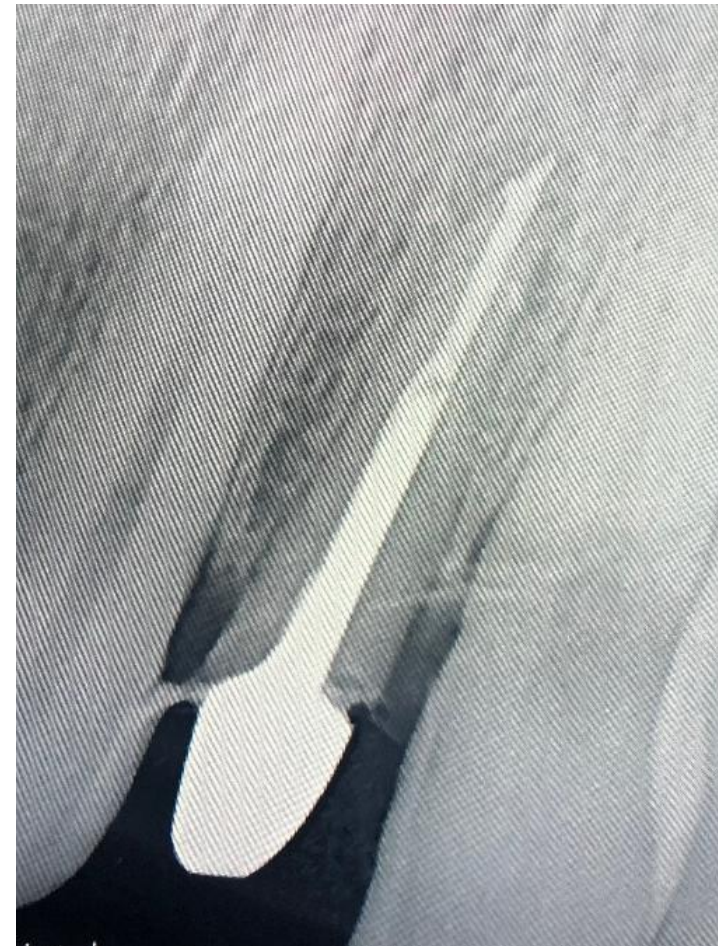
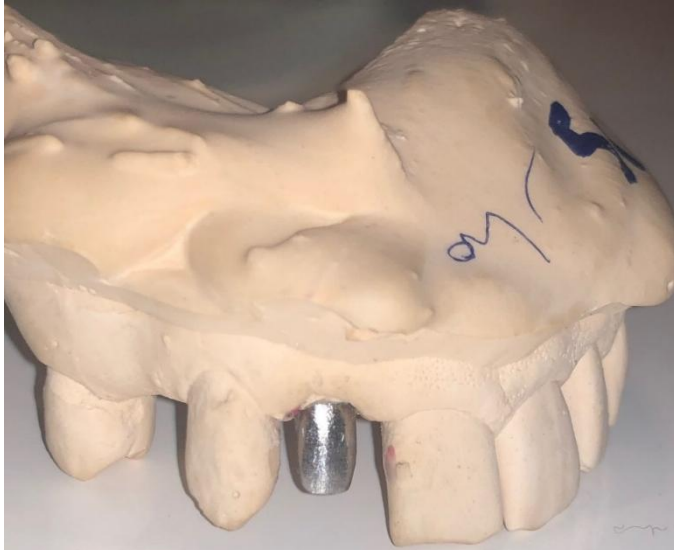
# Crown preparation



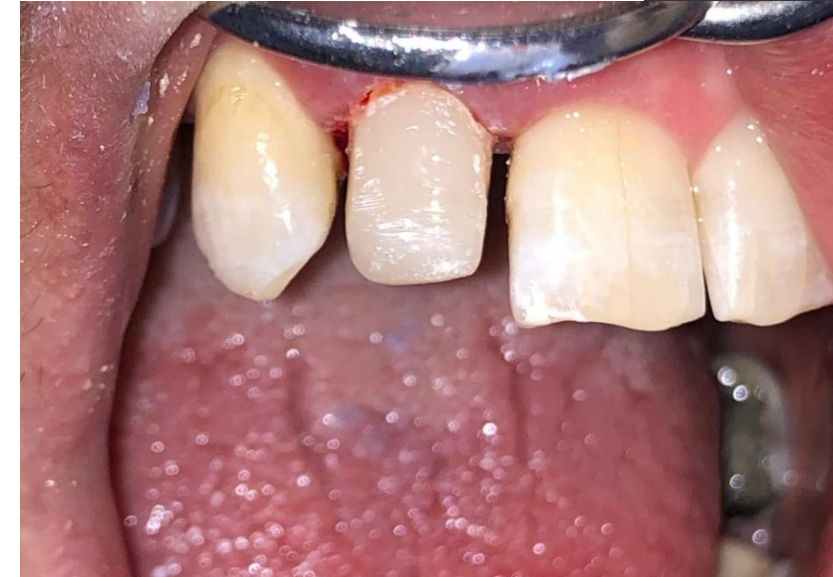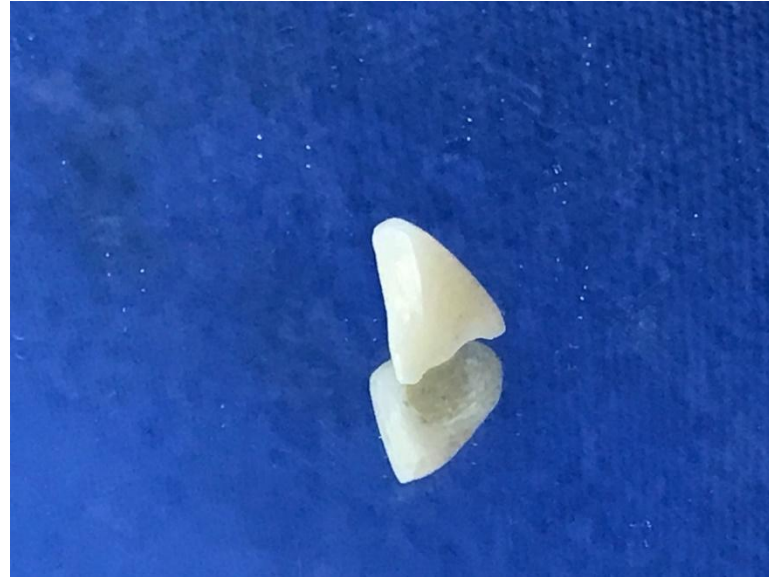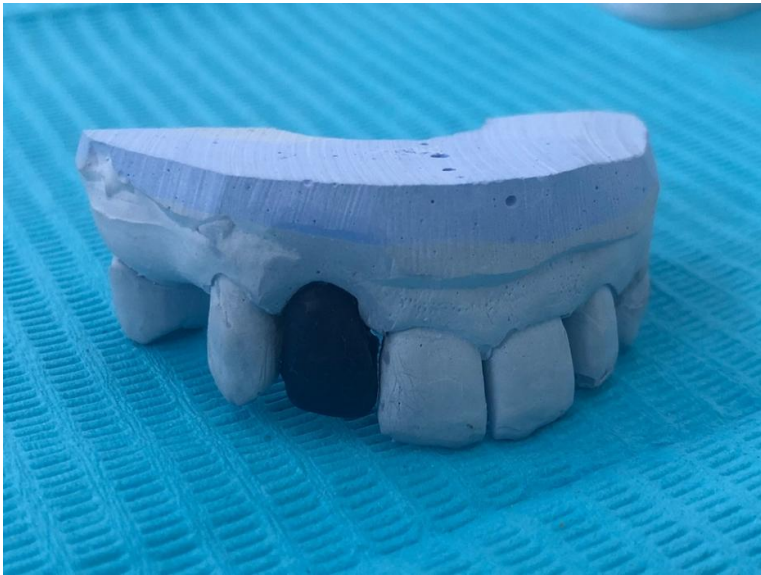# Post space preparation & impression



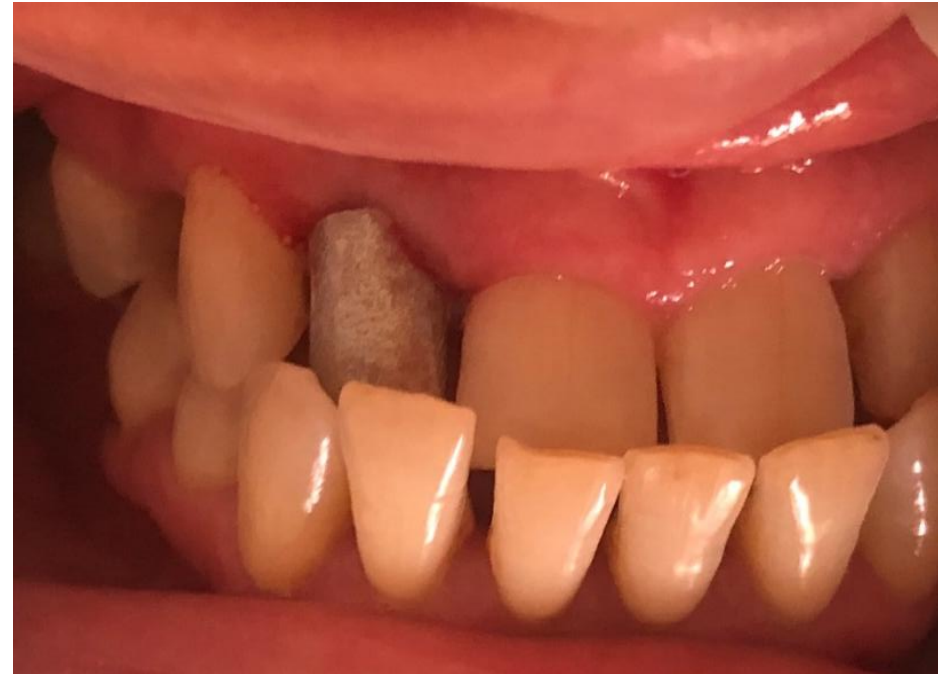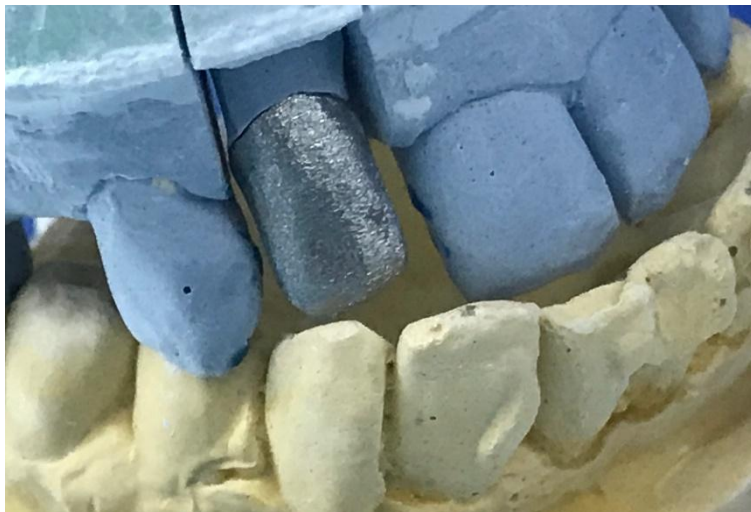# Costume made post and core



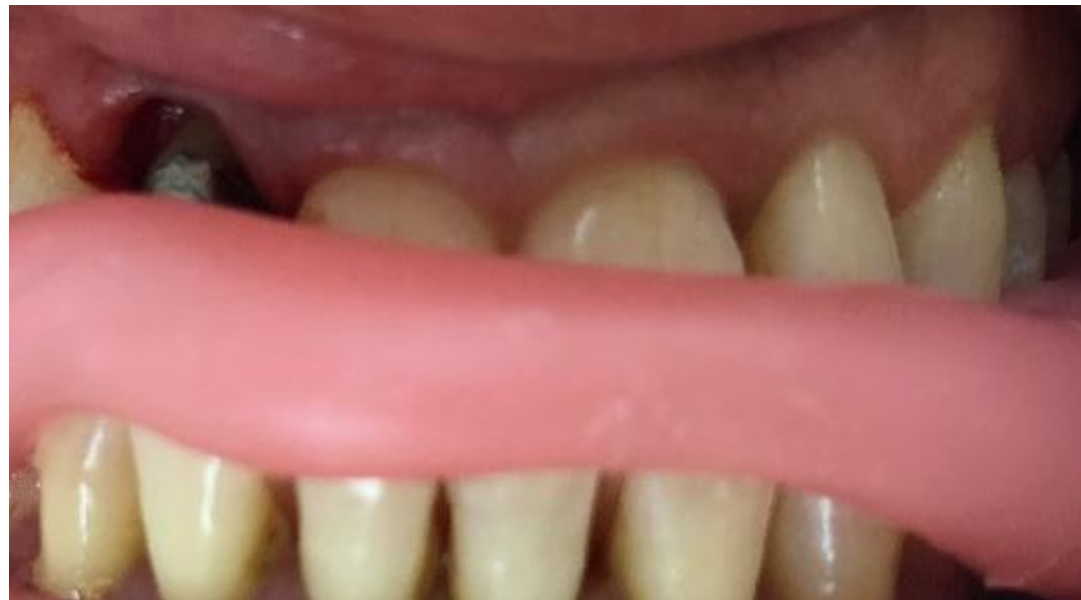# Wax up & Temporary crown



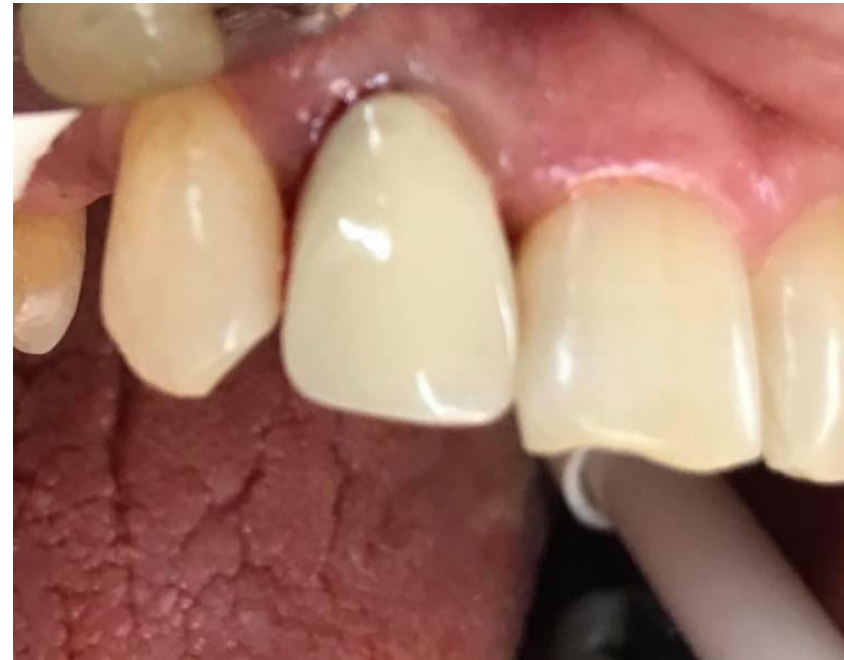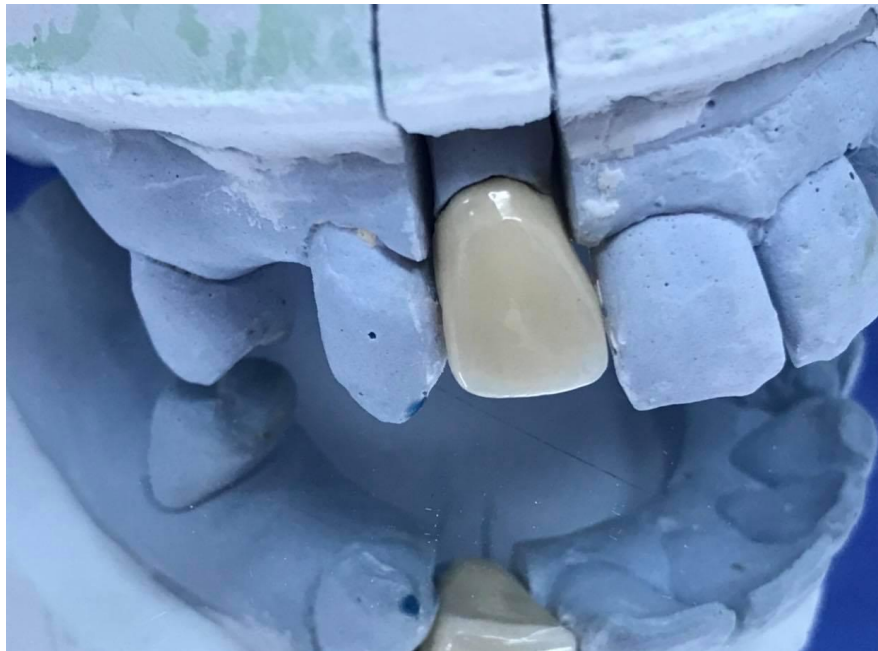# Metal try-in



# Bite registration

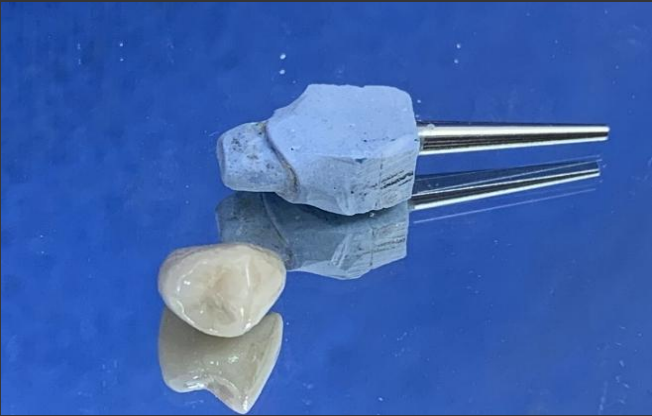


# PFM crown insertion

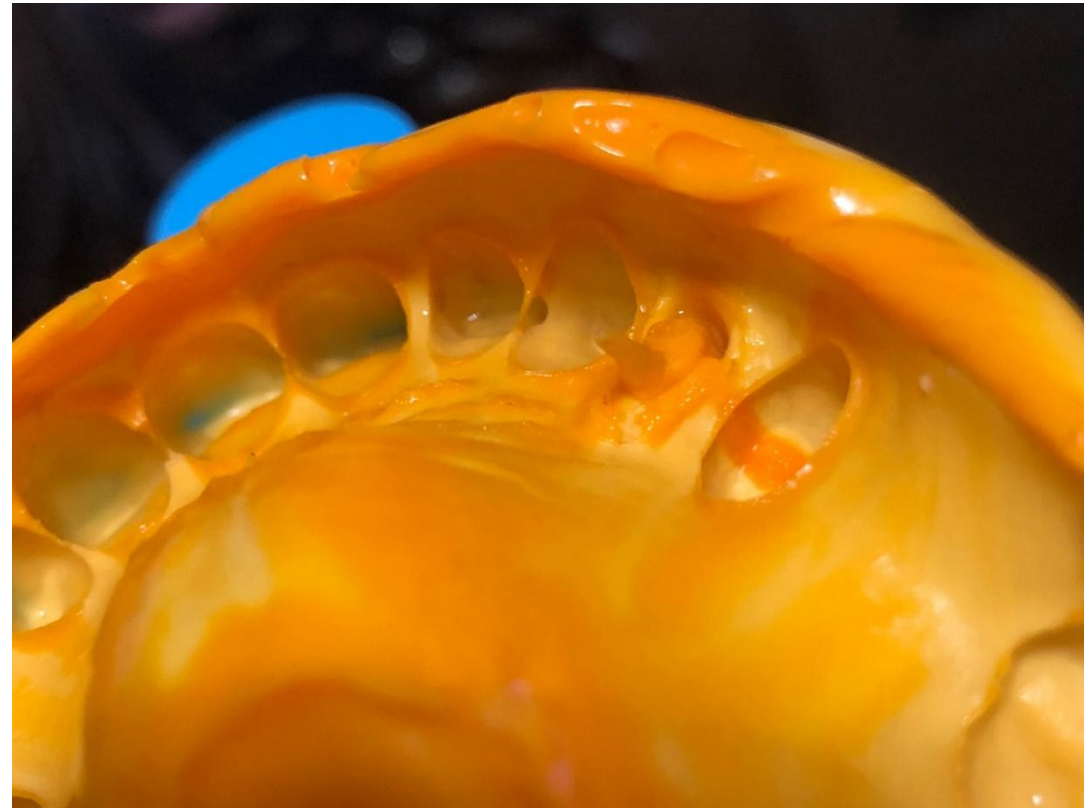
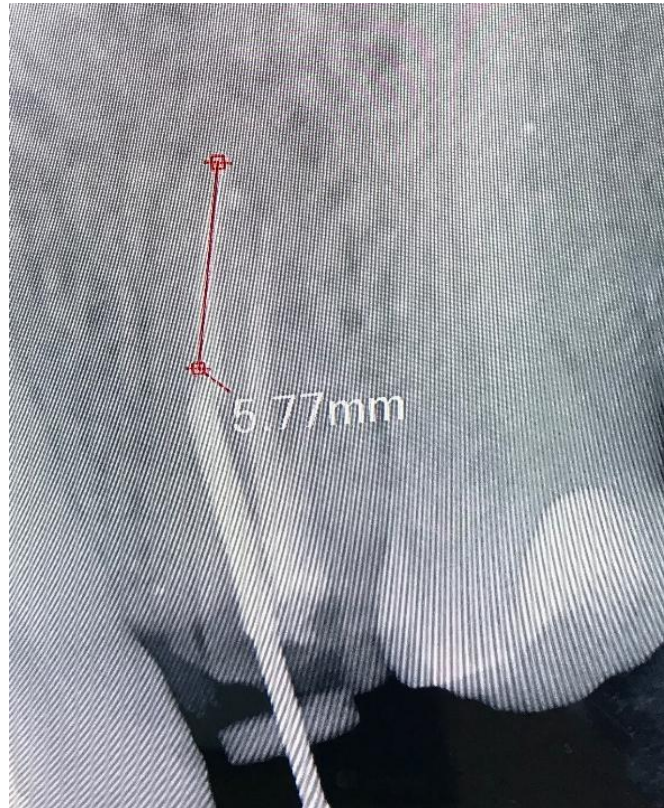




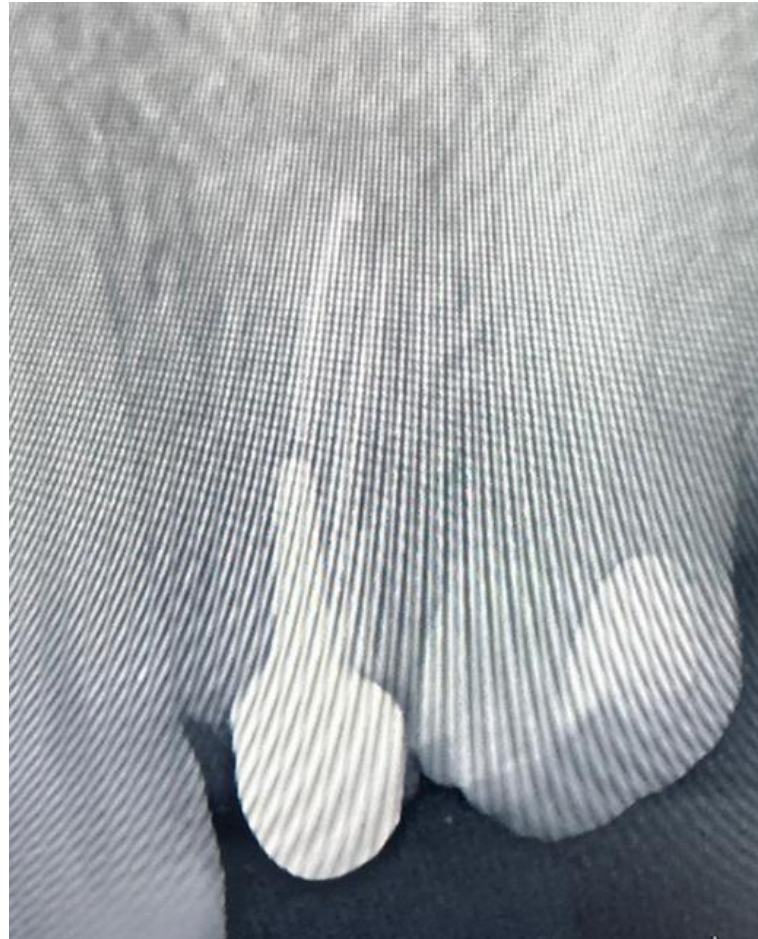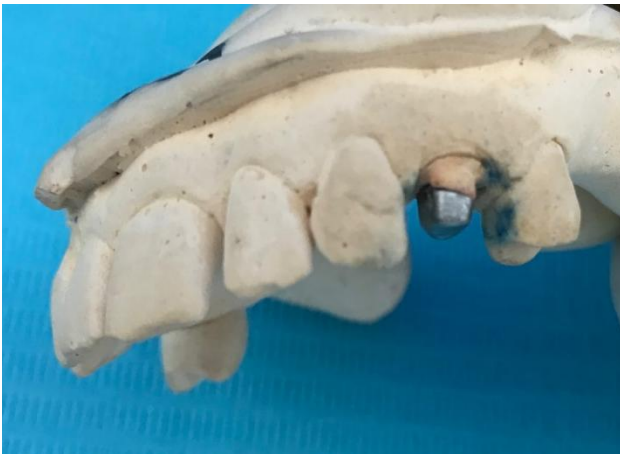PFM crown for the



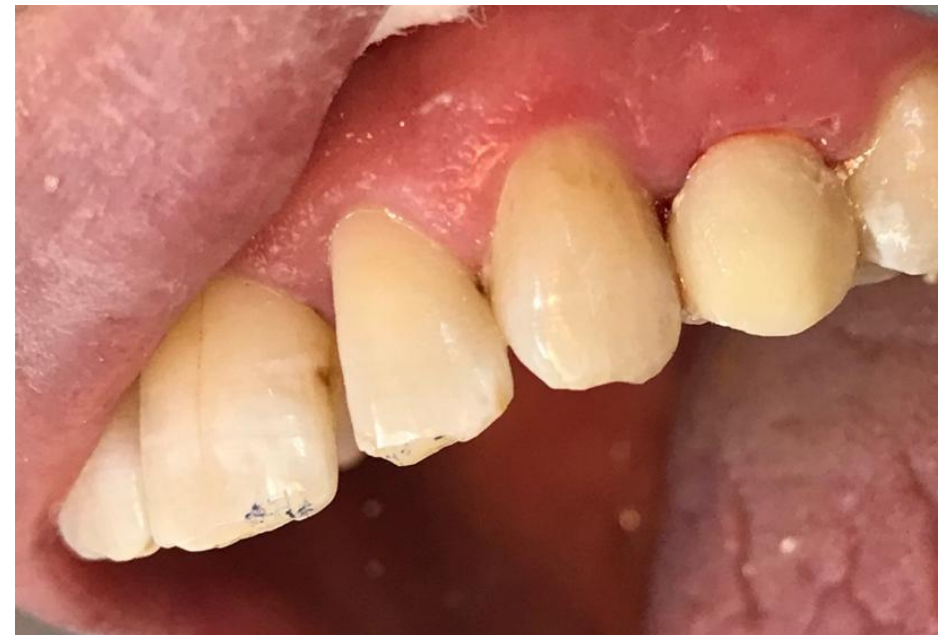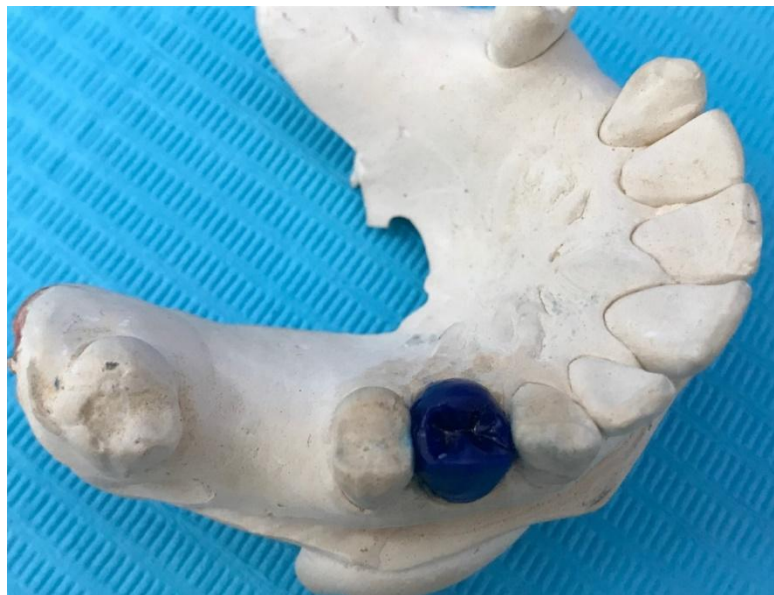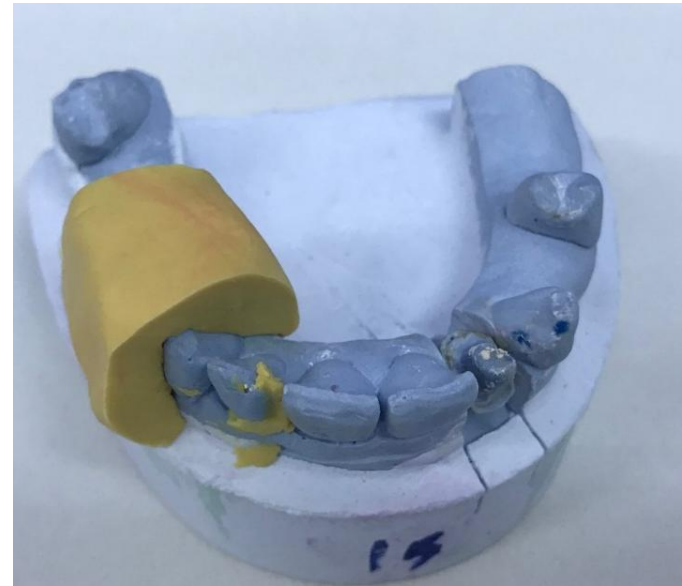
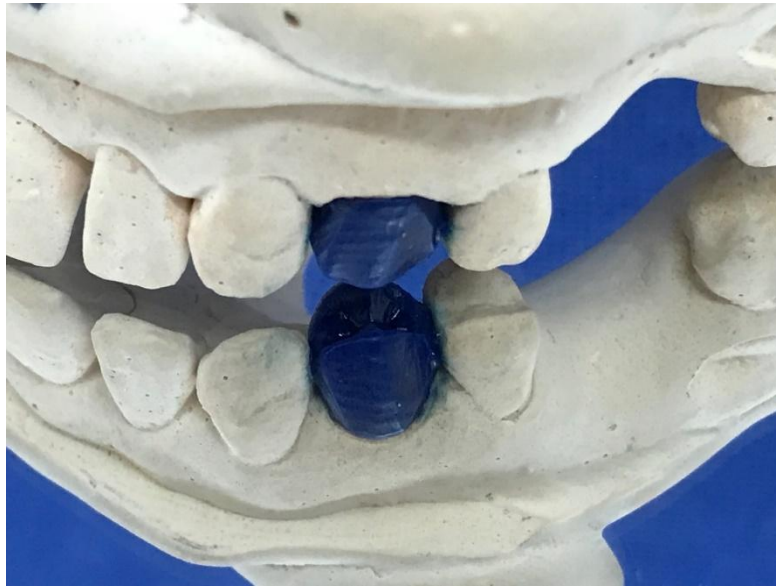# Post space preparation & impression



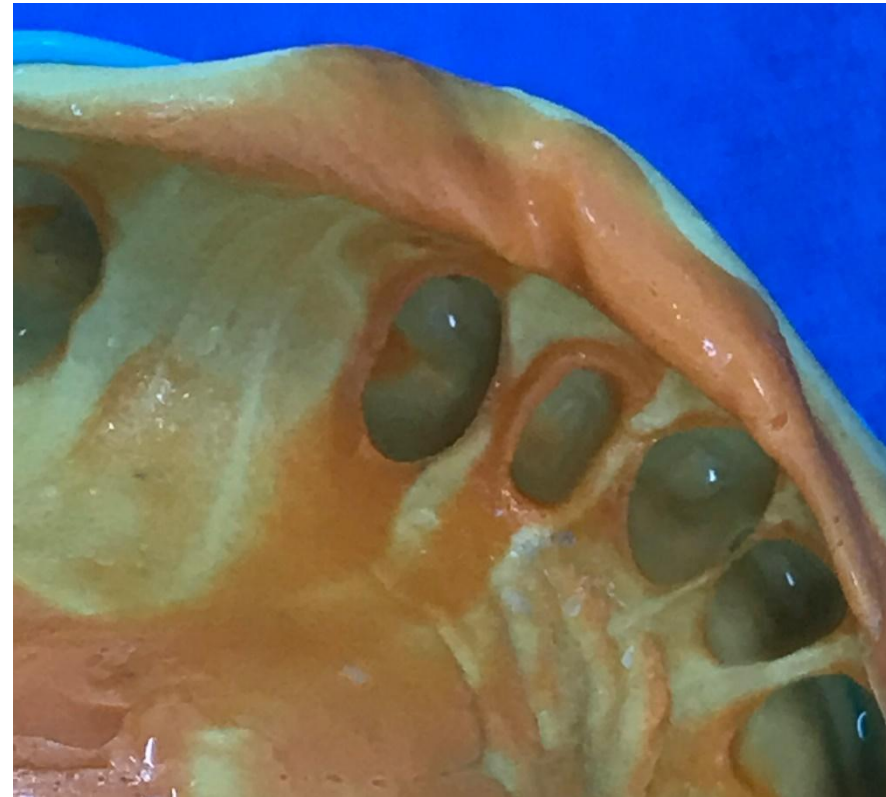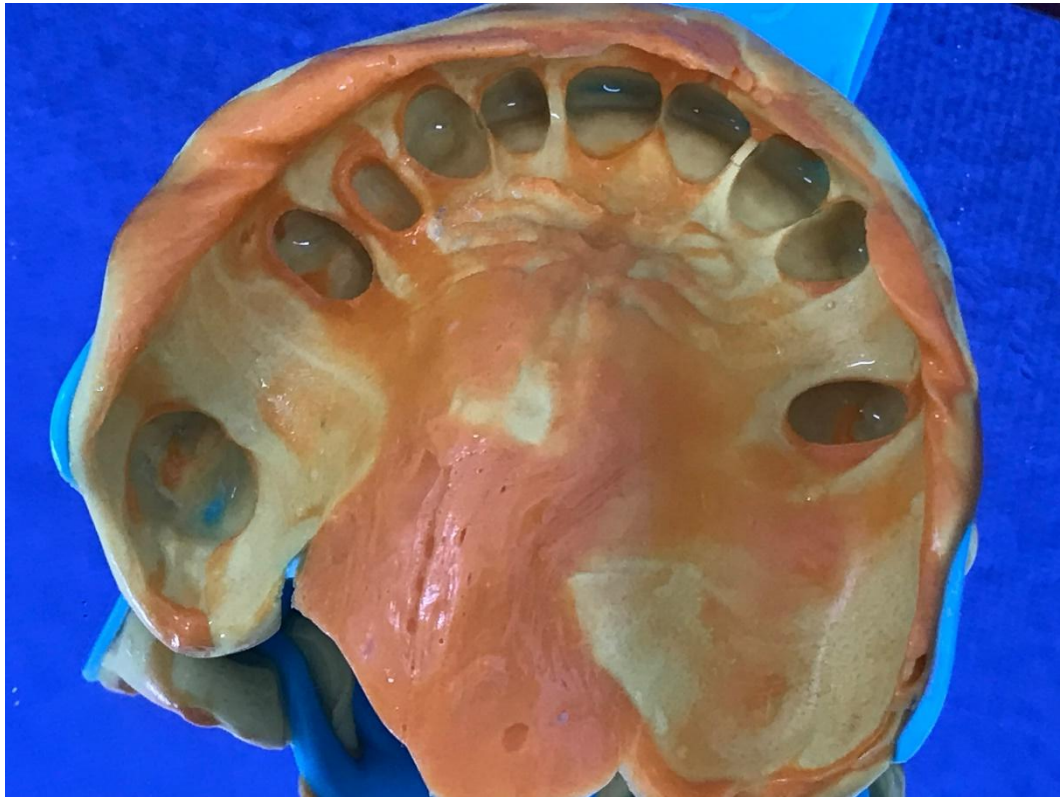# Costume made post and core



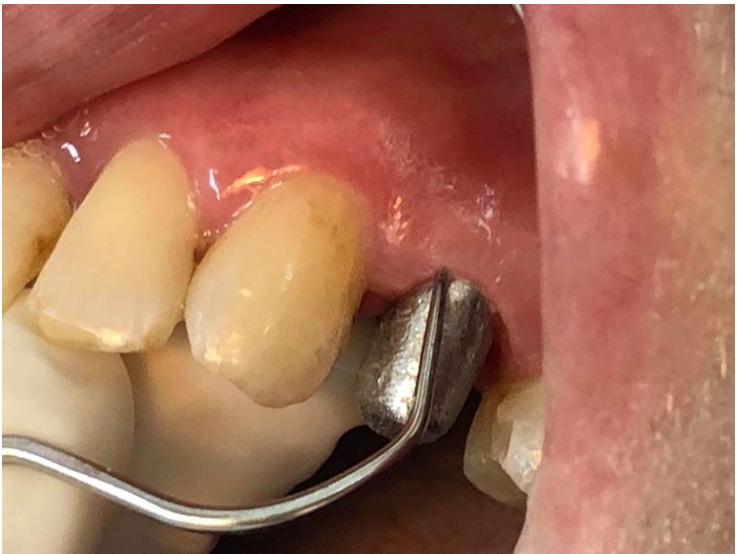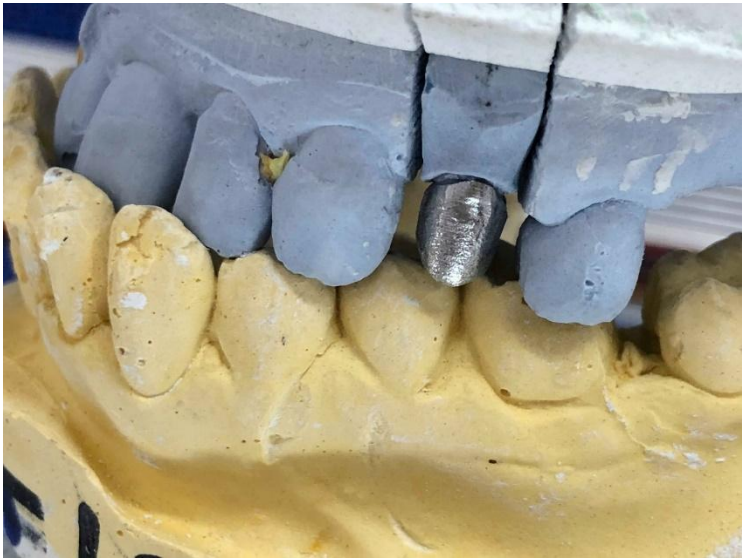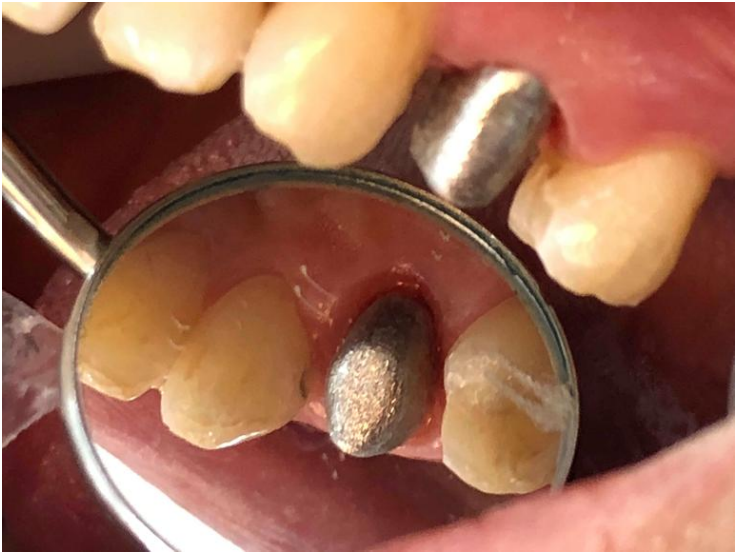# Wax up & temporary crown



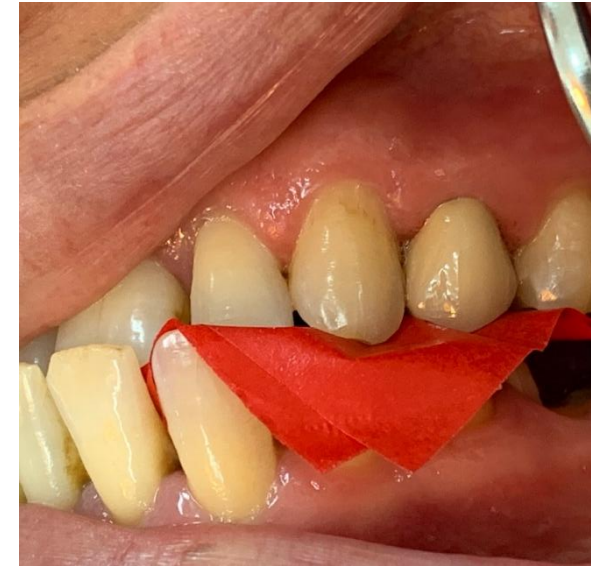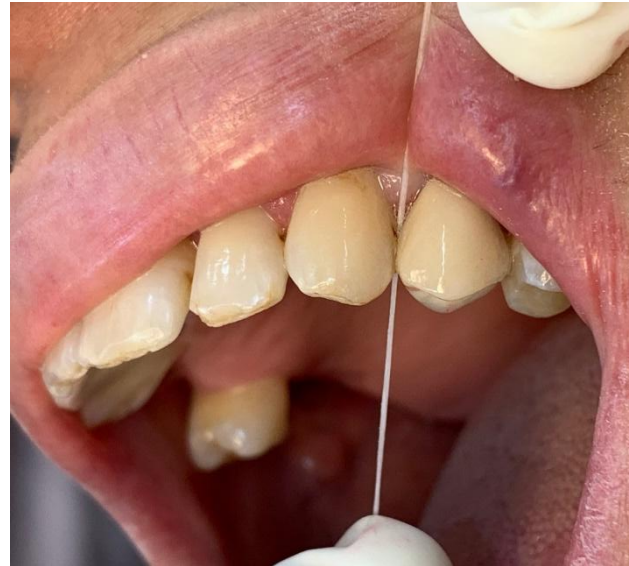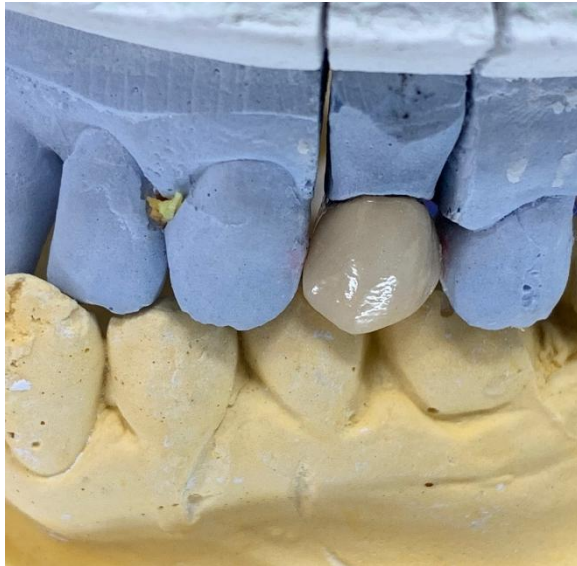# Impression of core

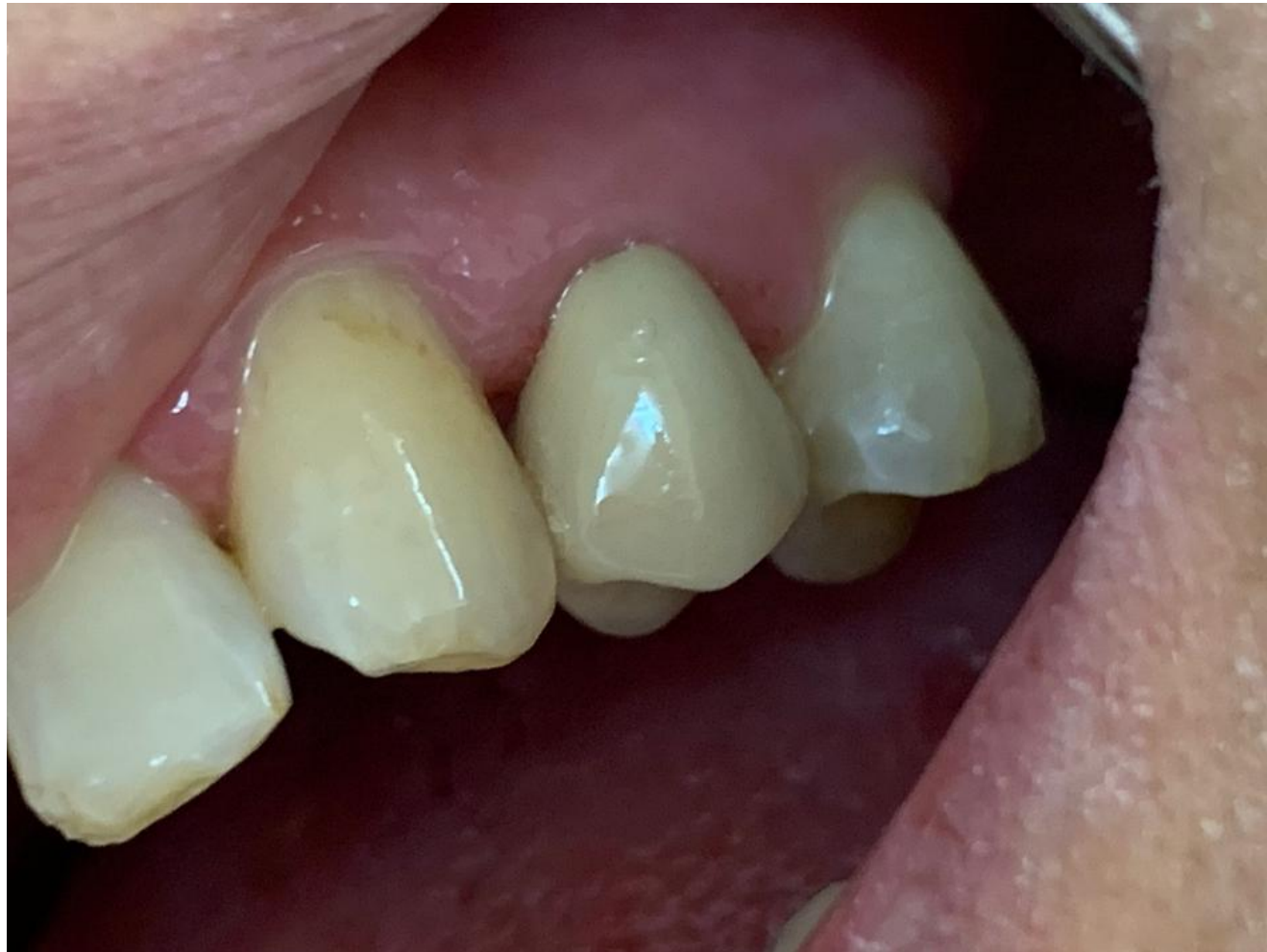

# Metal try-in



# PFM crown insertion



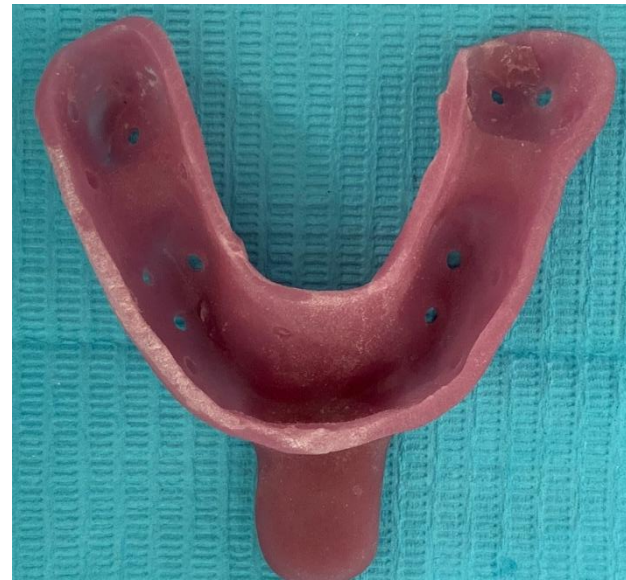
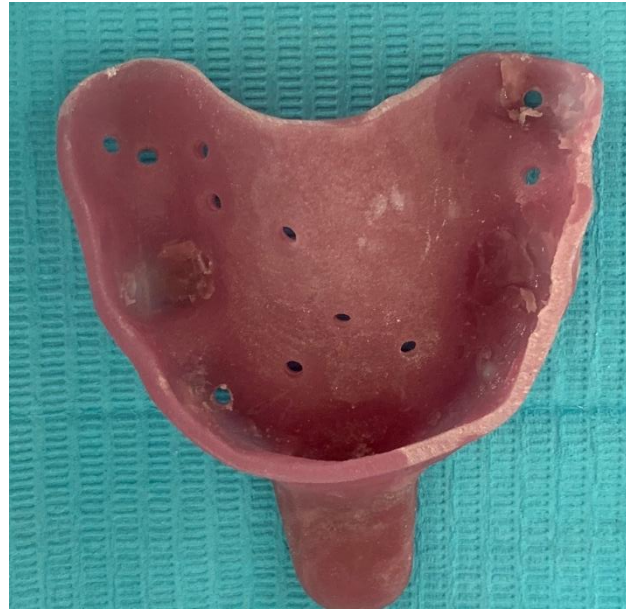


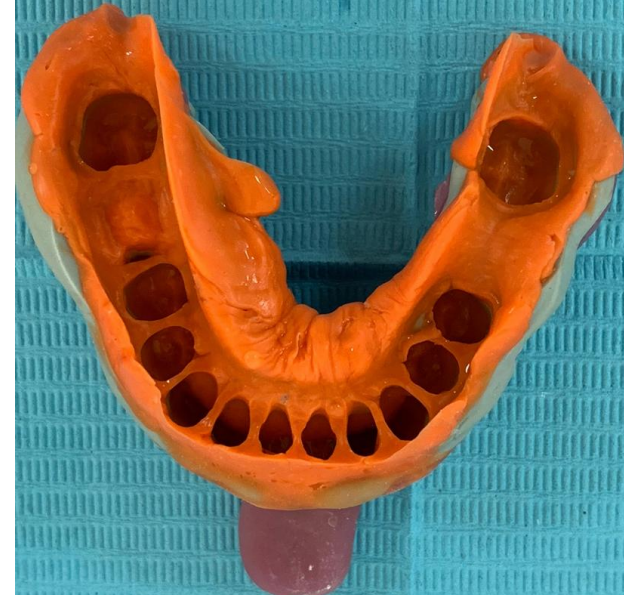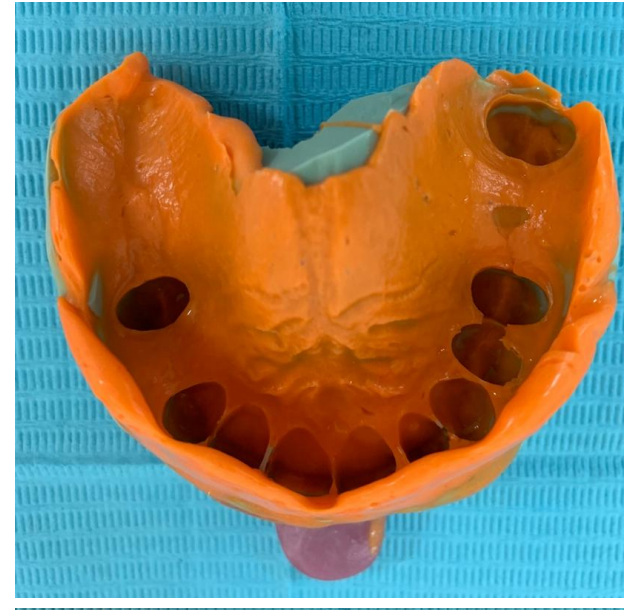
removable prosthodontics  
part:

Acrylic RPD

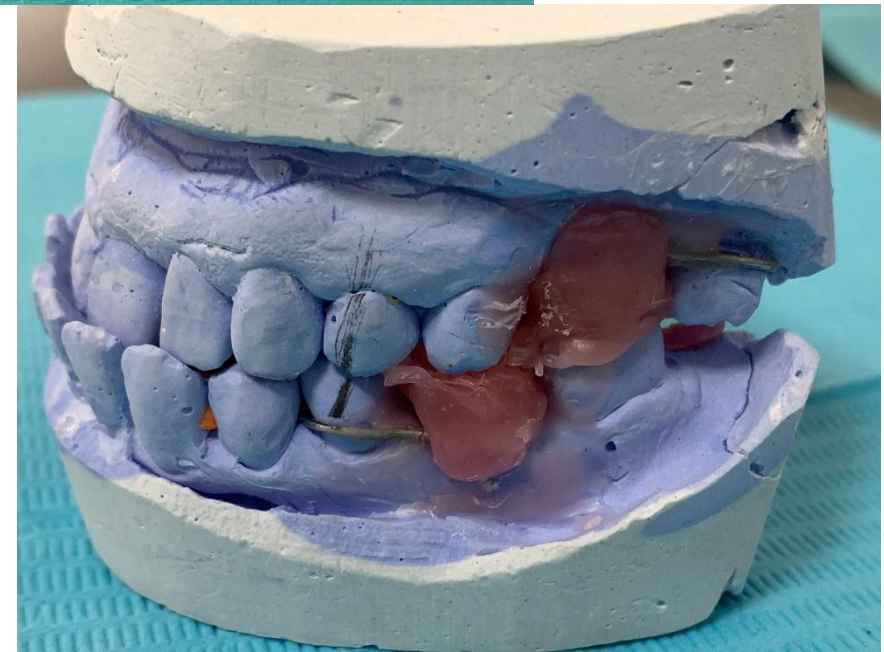
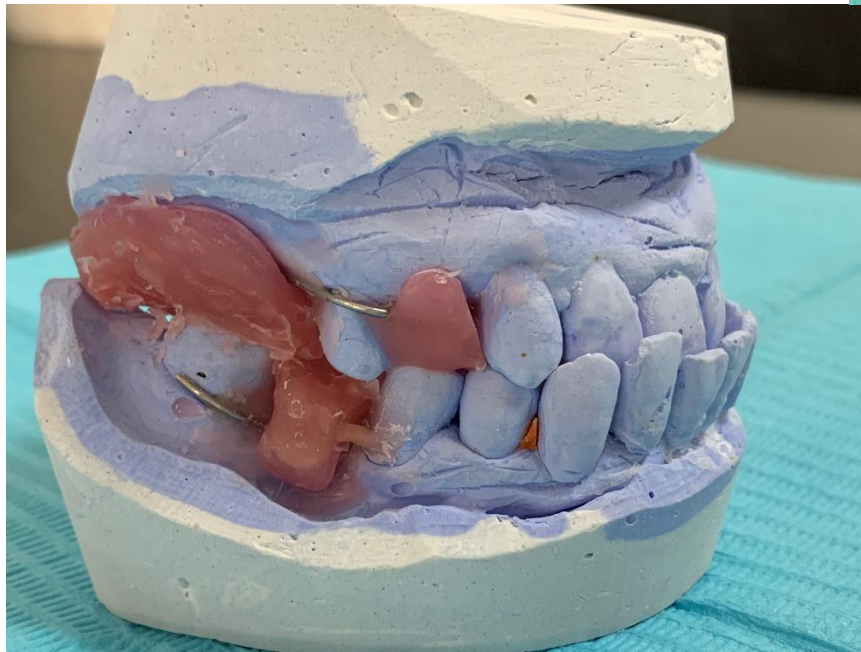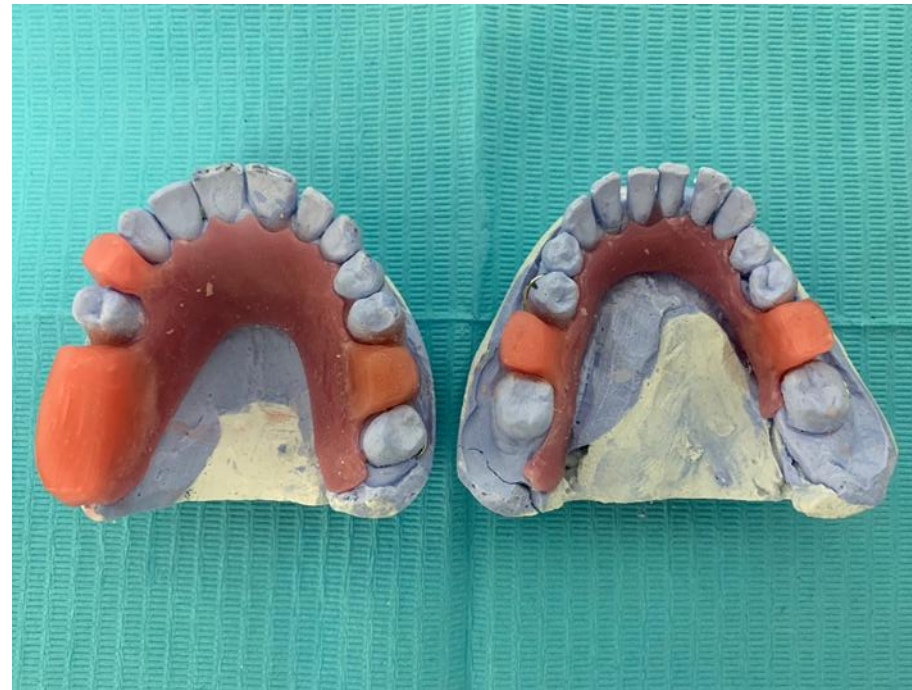# Special tray



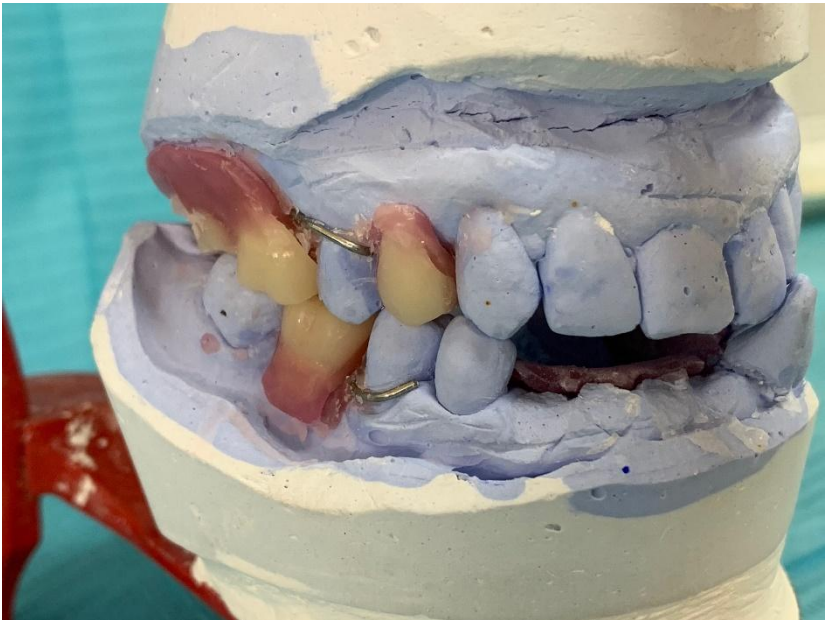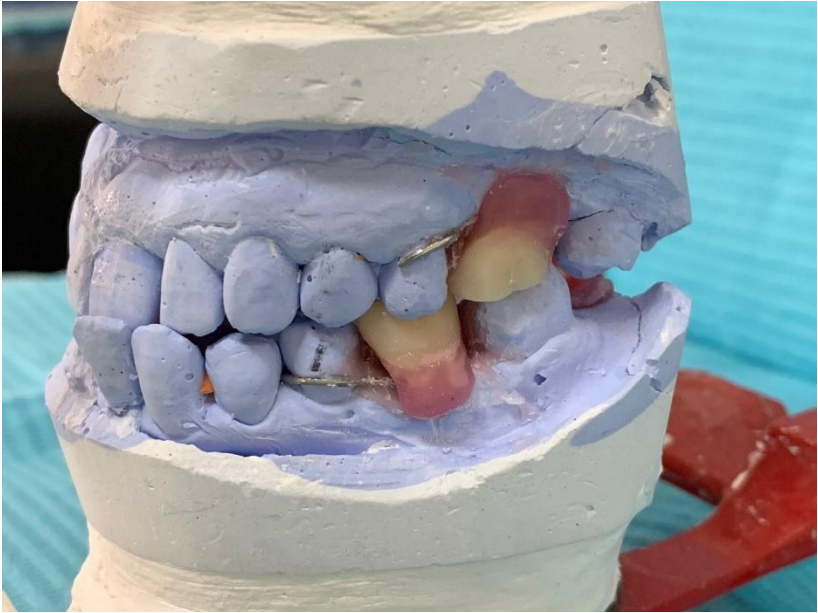
# Final impression



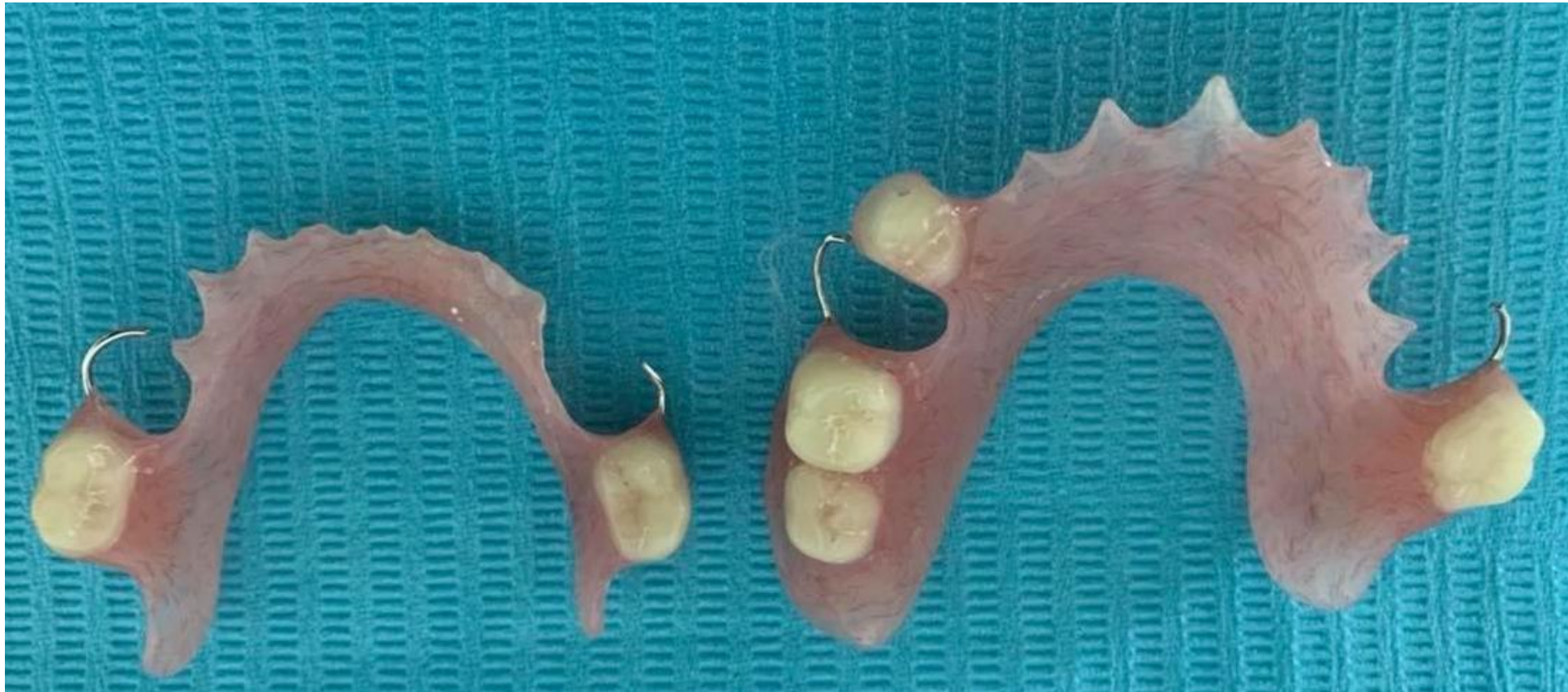# Jaw relation



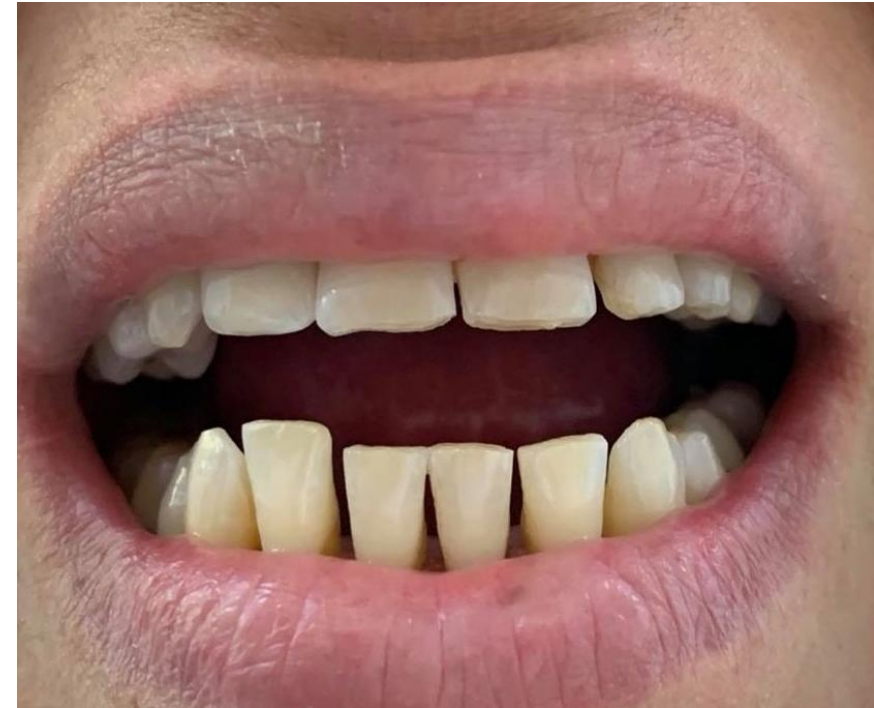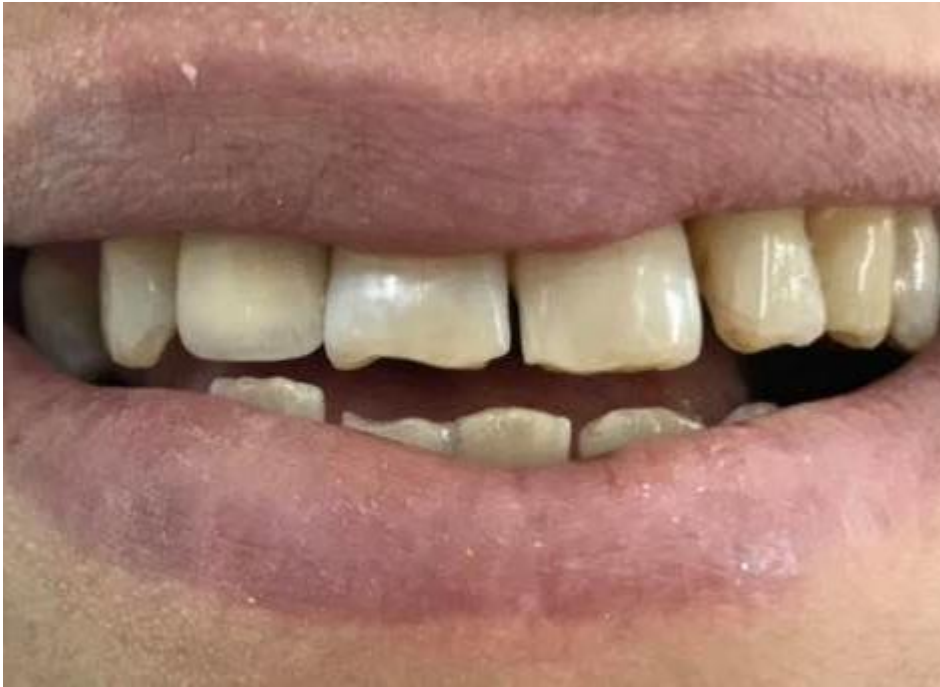# Try-in:




# Insertion

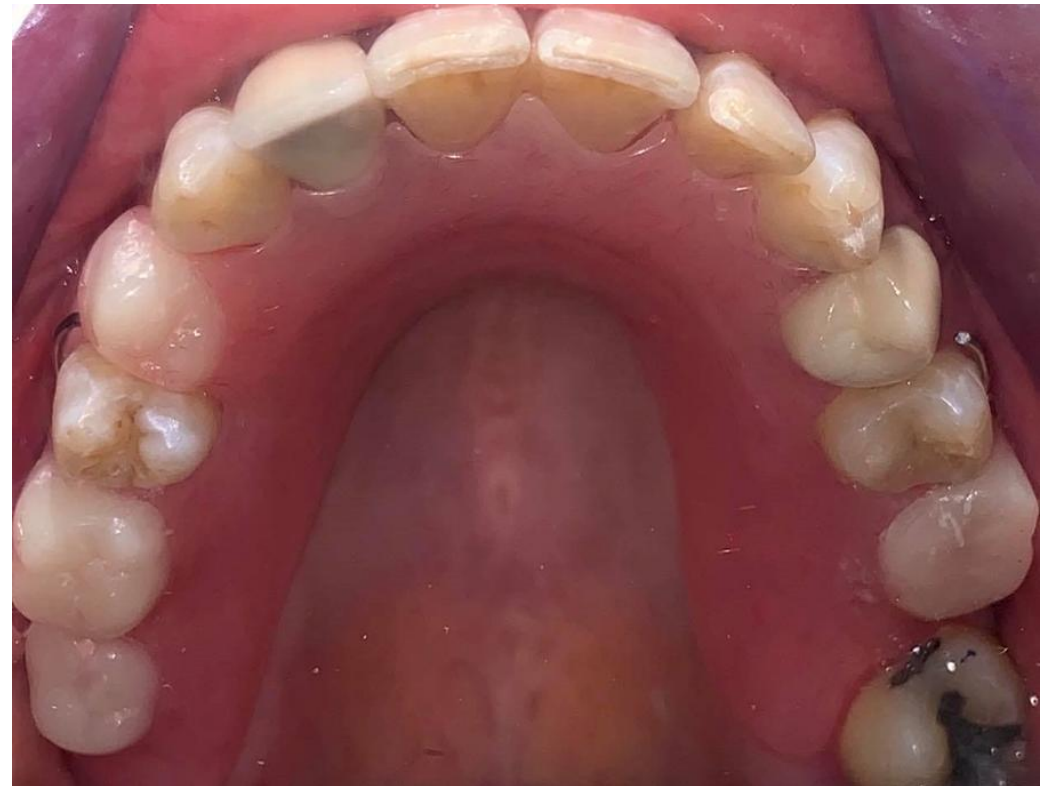
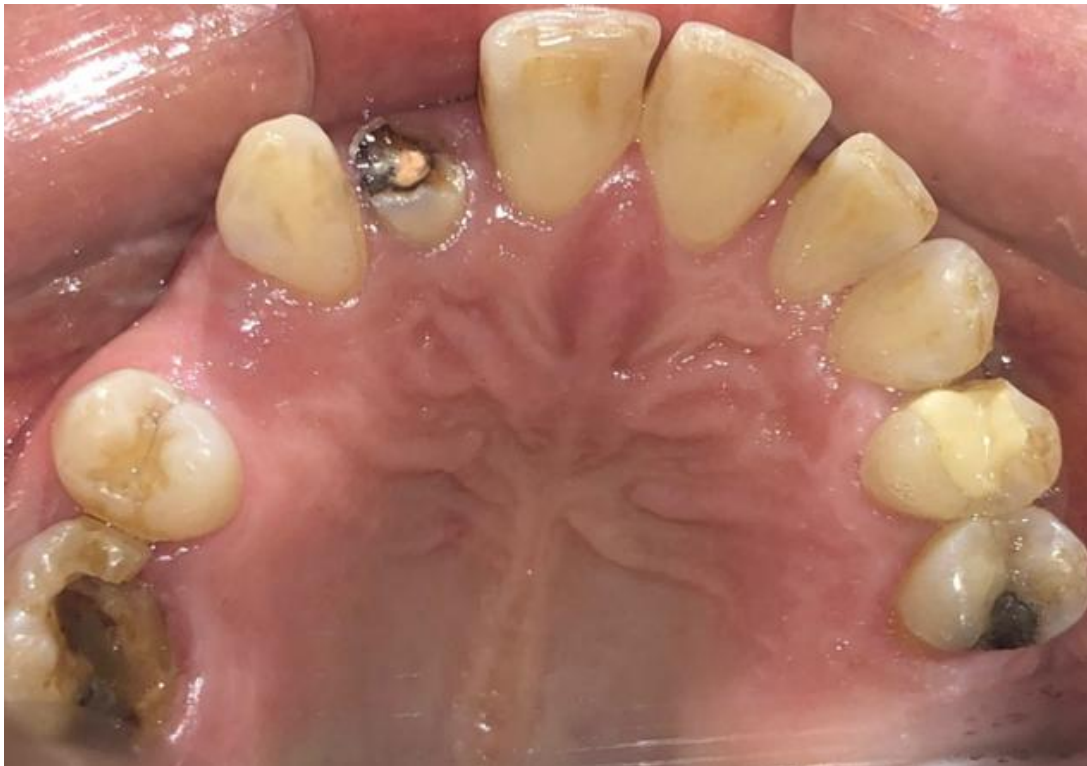
# Enameloplasia:

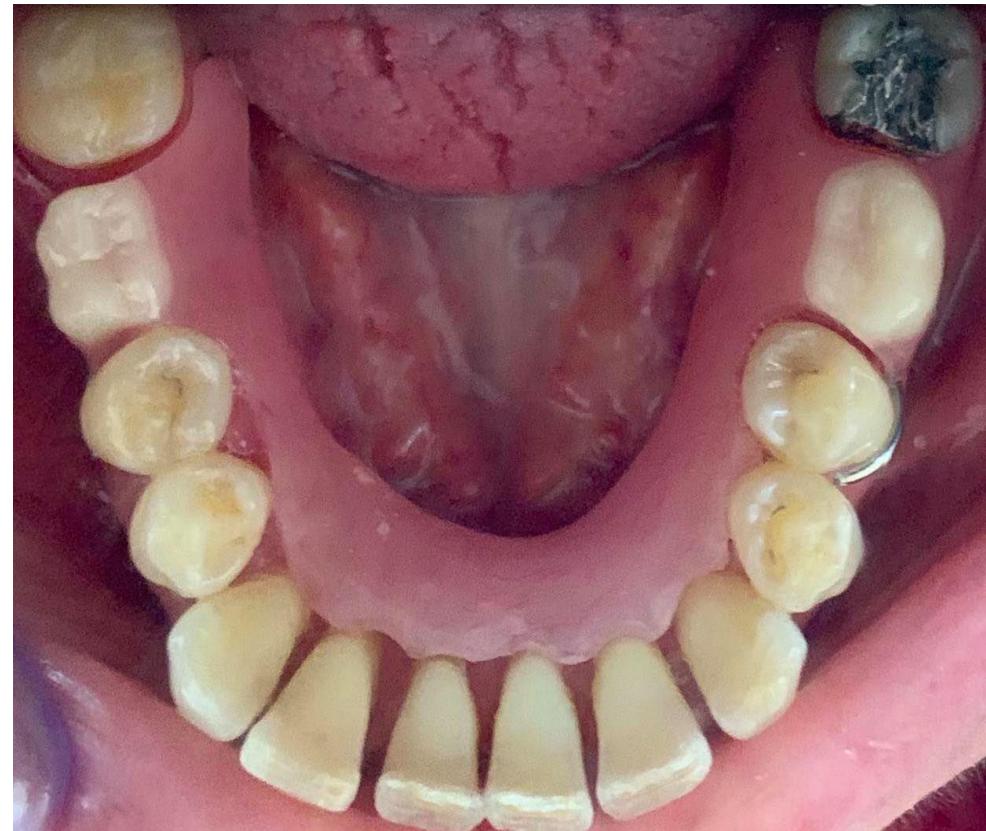
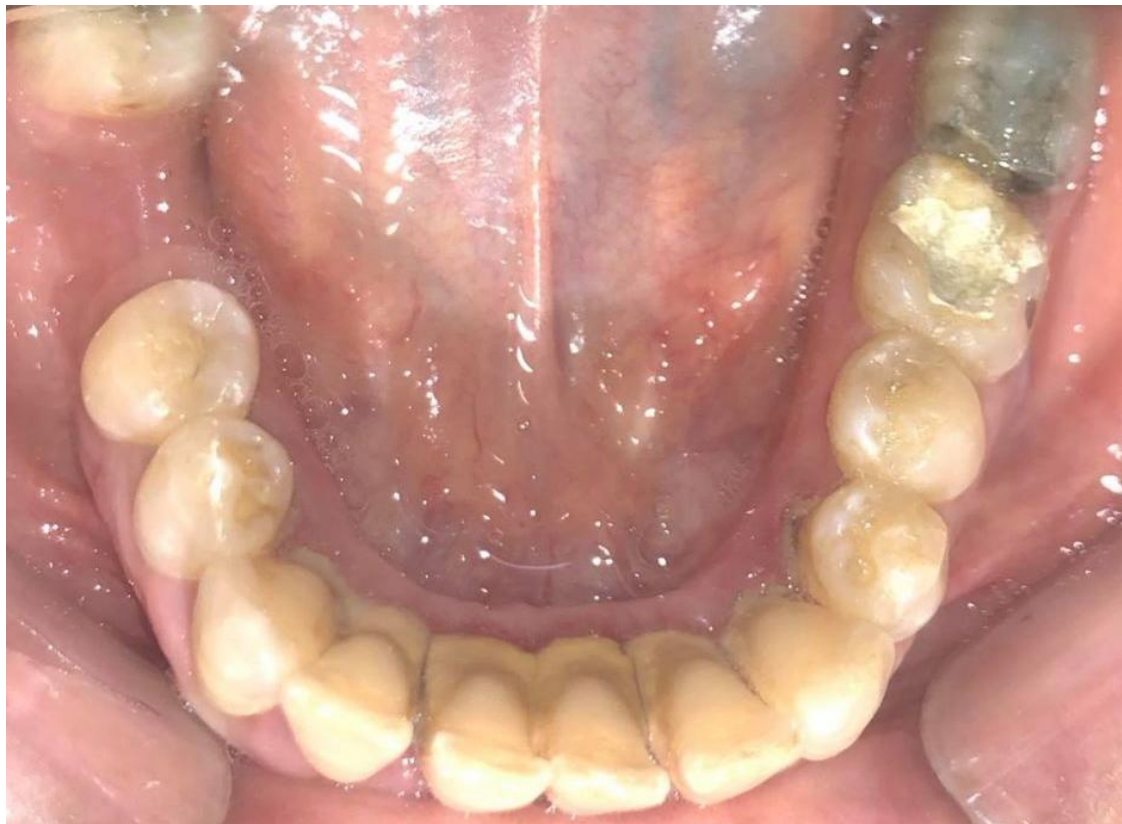
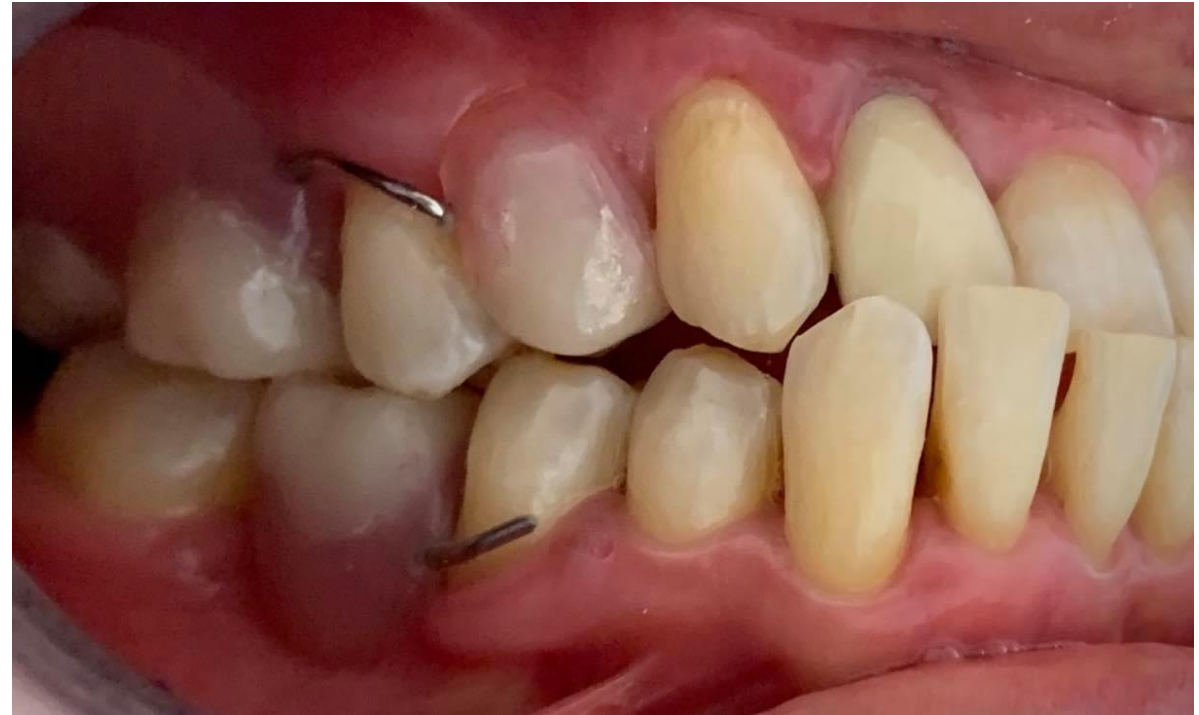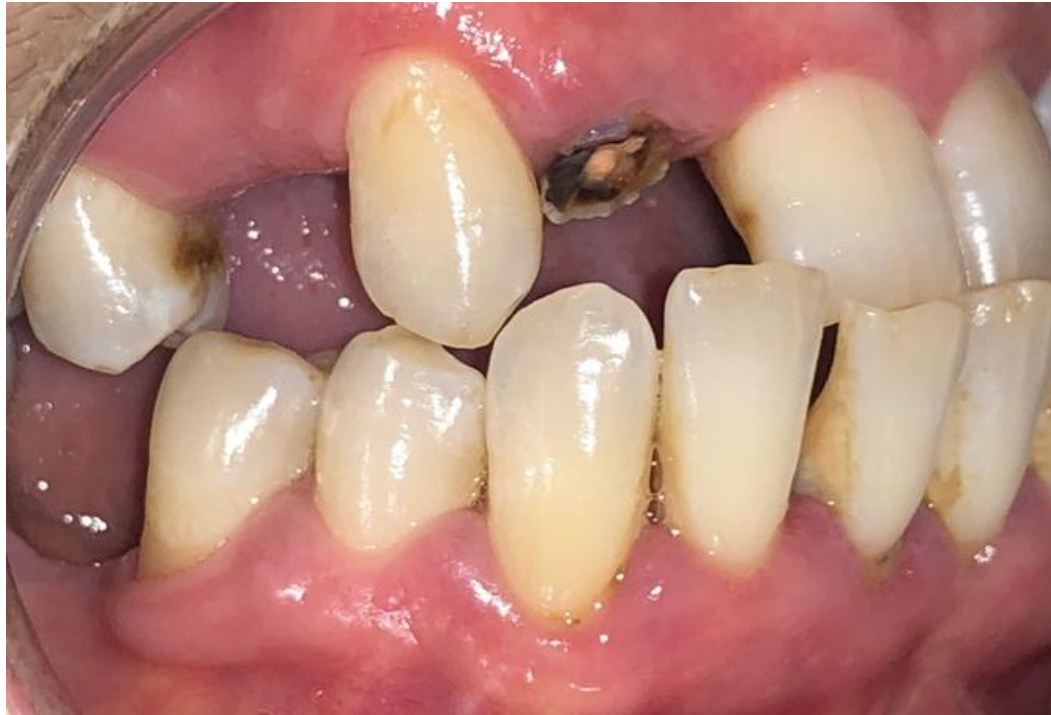RESULT

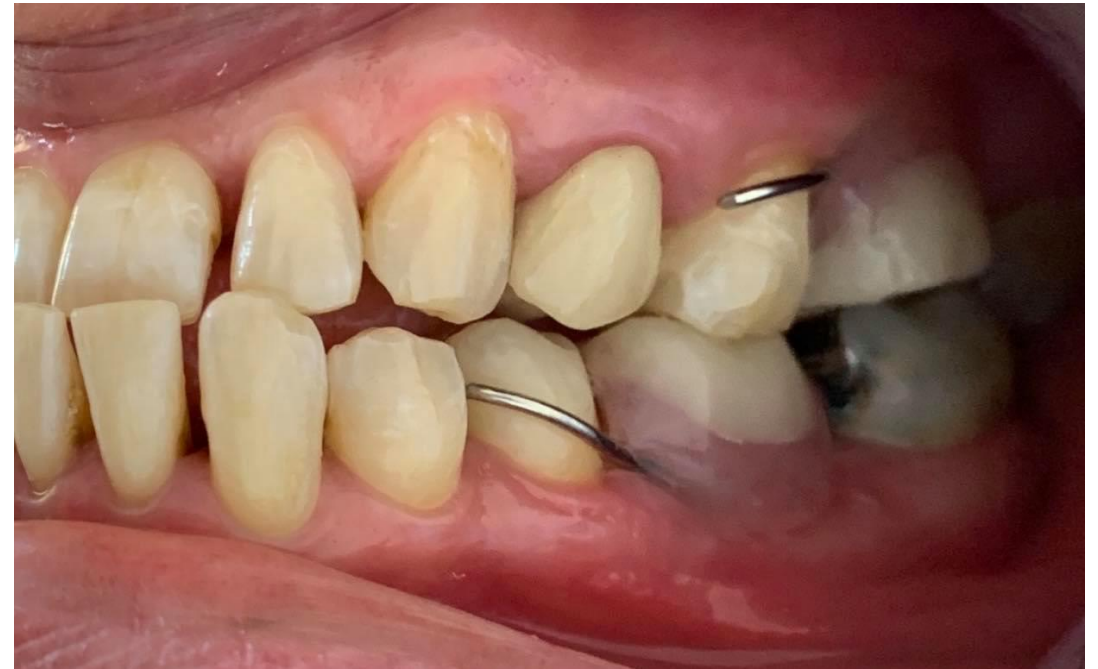
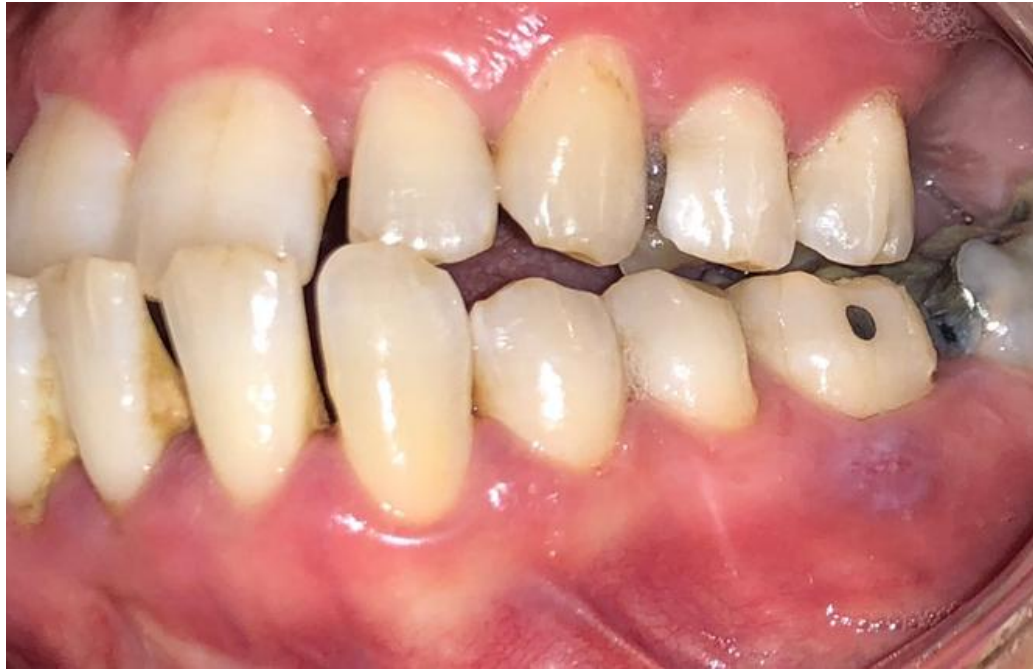


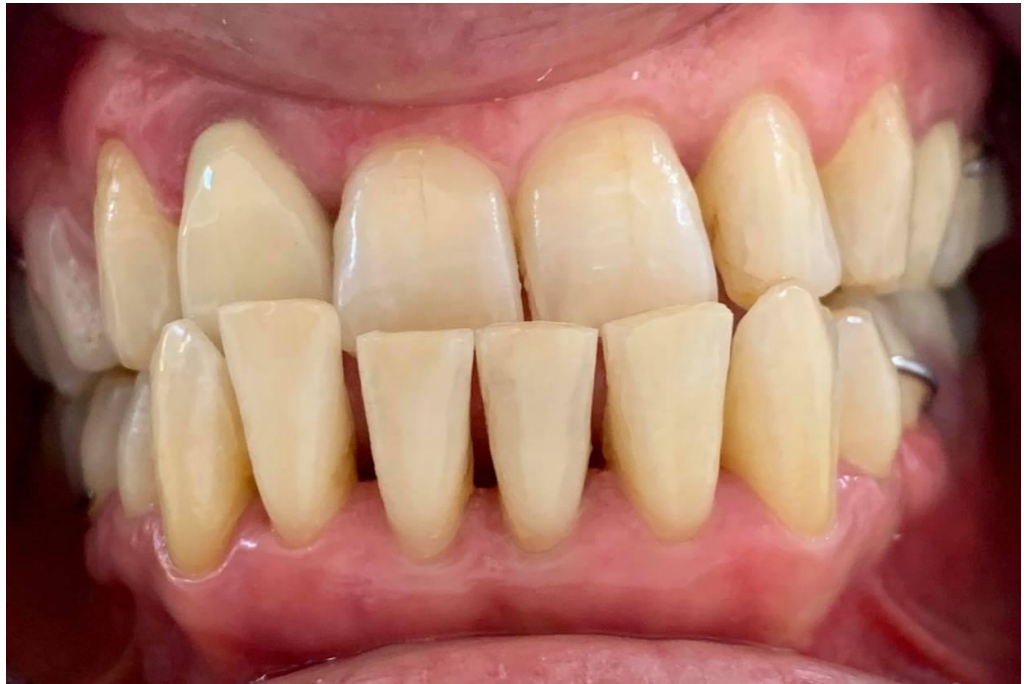
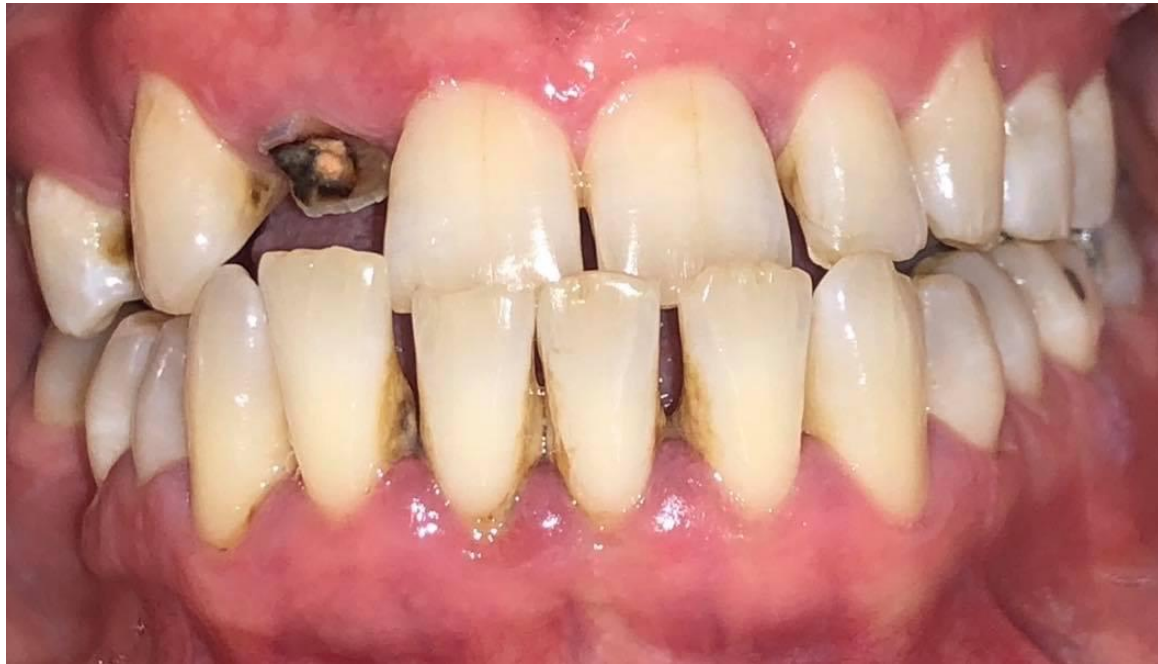








Thank you

*For your attention*

