



Libyan International Medical University
الجامعة الليبية الدولية للعلوم الطبية

Comprehansive Case

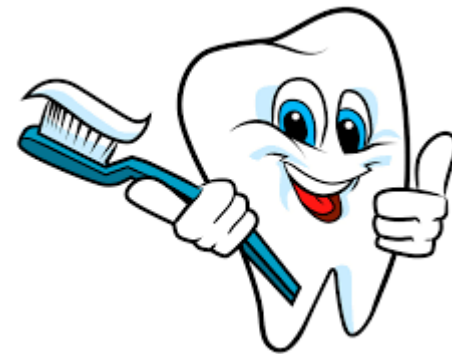BY : Mariam Abd_Alrahim Nashad
ID Number : 921



**This work done under the supervision of dental teaching staff at :
Libyan International Medical University**

- Sara Elkailani
- Rafik Alkowafi
- Omer Huni
- Abdelmonem Abdelnabi
- Masoud Dayhome
- Aml Elawami
- Marwa Elsharkasi
- Nada Kashbor
- Khadiga Elfallah
- Ali Busnania
- Nuha Elkadik
- Abdelsalam Elhddad
- Rabea Alhun

- Patient name: H.M. A. A**
- Date of birth : 3\6\1972**
- Gender: Female**
- Nationality : Libyan**
- Occupation : Housewife**
- Date : 2019\3\13**



Chief complain :

Patient coming to dental clinic for restore badly decay multiple teeth for long time nearly 3 years ago

History of chief complain :

Patient give history of multiple decay teeth that get continued and got fracture with no history of pain swelling or any other associated symptoms

No history of teeth decay of since childhood

And she is discomfort from his teeth and need to restoration for esthetic and function to preserve his teeth

Medical history :

**Hypertensive from 1.5 year last reading from 3 months)
(160\80mmHg)**

drug history:

Atacand plus 16\12.5 mg tab

Allergic history Non

Dental history

Last visit from 10 months ago for extraction without any complication

Family history ; hypertension and heart disease from mother

Social history :Widow with 5 children NOT smoker or drinking

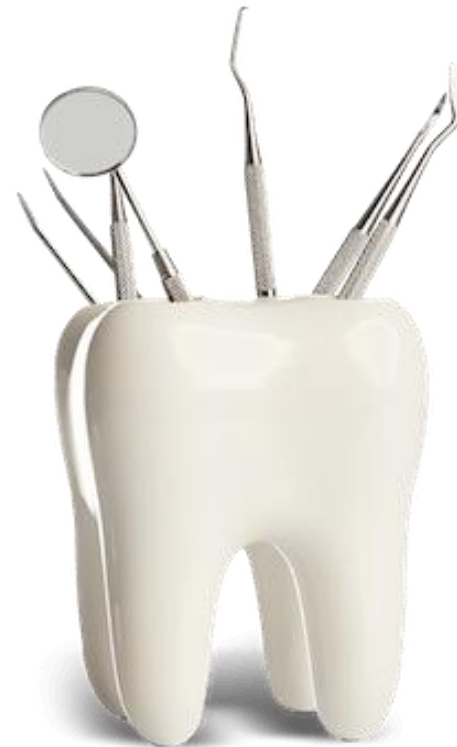EXTRA ORAL EXAMINATION

- ✓ **Face symmetry No scaring**
- ✓ **Skin : color normal**
- ✓ **No lesion**
- ✓ **TMJ normal**
- ✓ **Lymph node not palpable**

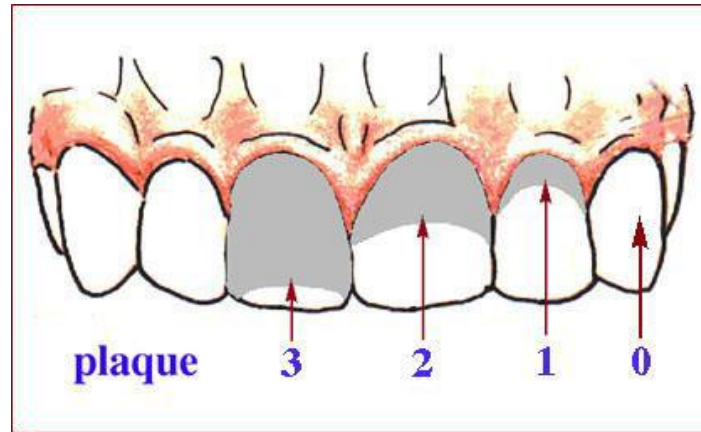
INTER ORAL EXAMINATION

- Oral mucosa : normal
- No discolouration
- No swelling
- No ulcer

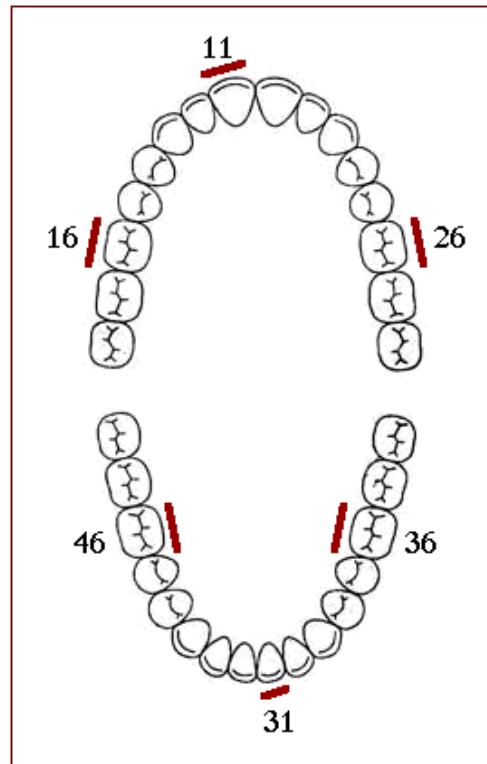
- Fair oral hygiene
- Inflamed Gingiva
- Fissured tongue



OHI



| | | |
|----|----|----|
| 16 | 11 | 26 |
| 3 | 3 | 3 |
| 3 | 2 | 2 |
| 46 | 31 | 36 |

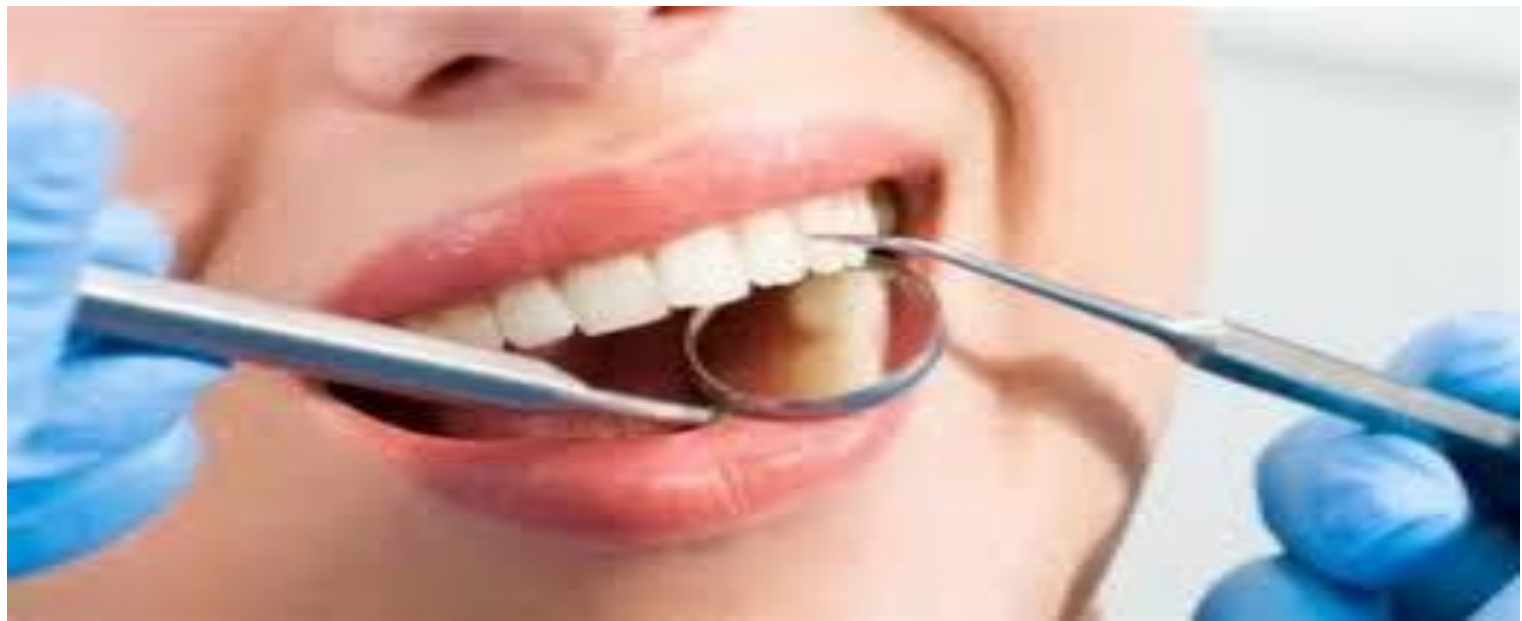

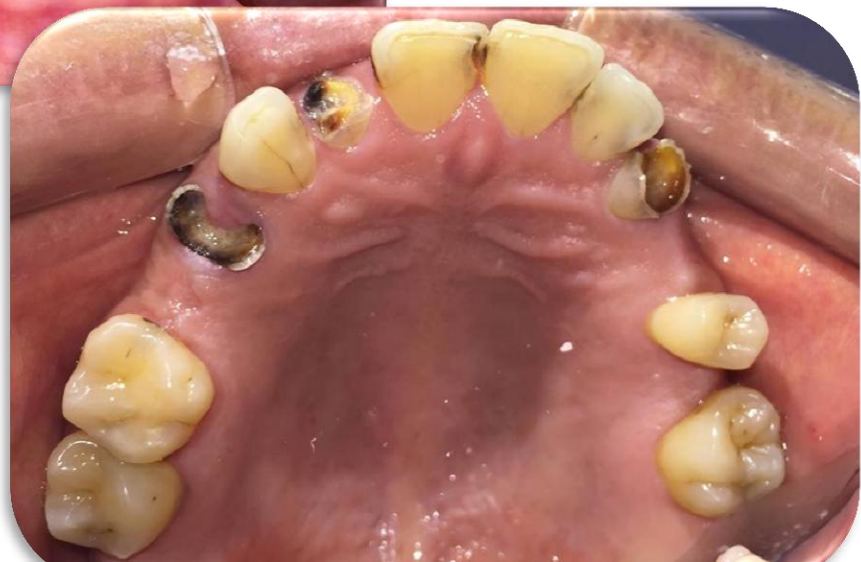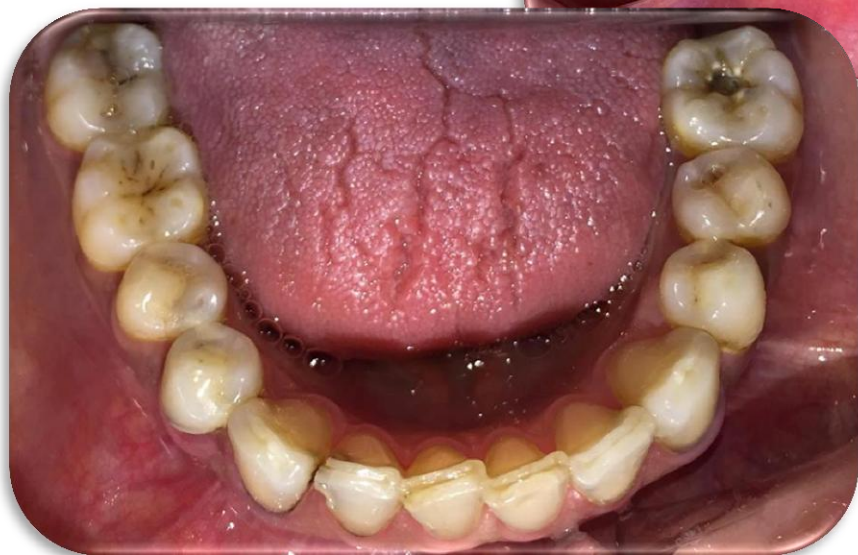
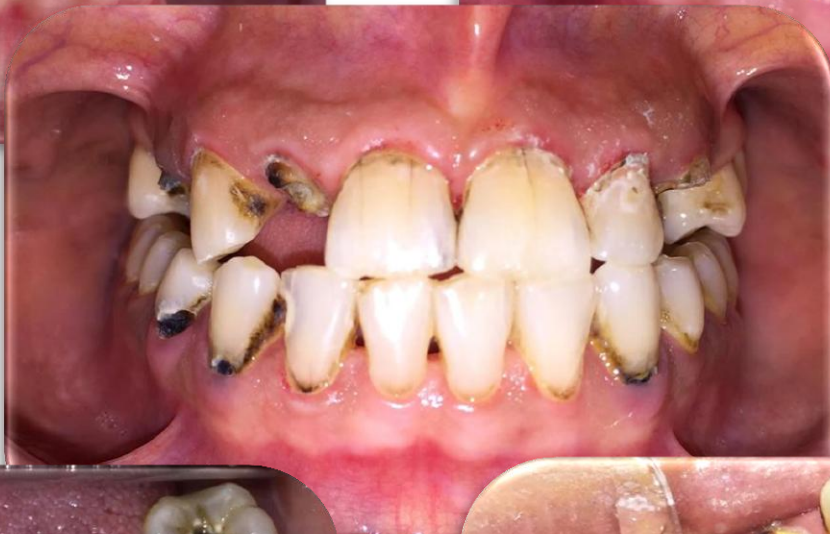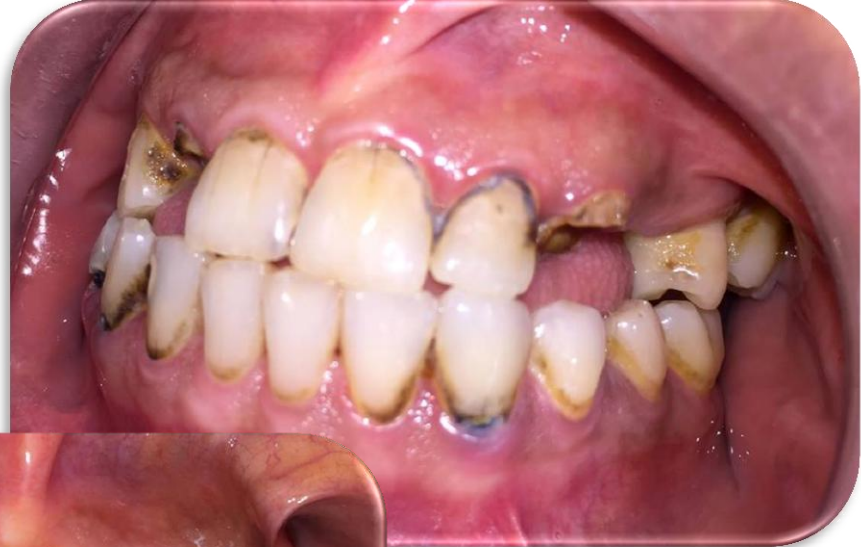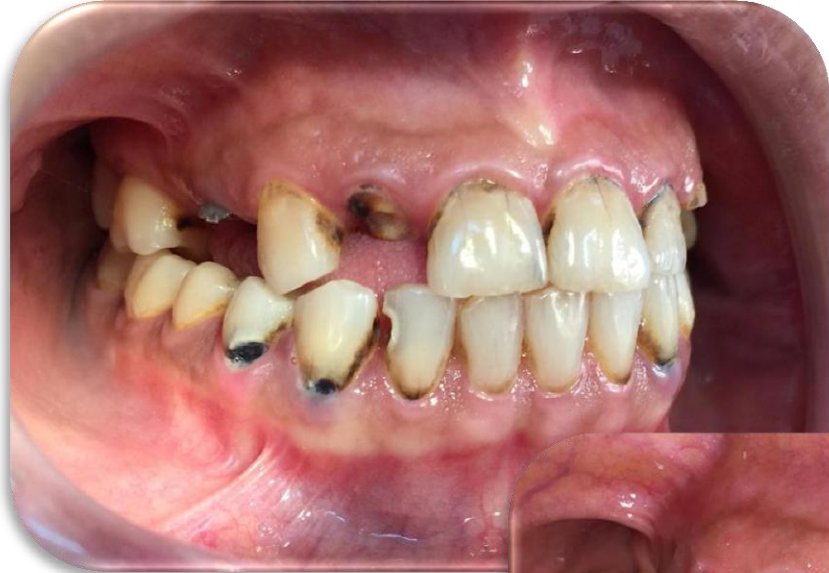| | | |
|----|----|----|
| 16 | 11 | 26 |
| 0 | 0 | 0 |
| 0 | 0 | 0 |
| 46 | 31 | 36 |

OHI-S 16+ 0 = 2.6

Good (0-0.2) fair (1.3-3) poor (3.1-6)

| M | S | D | M | RR | D | RR | D | D | D | D | M | D | M | S | M |
|---|---|---|---|----|---|----|---|---|---|---|---|---|---|---|---|
| 8 | 7 | 6 | 5 | 4 | 3 | 2 | 1 | 1 | 2 | 3 | 4 | 5 | 6 | 7 | 8 |
| 8 | 7 | 6 | 5 | 4 | 3 | 2 | 1 | 1 | 2 | 3 | 4 | 5 | 6 | 7 | 8 |
| M | D | D | D | D | D | D | S | S | S | D | S | D | D | M | M |





Differential diagnosis of chief complain :

1, dental caries $\frac{65321}{765432} \mid \frac{12346}{356}$

2. preapical granuloma $\frac{4}{\quad} \mid$

3. Chronic preapical periodontitis $\frac{2}{\quad} \mid 3$
 \chronic preapical abcess

PERIO CHART



CompuDent

PERIODONTAL CHART

PATIENT NAME: [REDACTED] FILE NO.: _____ DATE: _____

Pre-treatment Re-evaluation Recall maintenance

Diagnosis
clinical attachment loss
plaque

| | | | | | | | | | | | | | | | | | | | |
|--------------|---|---|---|---|---|---|---|---|---|---|---|---|---|---|---|---|---|---|---|
| Diagnosis | | | | | | | | | | | | | | | | | | | |
| CAL, BOP | 0 | 1 | 2 | 1 | 1 | 1 | 1 | 1 | 1 | 1 | 1 | 1 | 1 | 1 | 1 | 2 | 2 | 2 | 2 |
| PD, PI, Calc | 2 | 1 | 3 | 3 | 2 | 2 | 1 | 2 | 2 | 2 | 1 | 2 | 1 | 2 | 2 | 1 | 1 | 2 | 2 |
| CEJ-GM | | | | | | | | | | | | | | | | | | | |

FACIAL

Mobility

LINGUAL

| | | | | | | | | | | | | | | | | | | | |
|--------------|---|---|---|---|---|---|---|---|---|---|---|---|---|---|---|---|---|---|---|
| CEJ-GM | | | | | | | | | | | | | | | | | | | |
| PD, PI, Calc | 3 | 2 | 2 | 2 | 1 | 1 | 1 | 1 | 1 | 1 | 1 | 1 | 1 | 1 | 1 | 2 | 2 | 2 | 2 |
| CAL, BOP | 2 | 2 | 1 | 1 | 0 | 0 | 0 | 0 | 0 | 0 | 0 | 0 | 0 | 0 | 0 | 0 | 0 | 0 | 0 |

| | | | | | | | | | | | | | | | | | | | |
|--------------|---|---|---|---|---|---|---|---|---|---|---|---|---|---|---|---|---|---|---|
| CAL, BOP | | | | | | | | | | | | | | | | | | | |
| PD, PI, Calc | 1 | 1 | 3 | 1 | 1 | 1 | 1 | 1 | 1 | 1 | 1 | 1 | 1 | 1 | 1 | 1 | 2 | 1 | 1 |
| CEJ-GM | 0 | 0 | 0 | 0 | 1 | 0 | 0 | 0 | 0 | 0 | 0 | 0 | 0 | 0 | 0 | 0 | 0 | 0 | 0 |

LINGUAL

Mobility

FACIAL

| | | | | | | | | | | | | | | | | | | | |
|-------------|---|---|---|---|---|---|---|---|---|---|---|---|---|---|---|---|---|---|---|
| CEJ-GM | | | | | | | | | | | | | | | | | | | |
| D, PI, Calc | 3 | 2 | 3 | 4 | 2 | 2 | 2 | 2 | 2 | 1 | 3 | 2 | 1 | 1 | 1 | 1 | 1 | 2 | 1 |
| AL, BOP | 1 | 0 | 1 | 3 | 1 | 1 | 1 | 1 | 1 | 1 | 1 | 1 | 1 | 1 | 1 | 1 | 1 | 1 | 1 |
| agnosis | 2 | 3 | 3 | 3 | 3 | 3 | 3 | 3 | 3 | 3 | 3 | 3 | 3 | 3 | 3 | 3 | 3 | 3 | 3 |

GM- Gingival Margin CAL- Clinical Attachment Loss CEJ- Cemento-enamel Junction PD- Probing Depth
 PI- Plaque, if presents put * Calc- Calculus, if presents put * BOP- Bleeding on probing, if presents put red

Plaque Index Bleeding Index

PERIO CHART

Clinical examination ... has bleeding on probing in right and left posterior teeth in both upper and lower and in upper anterior teeth and most highest probing depth in lower right 6 (4mm) and posterior teeth lower 6 about 3mm and in upper right 6\7 left (3mm)

Finding ... poor oral hygiene and plaque scour 3 in oral of teeth with slight redness in gingiva in all of anterior teeth

Diagnosis ... localized chronic mild periodontitis [11 %]

Prognosis ... good prognosis

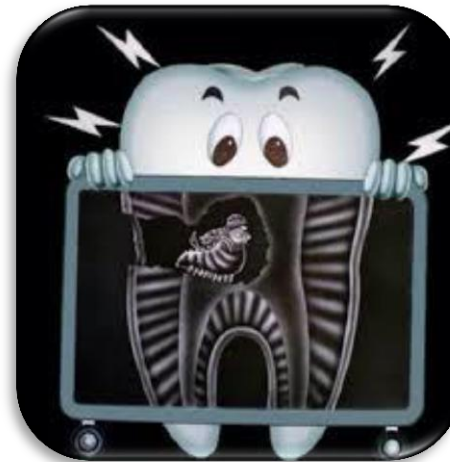Treatment ...OHI / flossing /Sealing sub -gingiva and polishing

Investigation : (Special investigation)

- Blood pressure 140\80mmHg
- percussion test

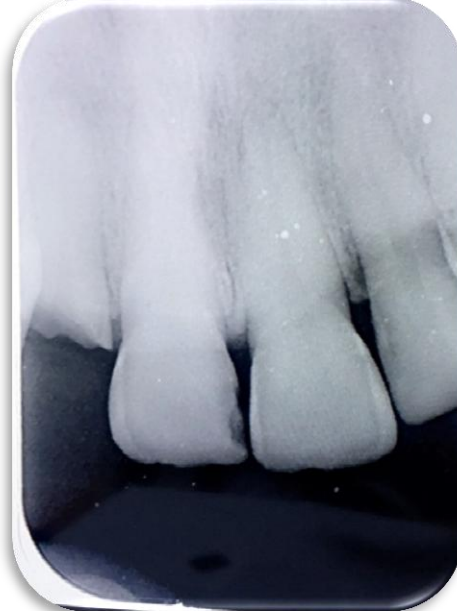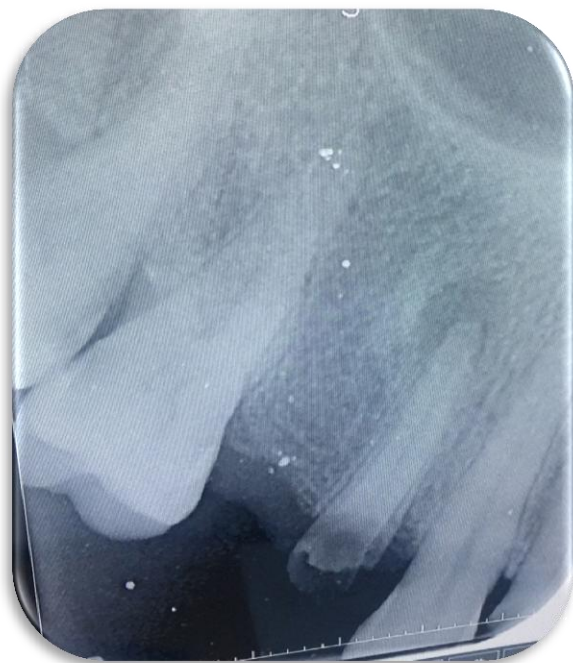| | |
|---|---|
| 2 | 3 |
|---|---|
- Vitality test

| | |
|---|---|
| 1 | 1 |
|---|---|
- X- ray :
- ✓ Intra oral preapical
- ✓ Bitwing
- ✓ OPG

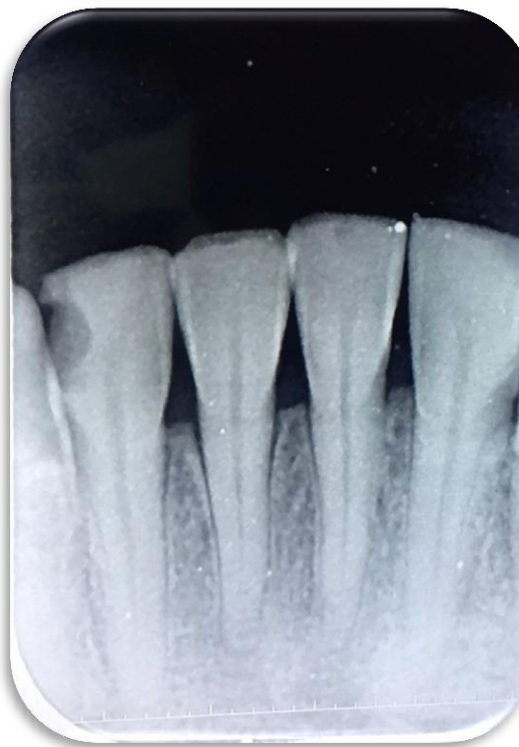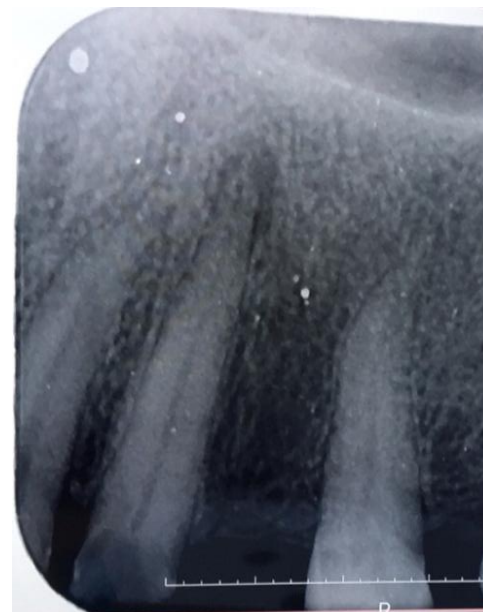


IOPR

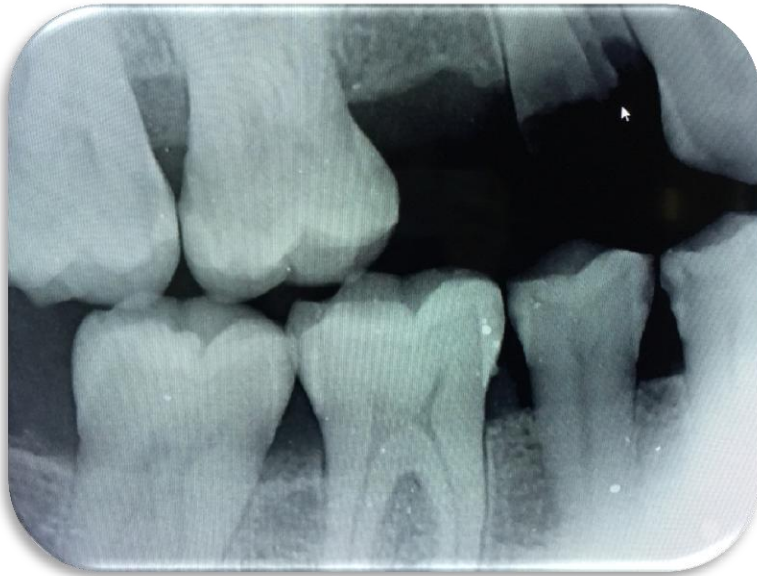Upper right side



Upper left side

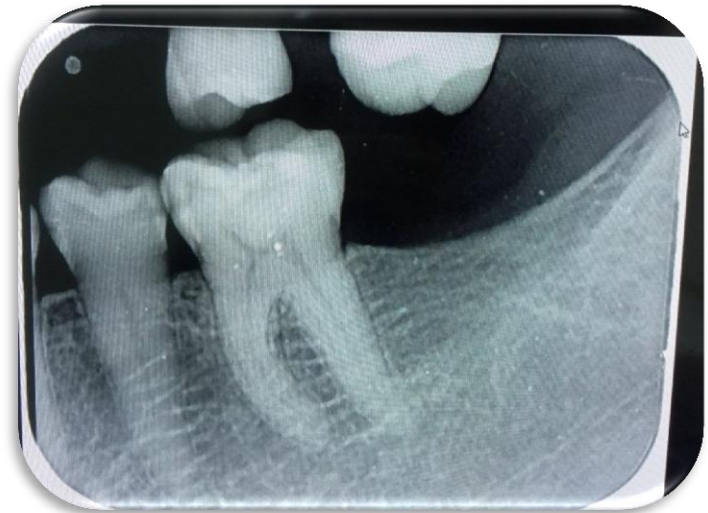

BITEWING

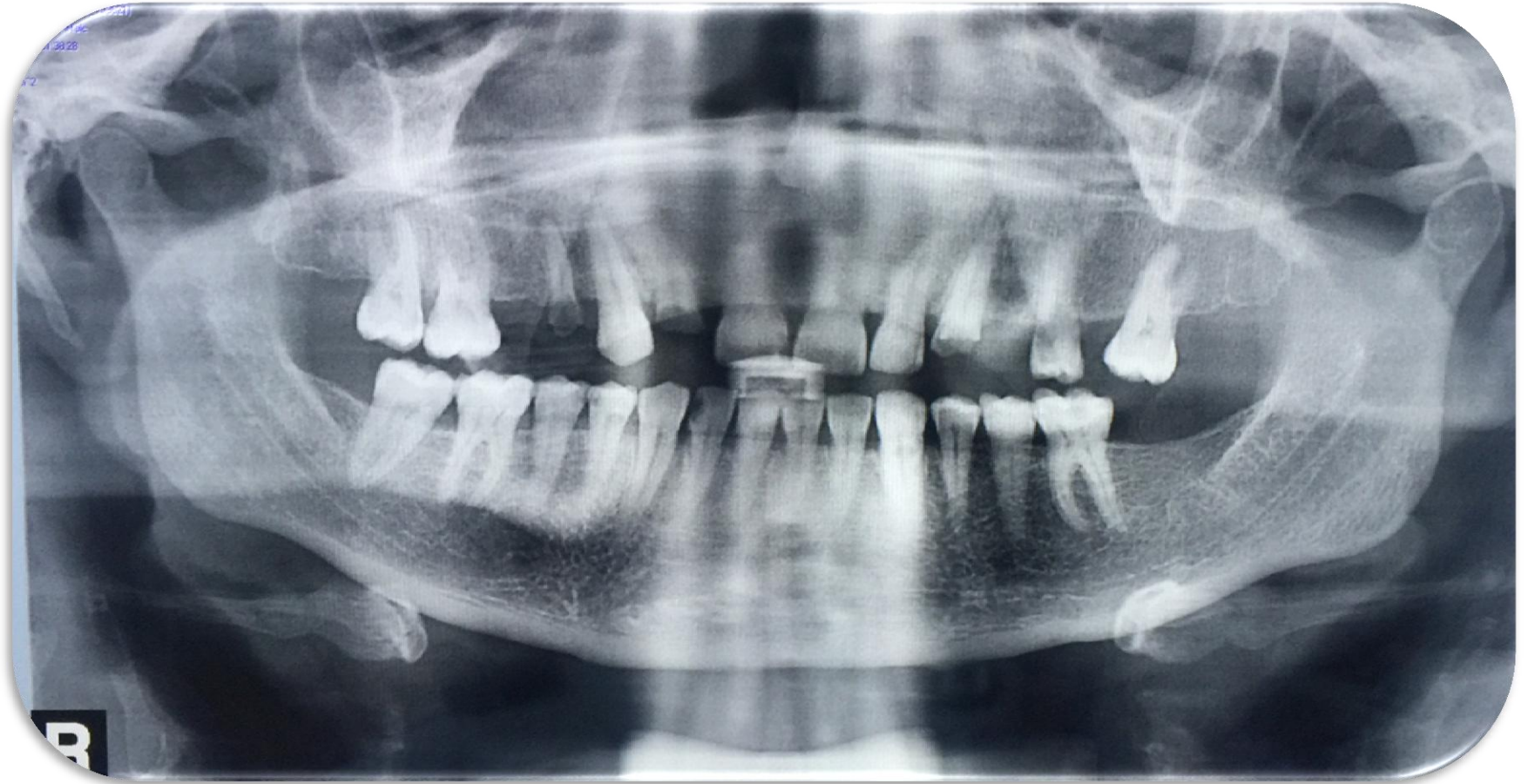

Right side

Left side



OPG



Final diagnosis :

1. Localized mild chronic periodontitis

2. preapical granuloma 4

3. Chronic preapical periodontitis 2 3

4. Dental caries

| | |
|--------|-------|
| 65321 | 12346 |
| 765432 | 356 |

Treatment plan :

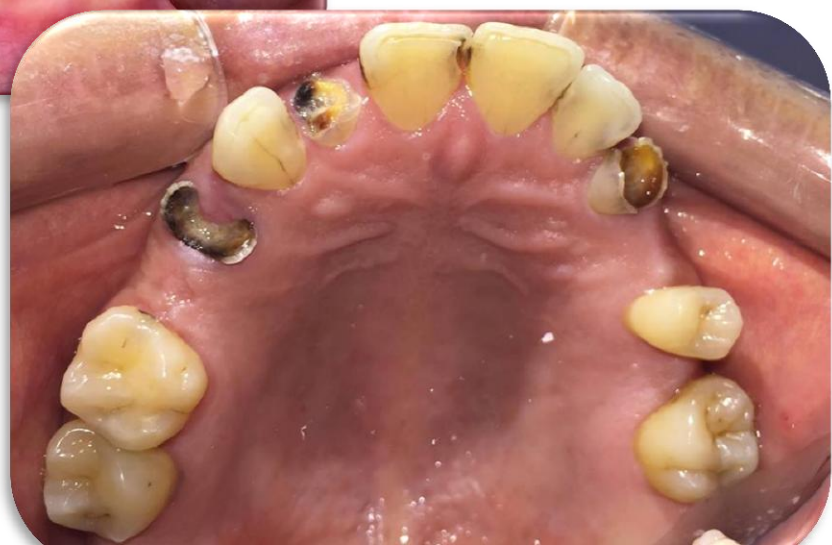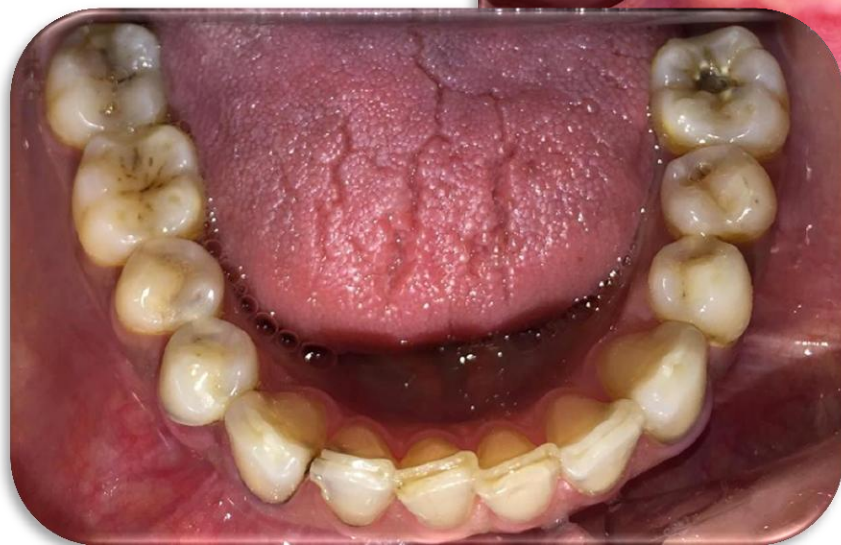
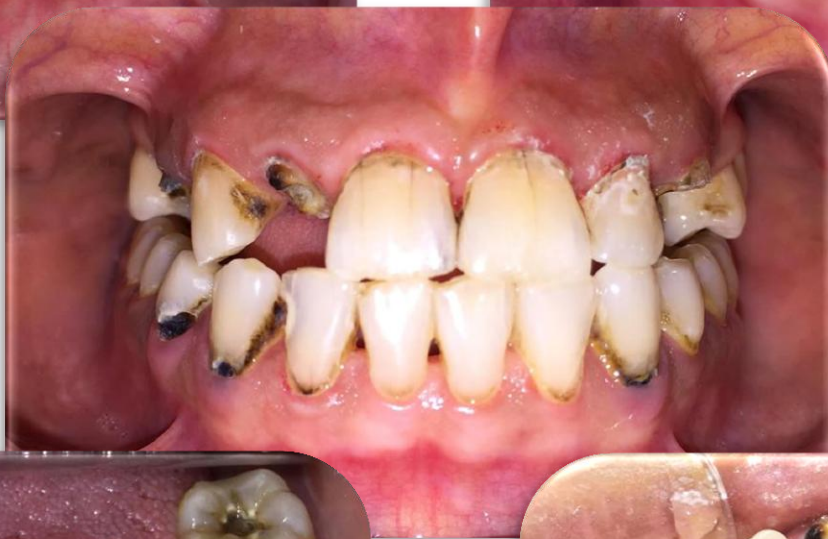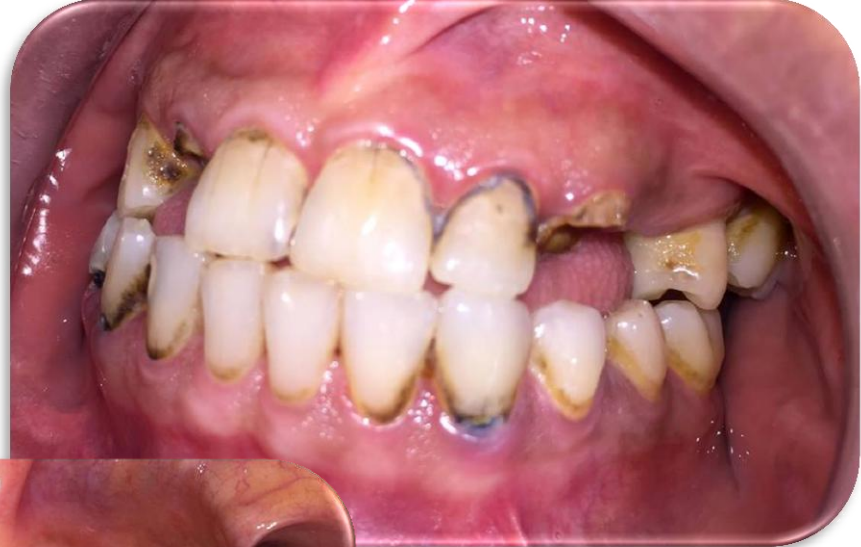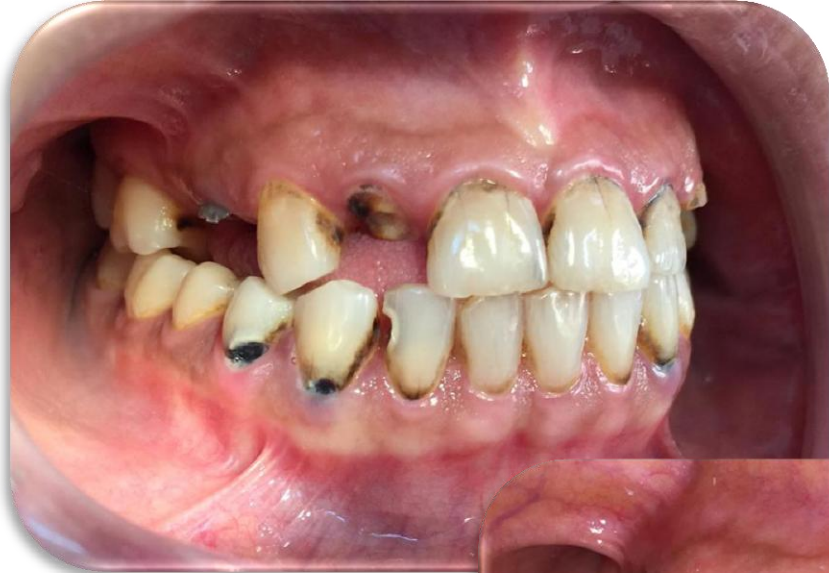1. OHI ,Scaling , polishing , fluoride application

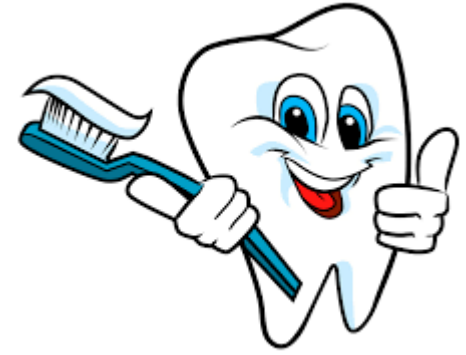2. Exo RR $\begin{array}{c|c} 4 & \\ \hline & \end{array}$ crown lengthening for $\begin{array}{c|c} 2 & 3 \\ \hline & \end{array}$

3- Endo $\begin{array}{c|c} 2 & 3 \\ \hline & \end{array}$

4- Restorative $\begin{array}{c|c} 65321 & 12346 \\ \hline 765432 & 356 \end{array}$

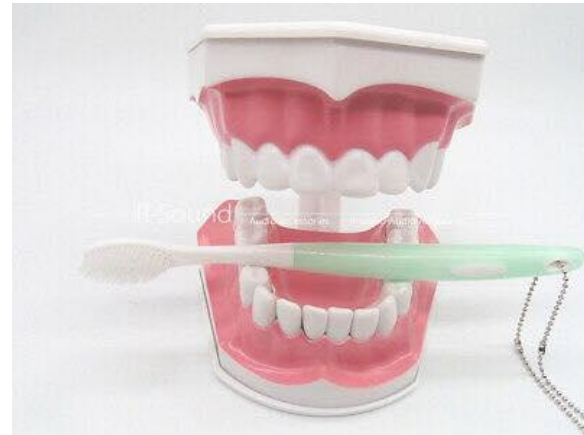5- Replacement : fixed $\begin{array}{c|c} 2 & 3 \\ \hline & \end{array}$ remove RPD $\begin{array}{c|c} 54 & 4 \\ \hline & \end{array}$

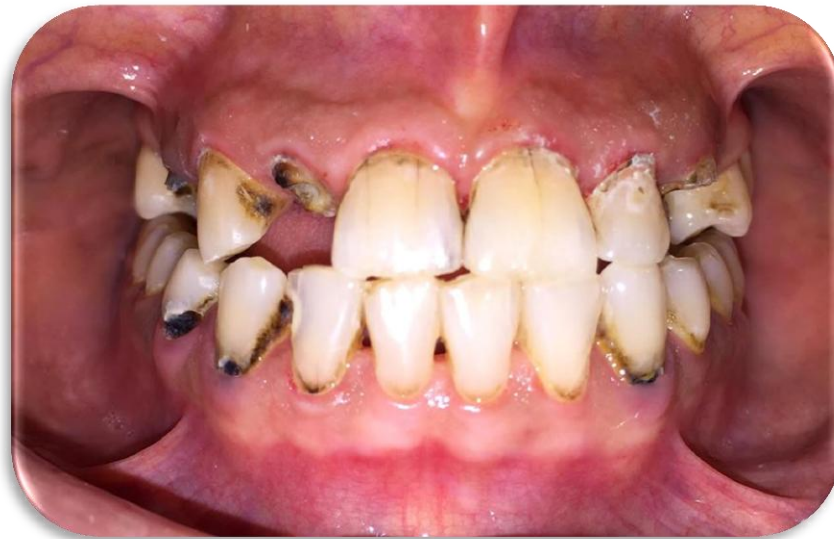
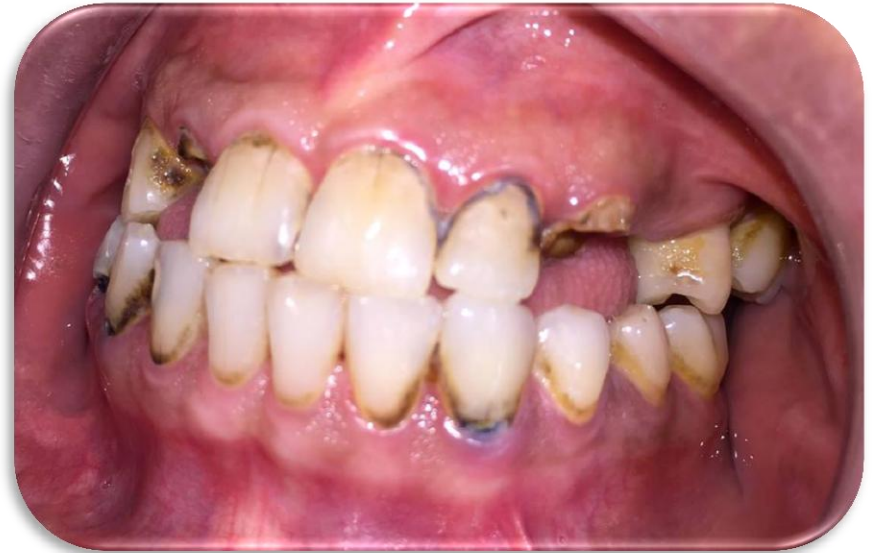
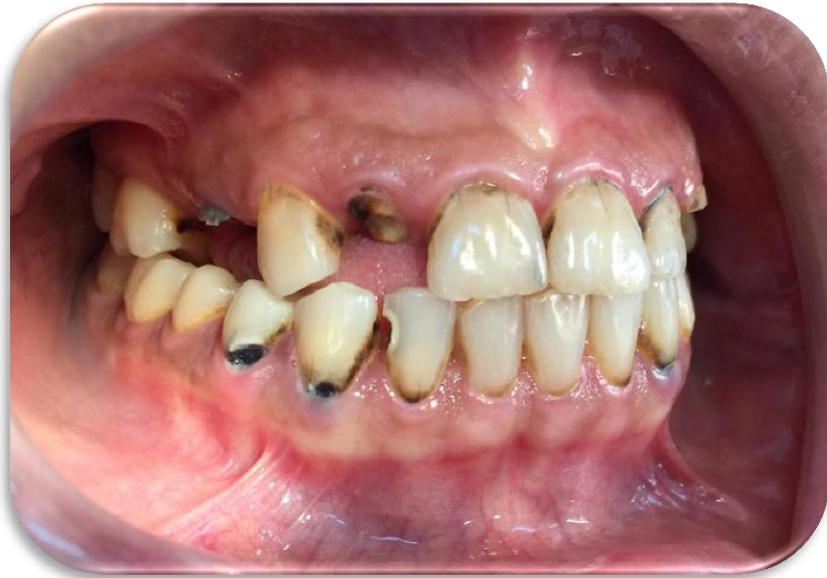

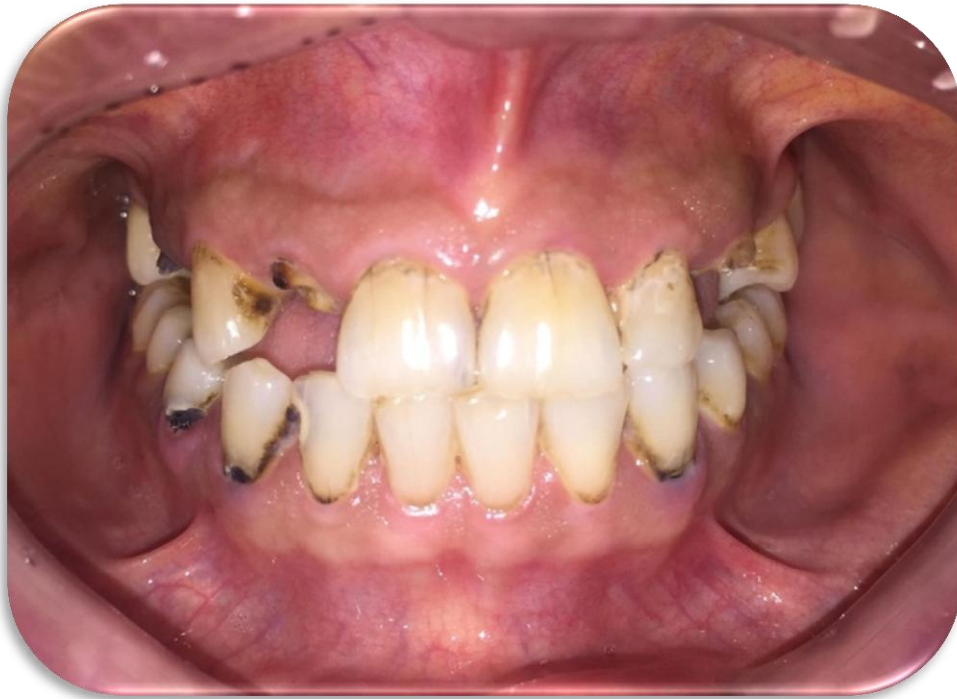Phase one therapy

OHI , Scaling and polishing

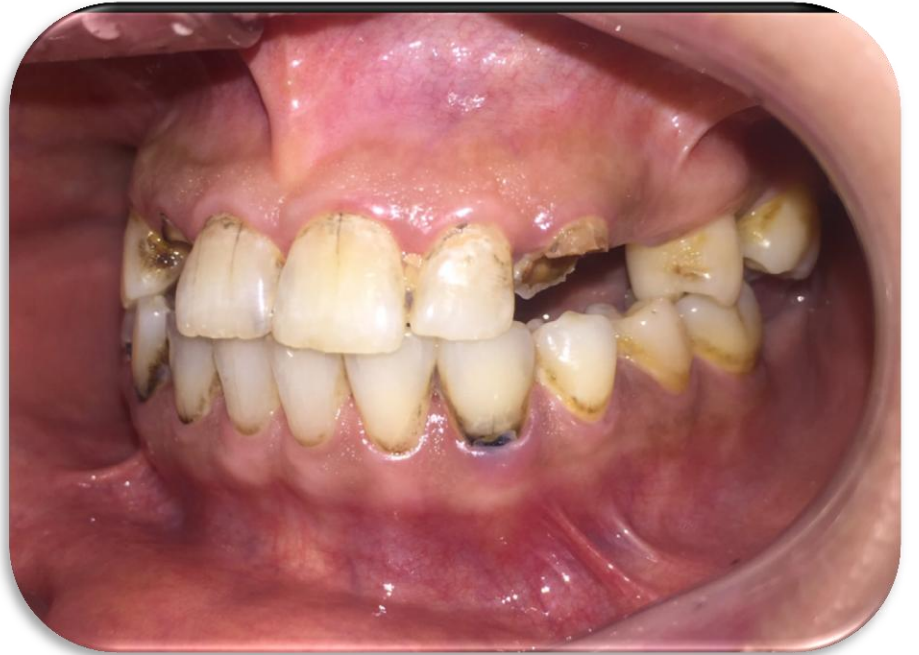
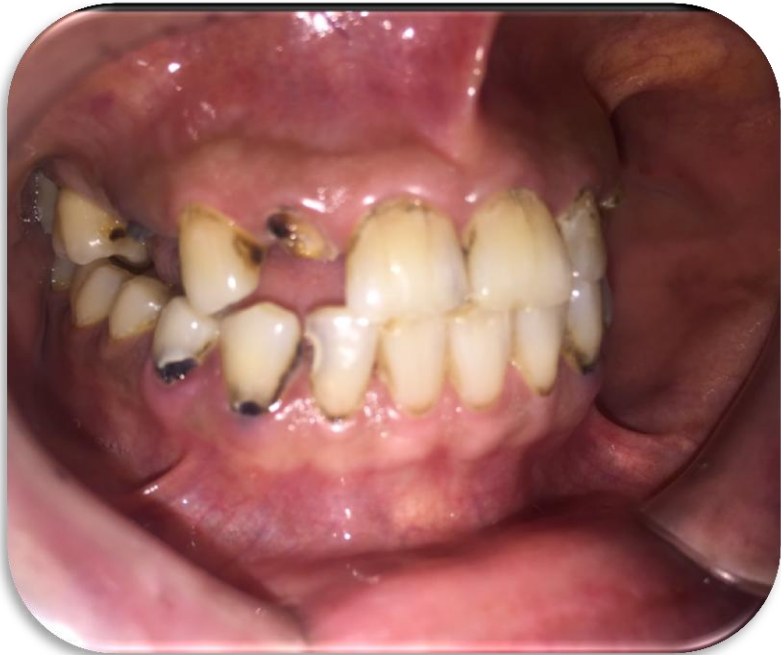


BEFORE



AFTER

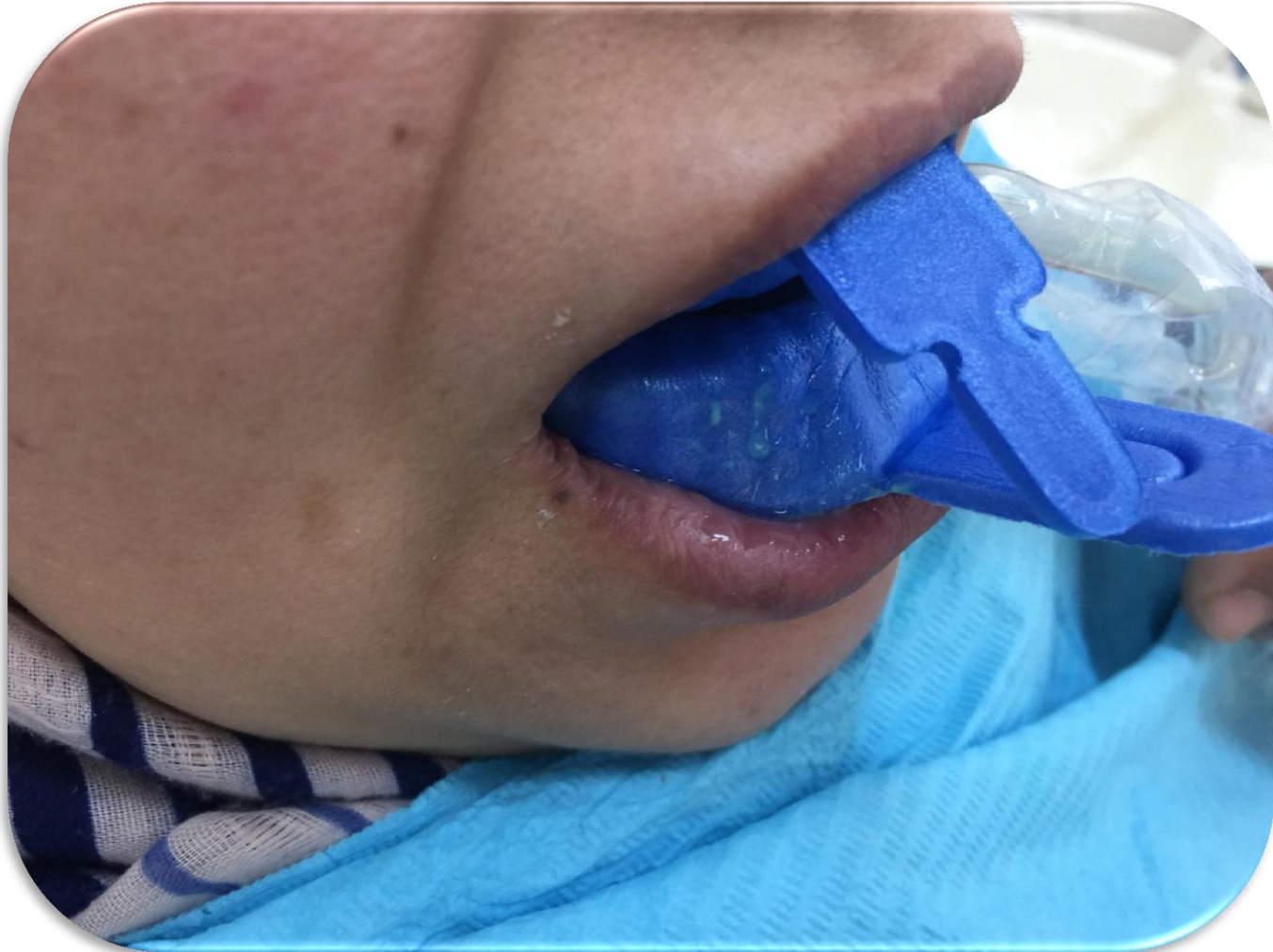

Diet sheet

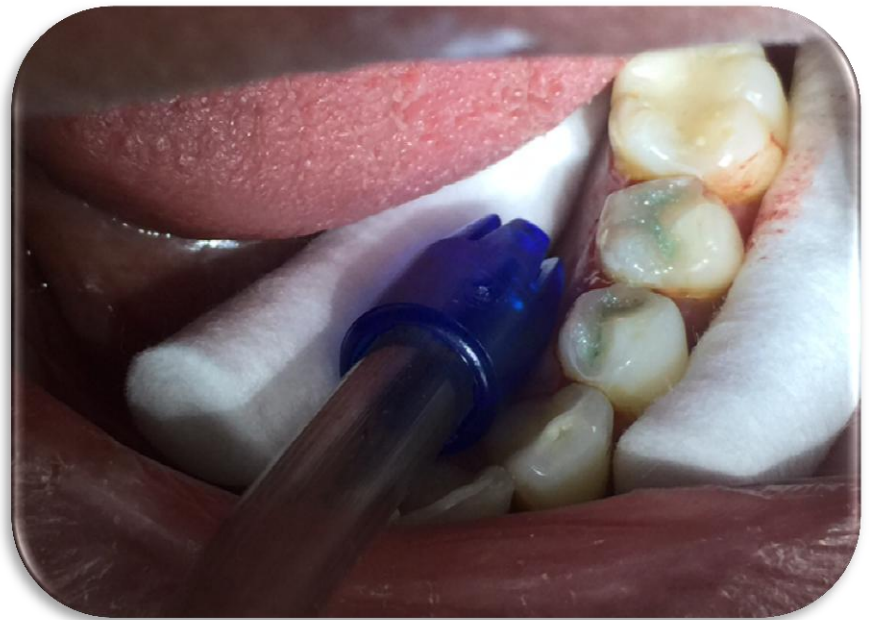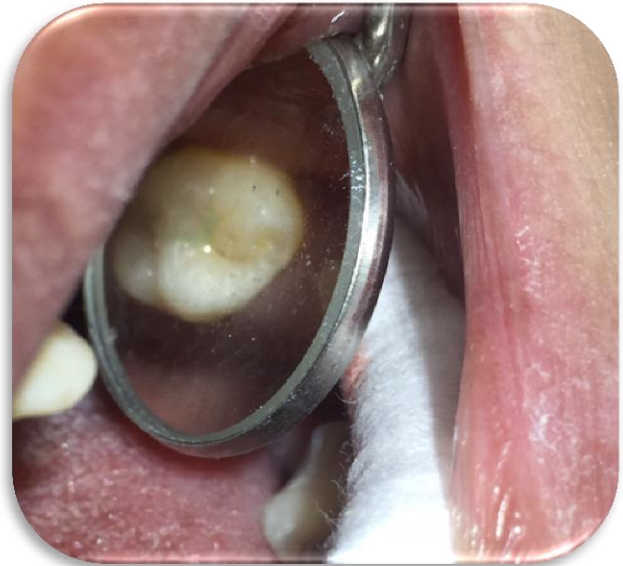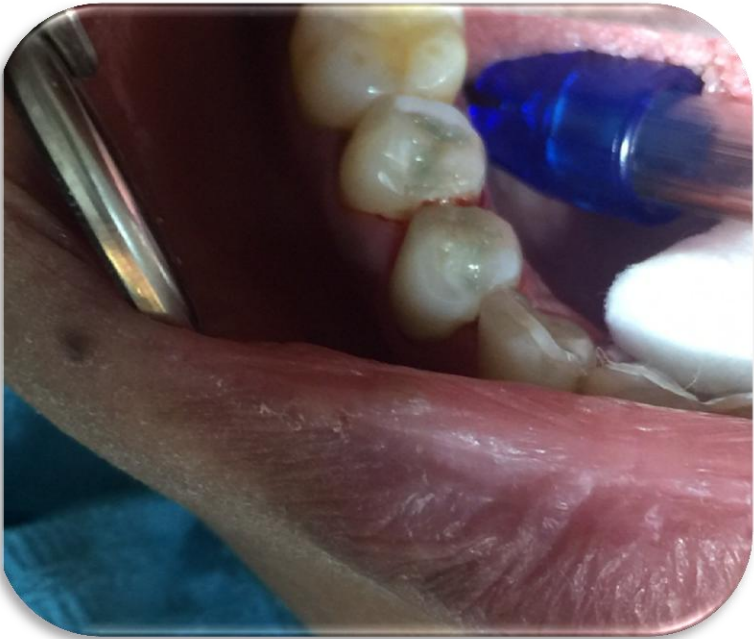Patient Name: [REDACTED] Gender: M/F Date of Birth: 19/7/31/86
 Occupation: [REDACTED] Address: [REDACTED]

| نوع الوجبة | المأكولات والمشروبات | الساعة | الأيام |
|------------|---|---------------|----------|
| فطور | كوب حليب | 9:52 | الأربعاء |
| | مافن كريك | 12:30 | |
| غداء | أرز وسلطة | 2:30 | الخميس |
| عصيرة | قهوة حلويات مع نوعين | 6:22 | |
| | عصير خاواله كونه شاهه + حنبرة كوب حليب | 11:00 | |
| فطور | حليب | 8 | الجمعة |
| غداء | قاصدلاء وسلطة | 2:22 | |
| عصيرة | قهوة ديكلاوة في المصروف | 6:30 | |
| | صالح دجبر غداء صفتيف | 7:12 11 | |
| فطور | حليب وسندوتش صينة | 9:20 | الجمعة |
| غداء | كيسكو و خلتل ماكش وسلطة | 2:30 | |
| عصيرة | قهوة و قهوية + عصير طبيعي | 6:22 | |
| غداء | عصير أحمد و تيرا قاصدلاء و برال وسلطة | 7:12 10:44 | |

fluoride application

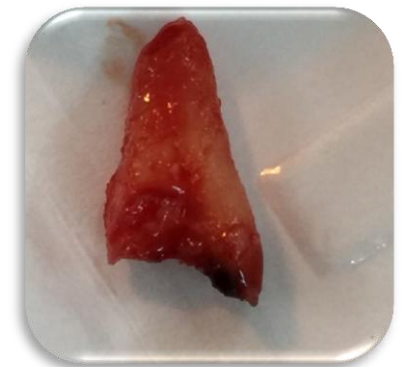
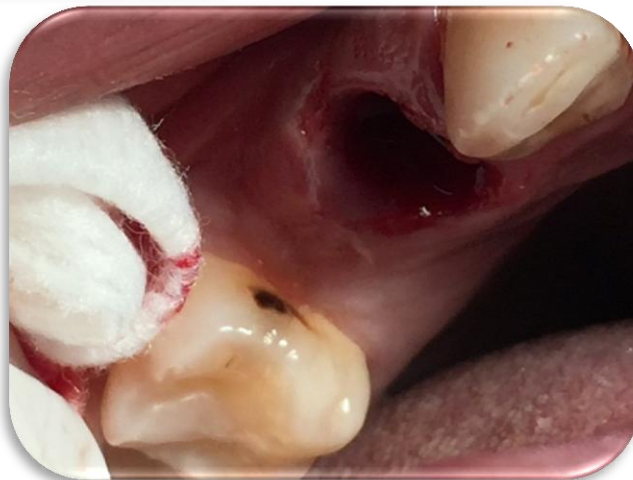
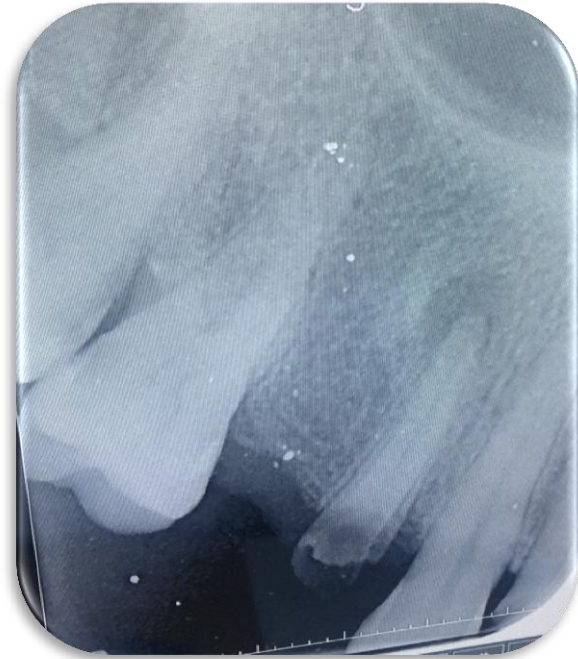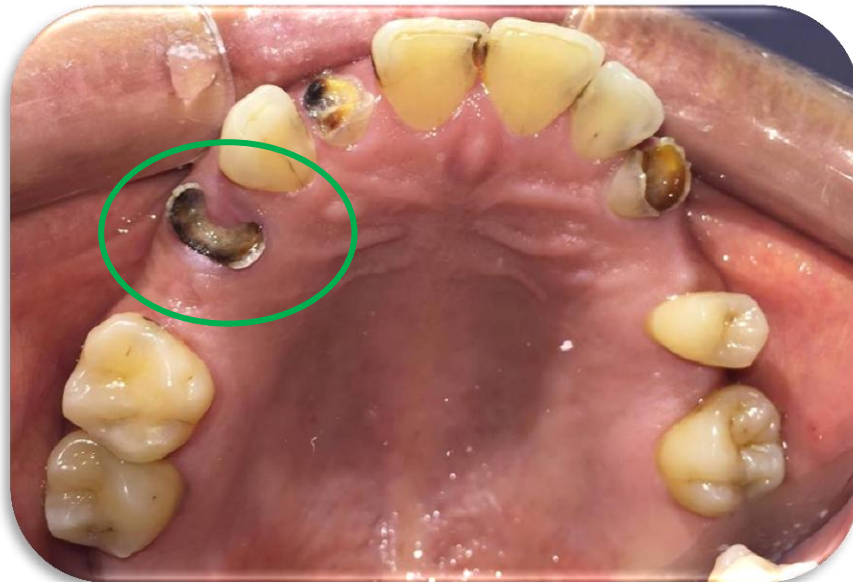Pit and Fissure Sealant

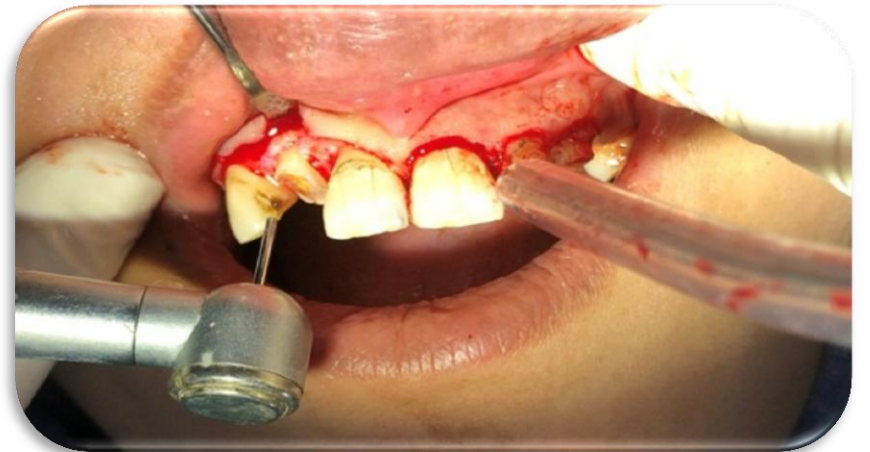
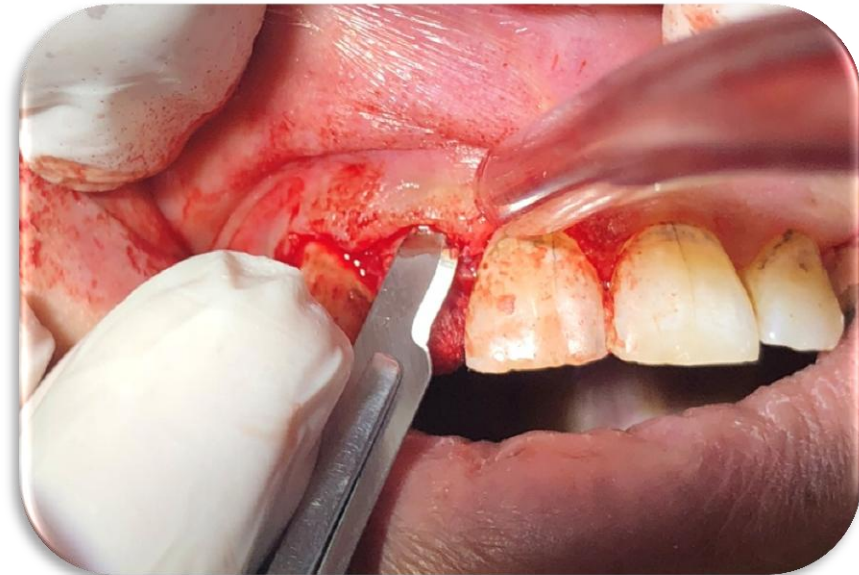
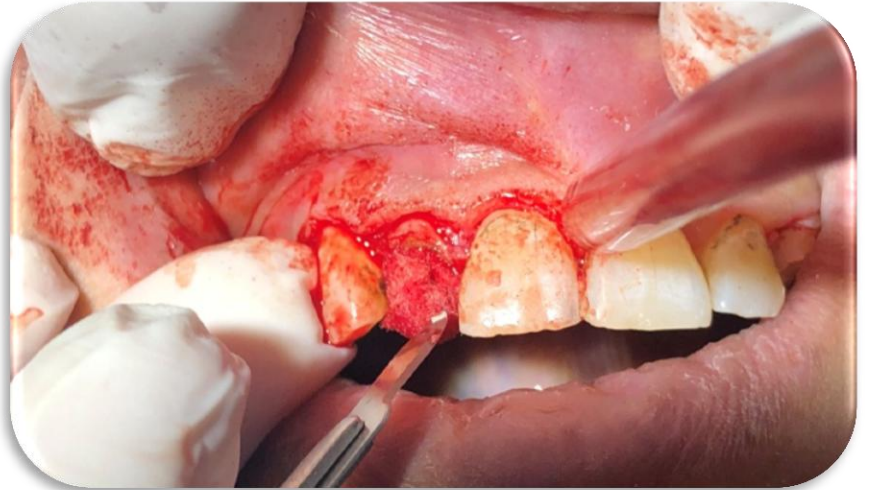
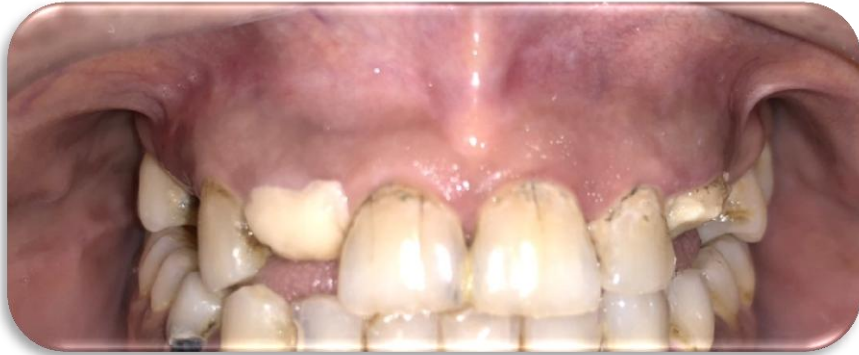

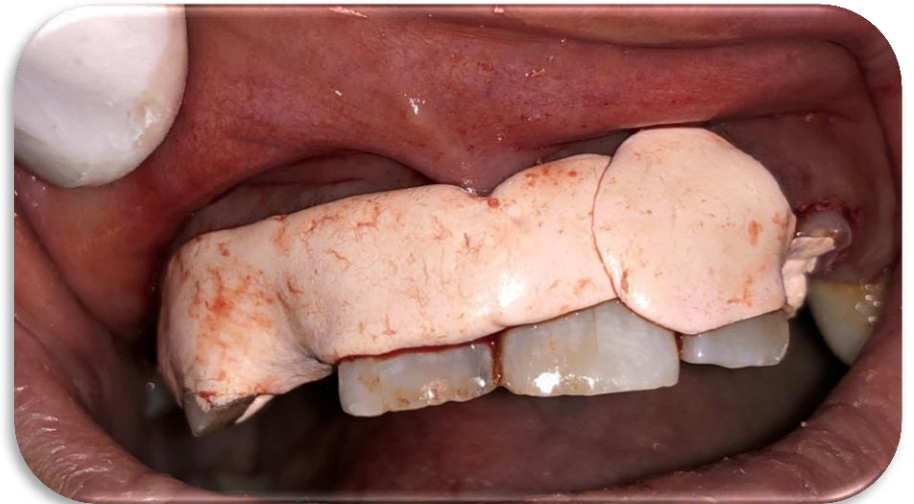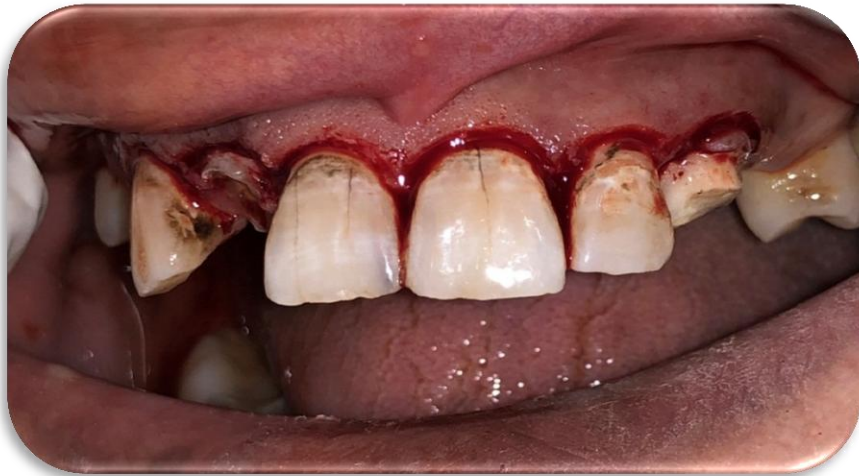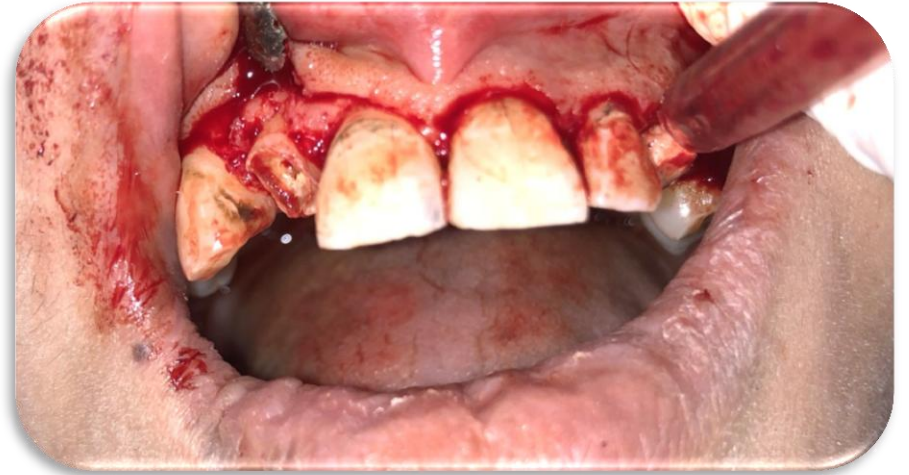
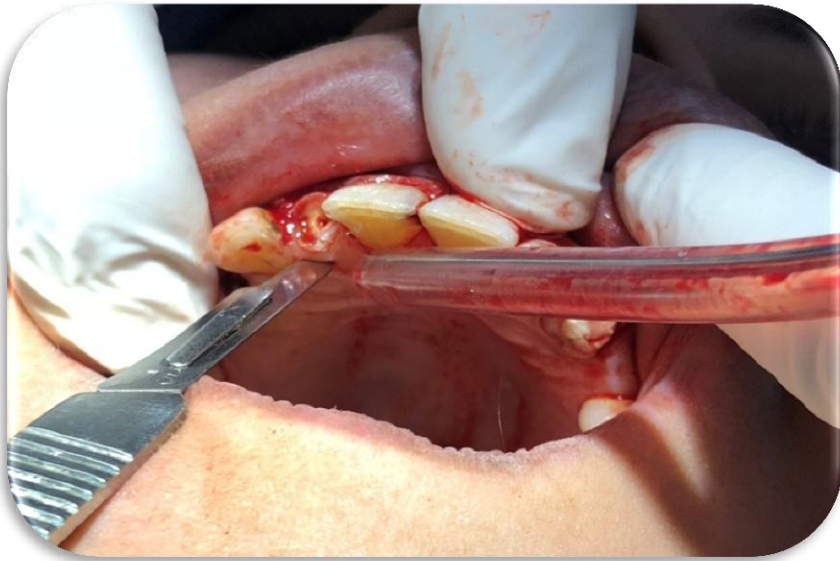Phase two therapy

Exo upper right 4

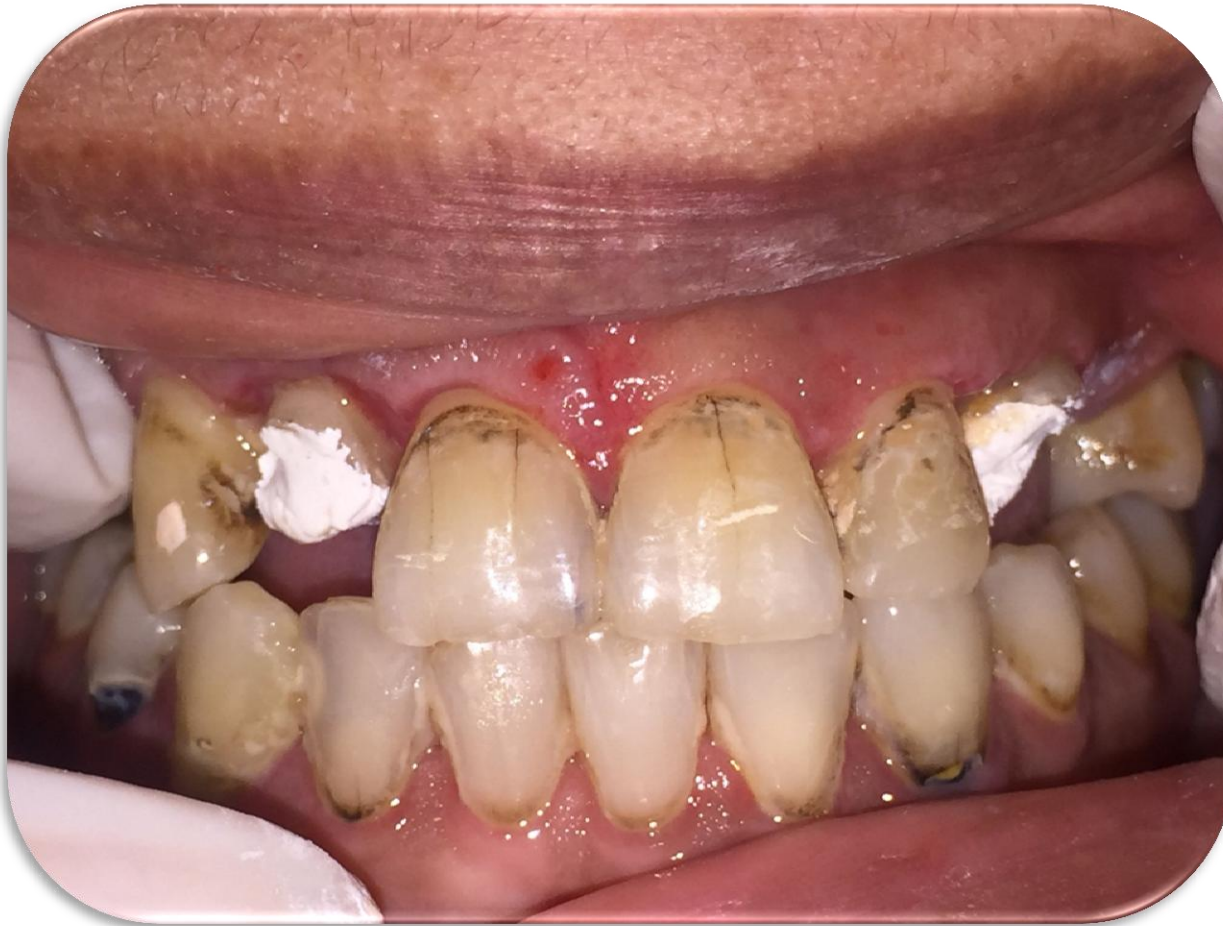

Crown Lengthening

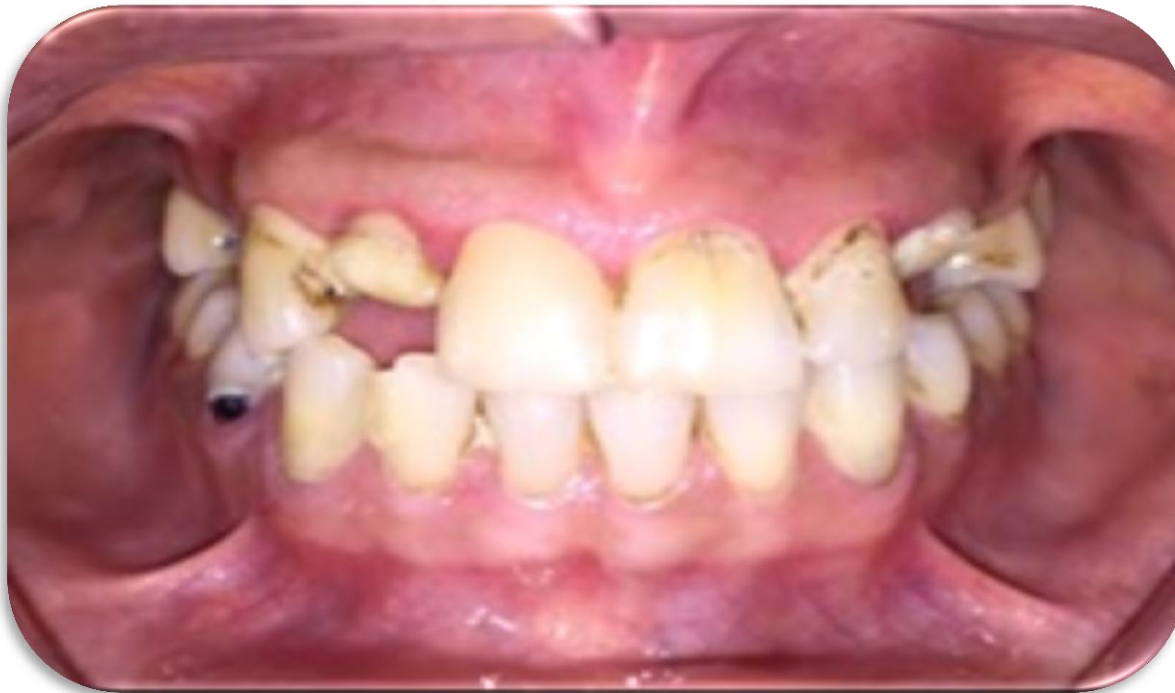



Re-evaluation after 1 week

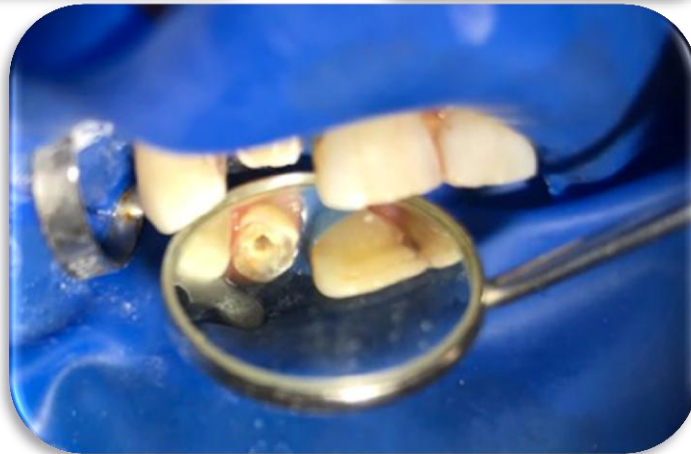
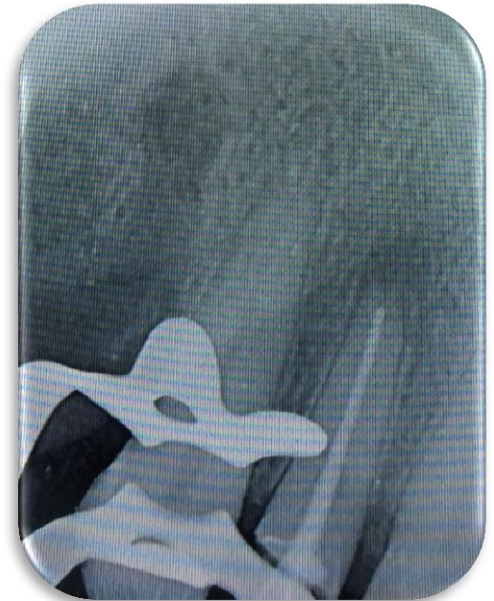
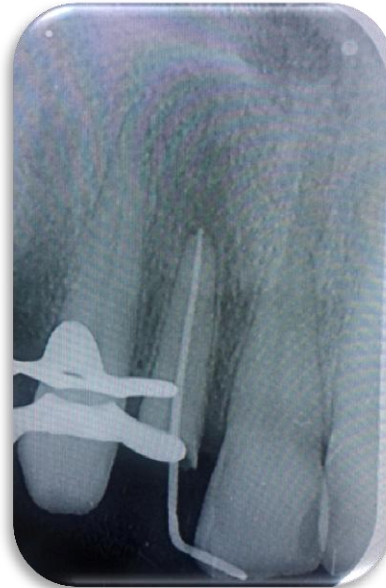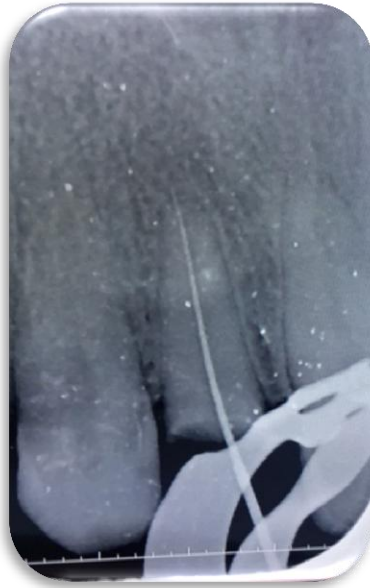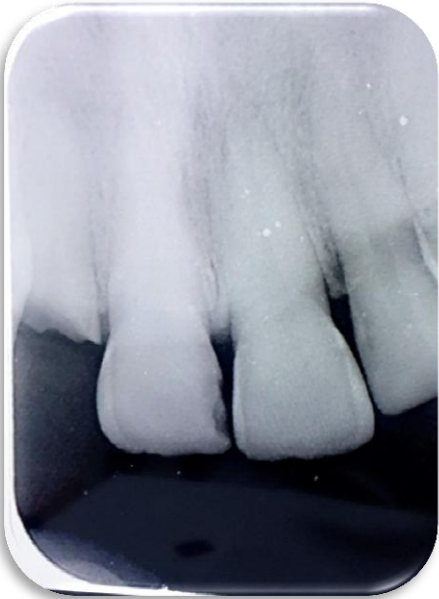Re-evaluation after 3 week

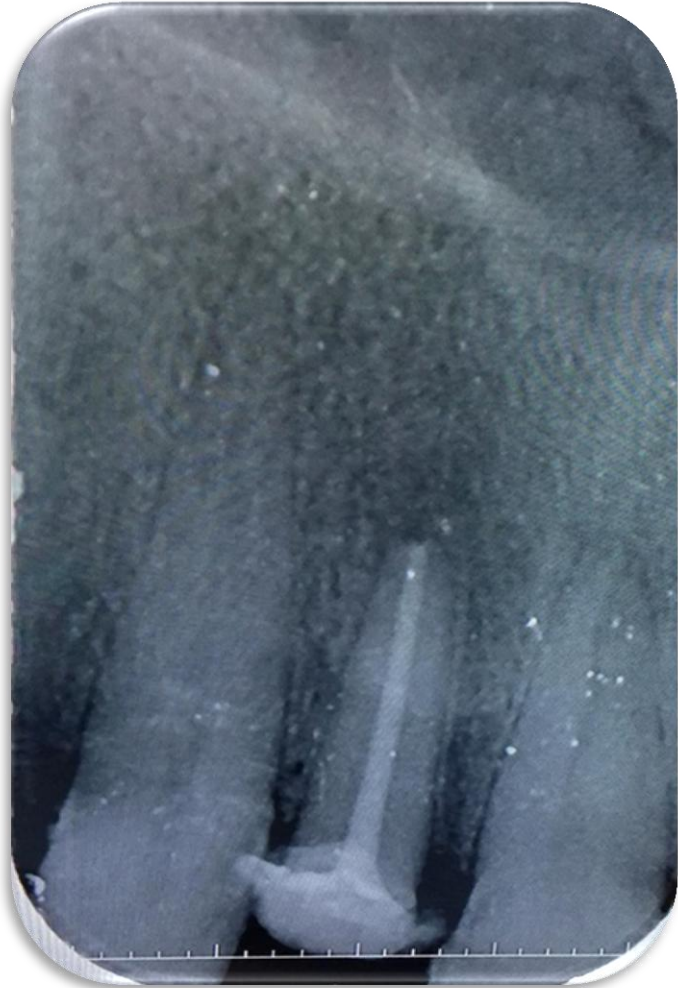
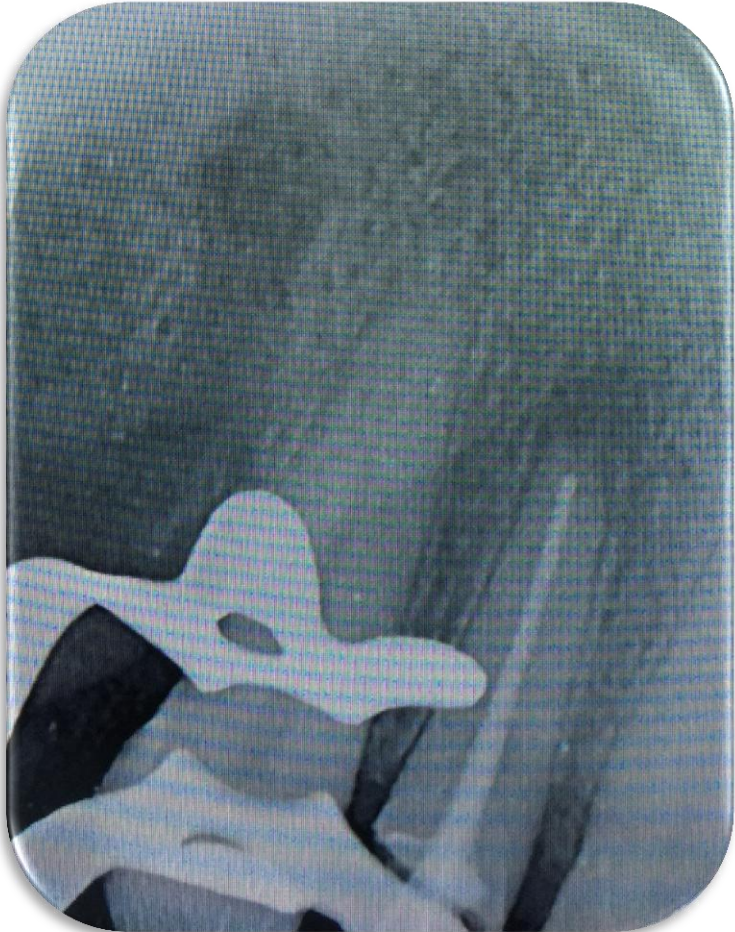
Phase three therapy

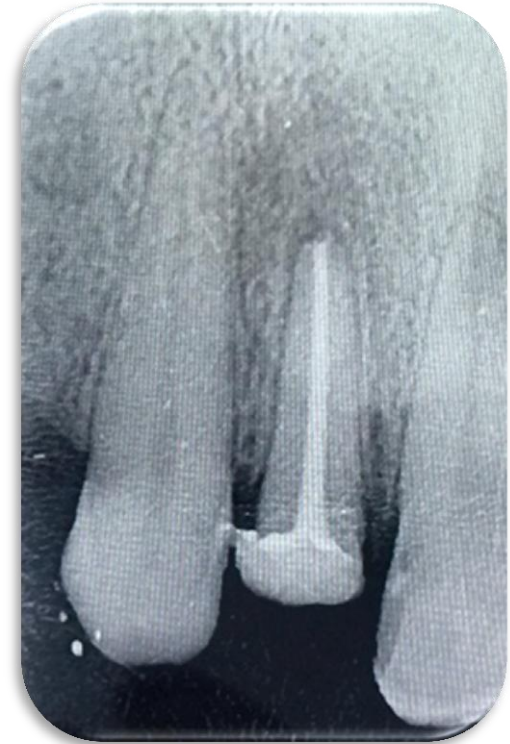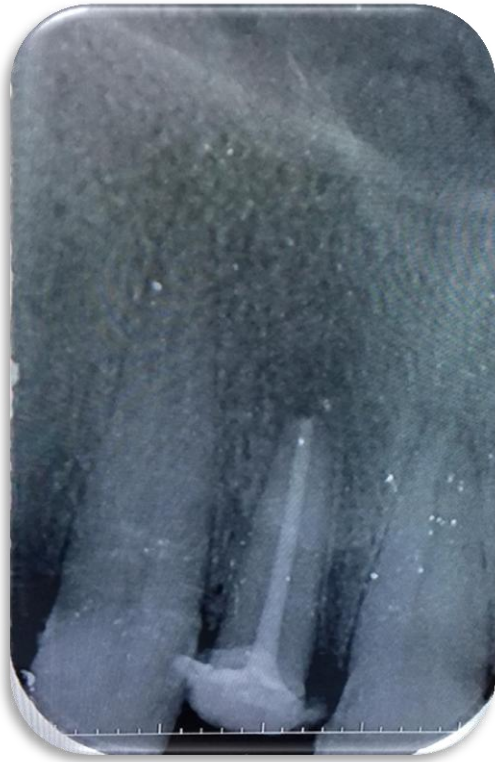Endo upper right lateral Incisor



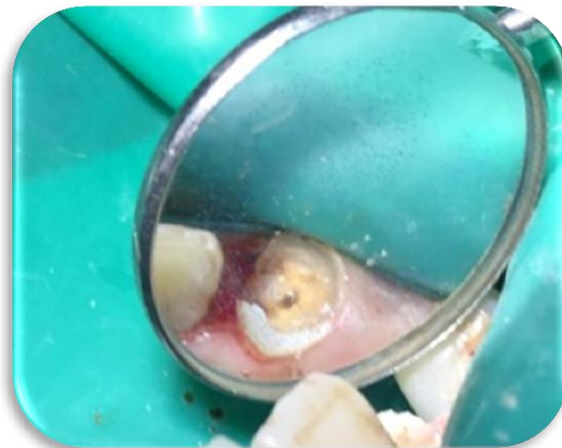
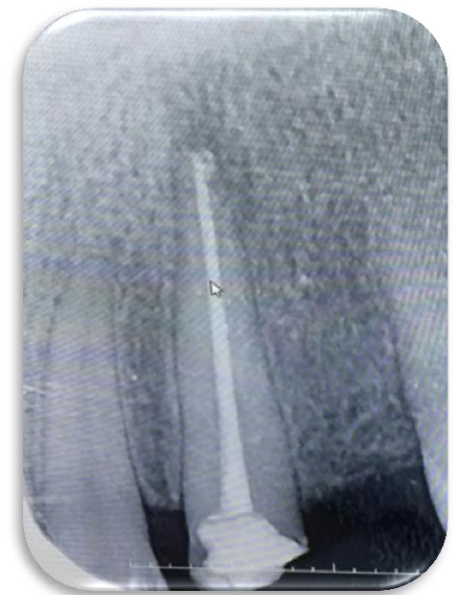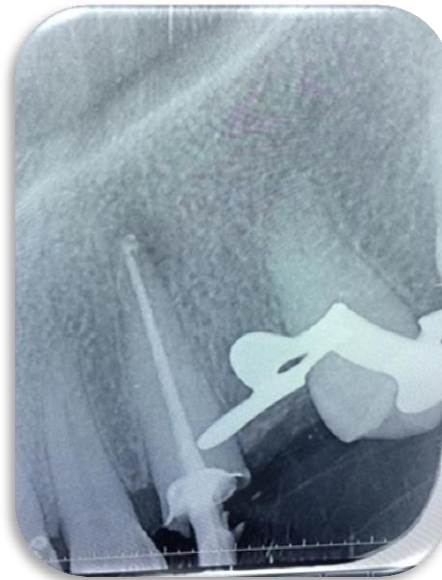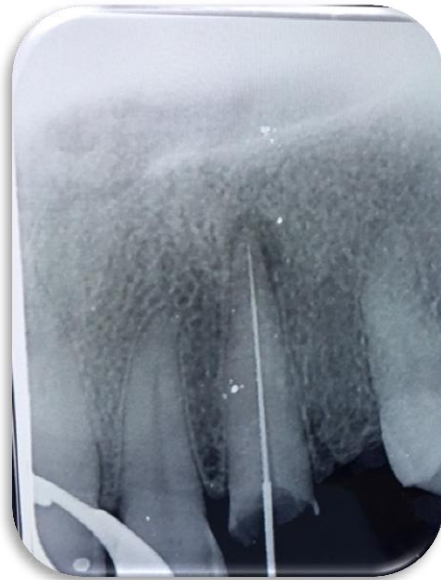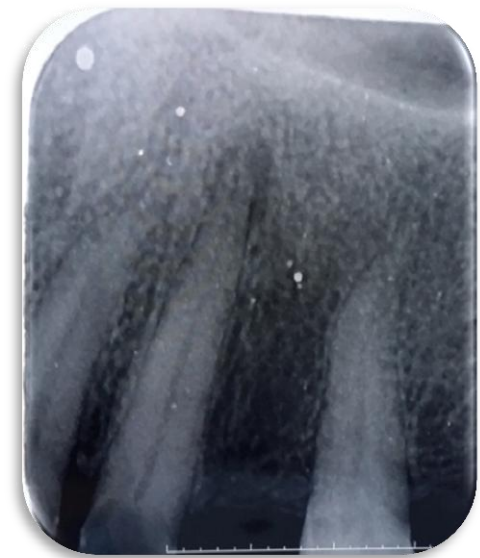Re-Treatment



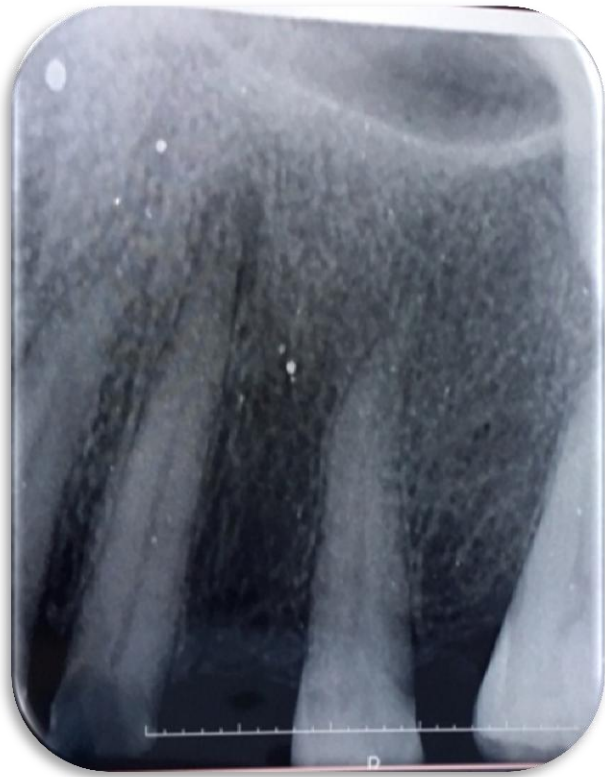After 2 Mouth



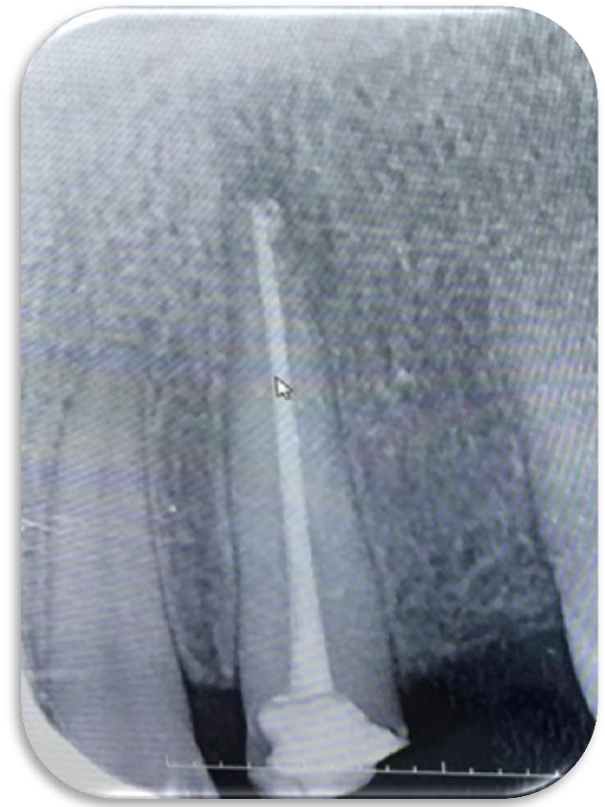Endo upper left canine



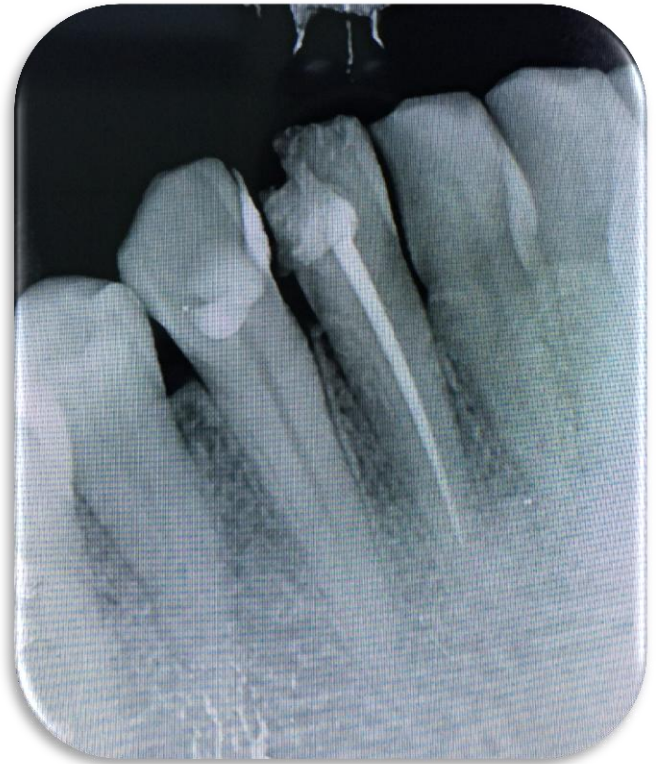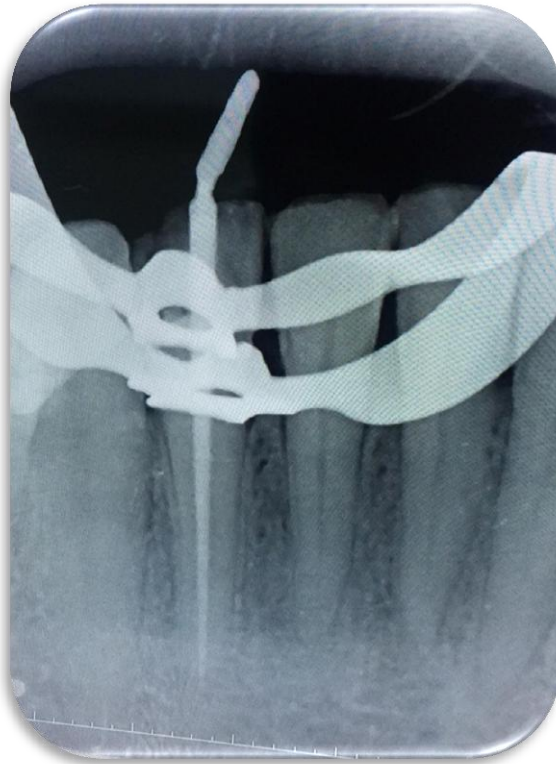
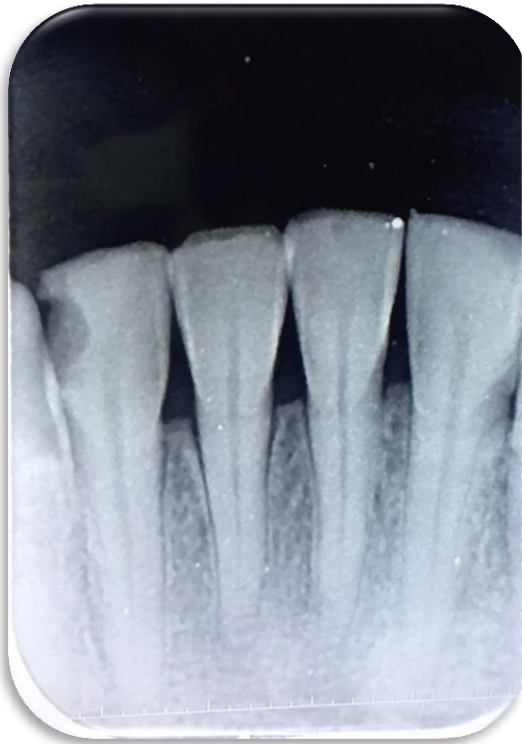
Before



After

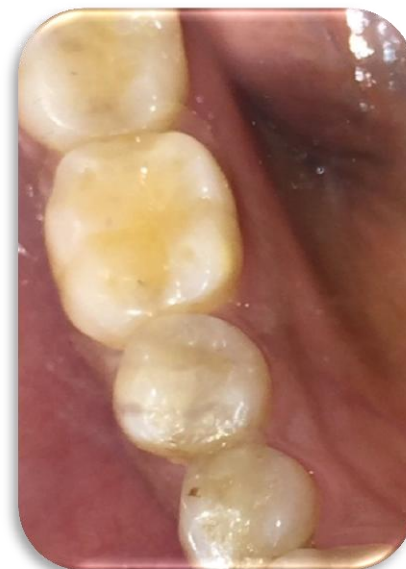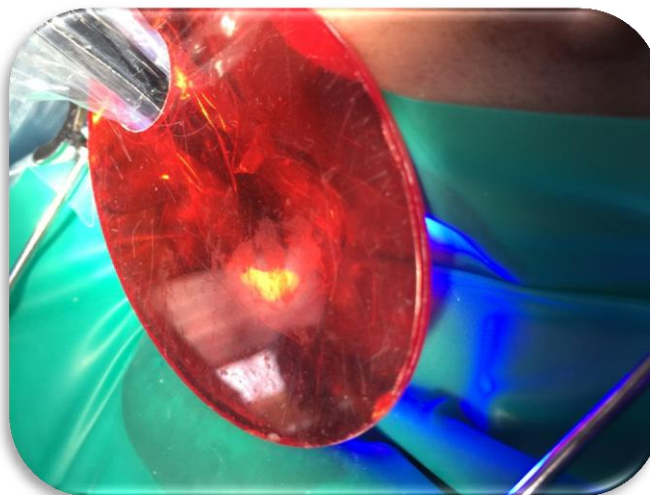
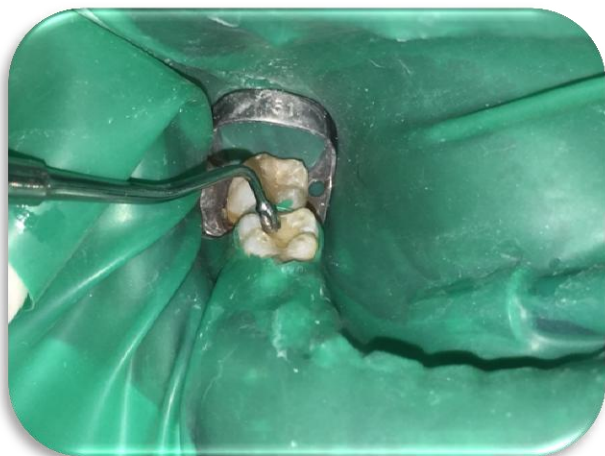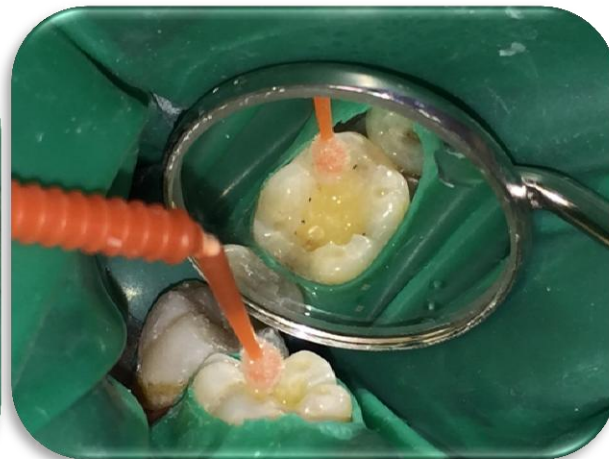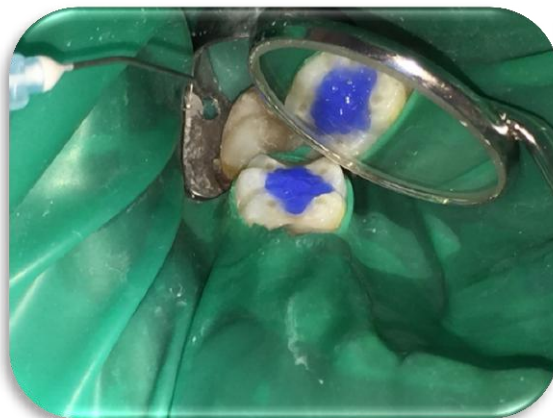


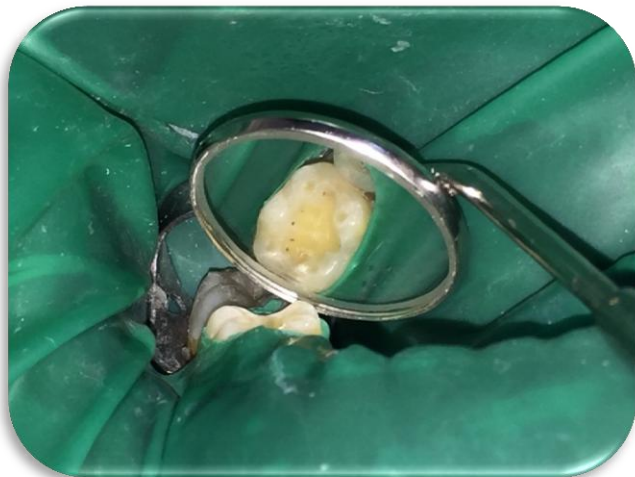Endo Lower Right lateral Incisor

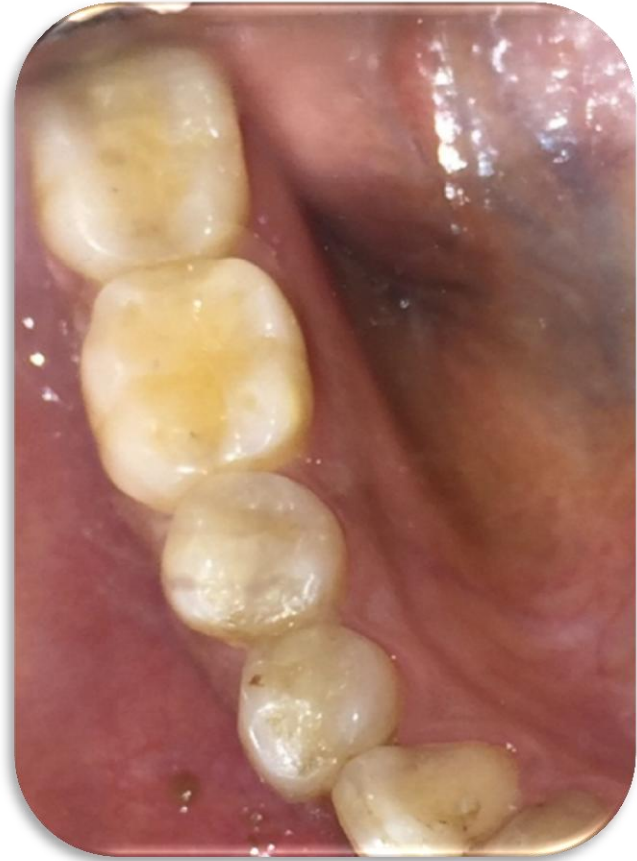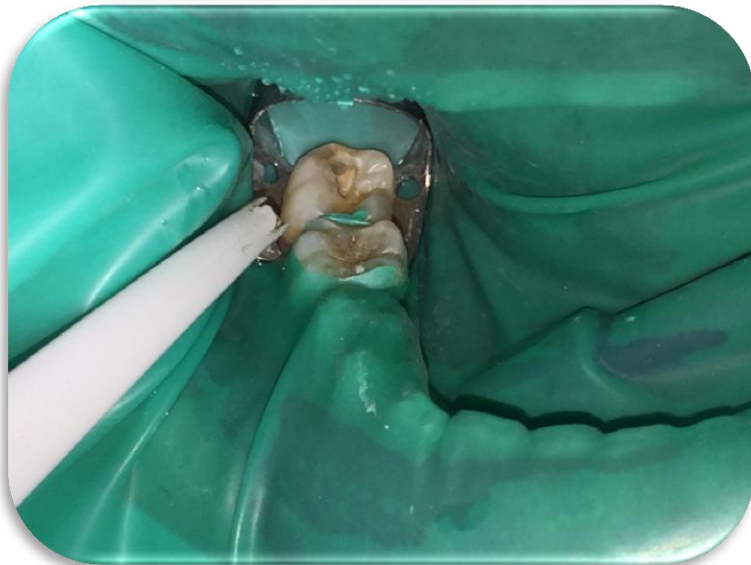

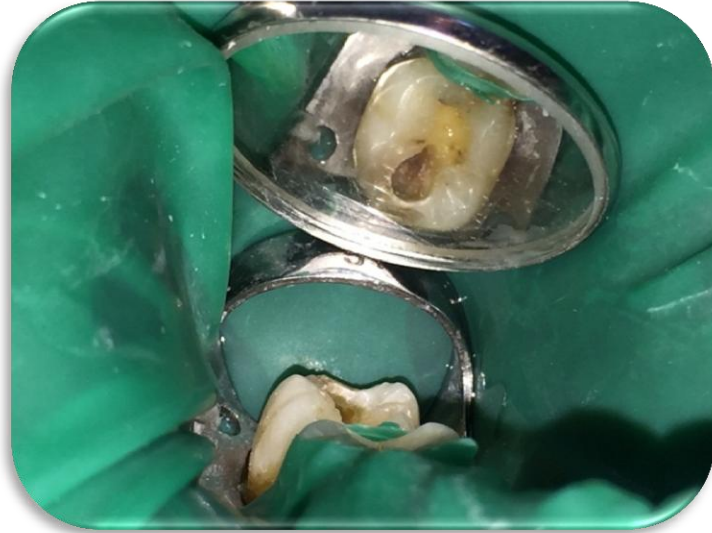
Phase four therapy

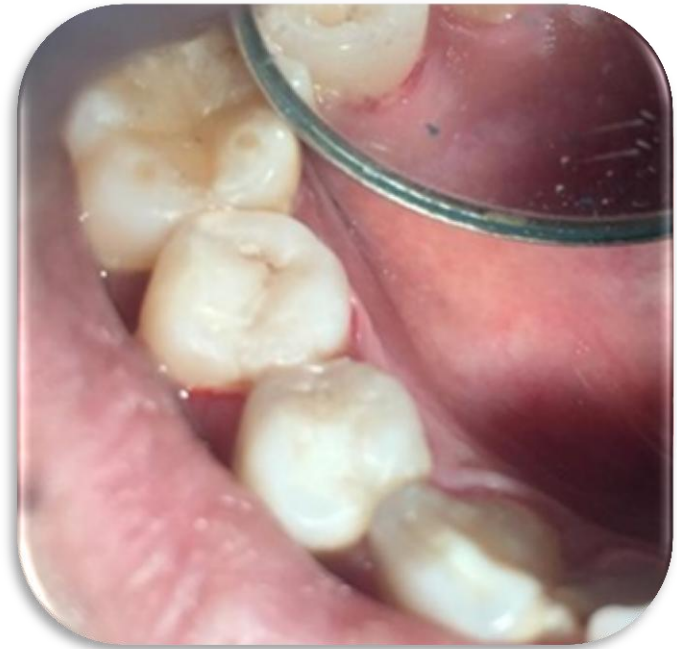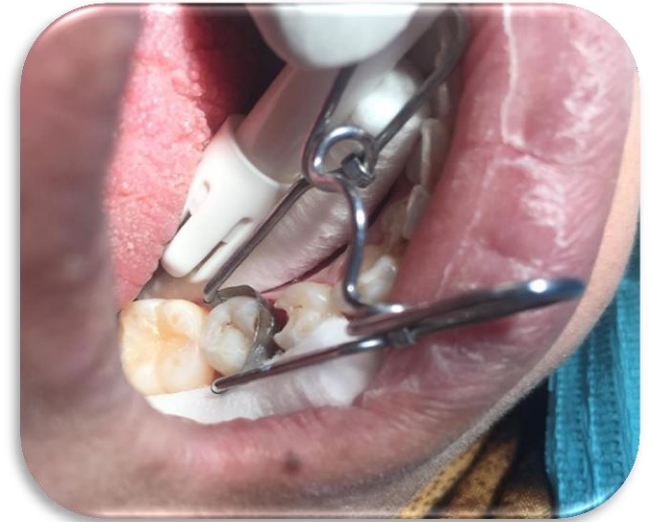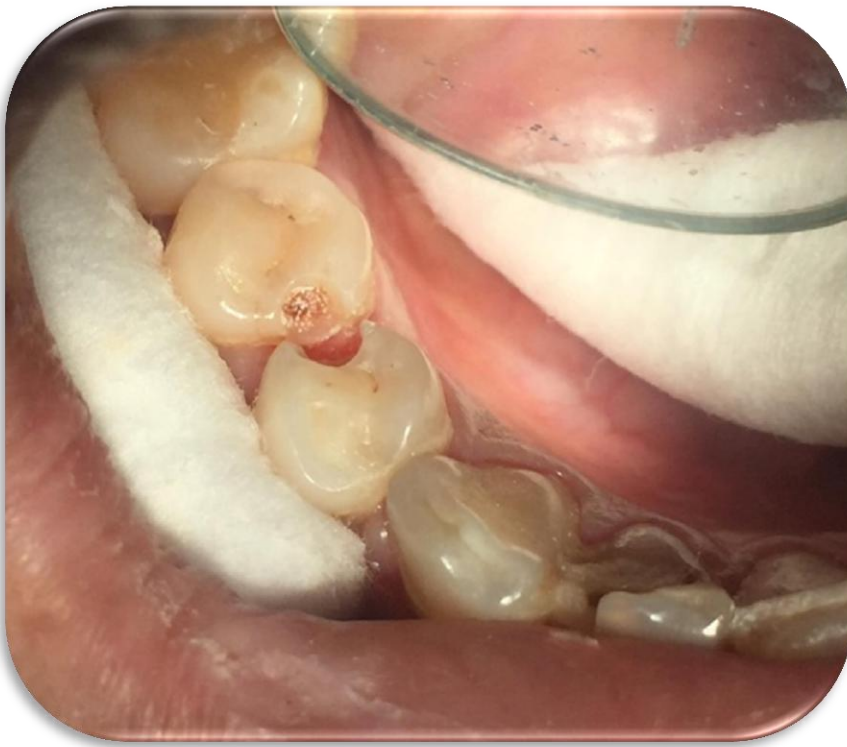Restoration Lower Right 1ST Molar



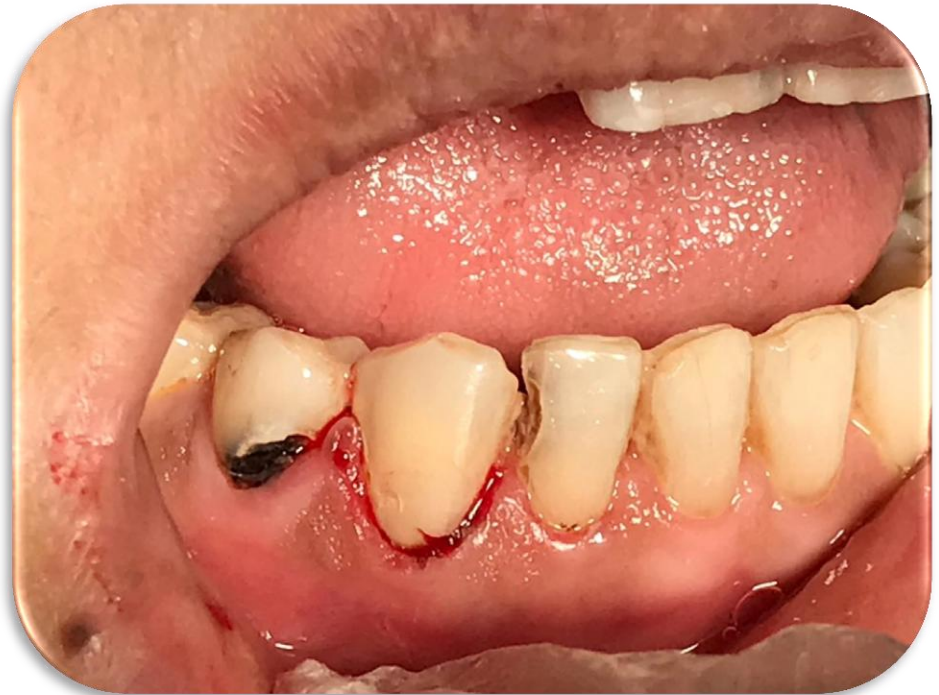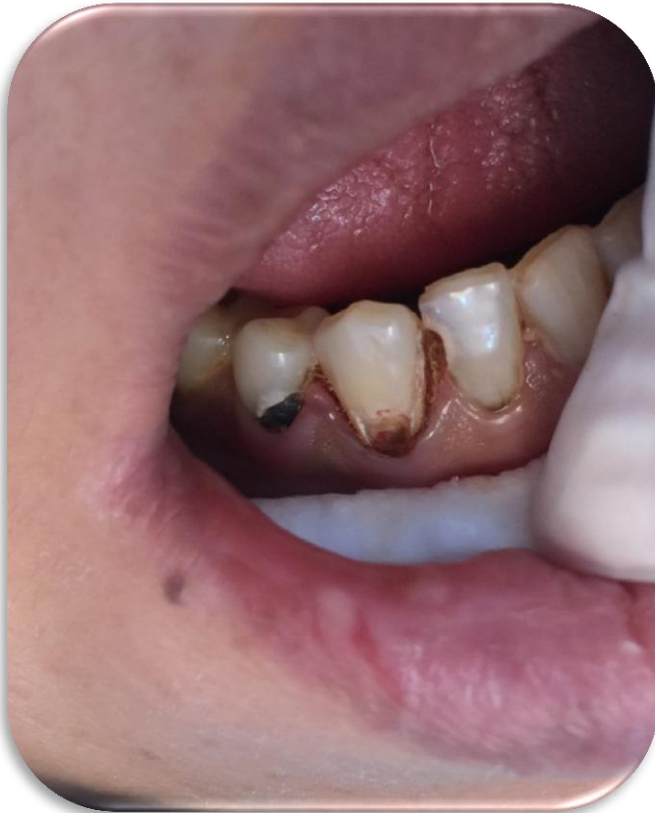Restoration Lower Right 2nd Molar



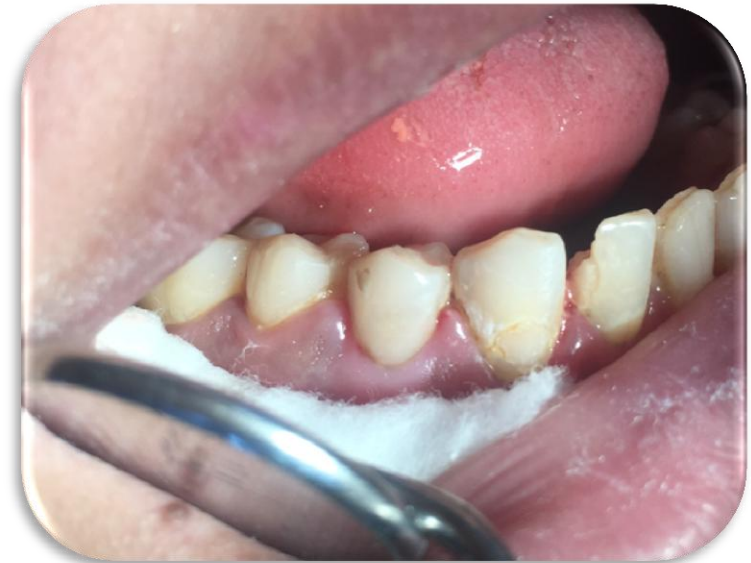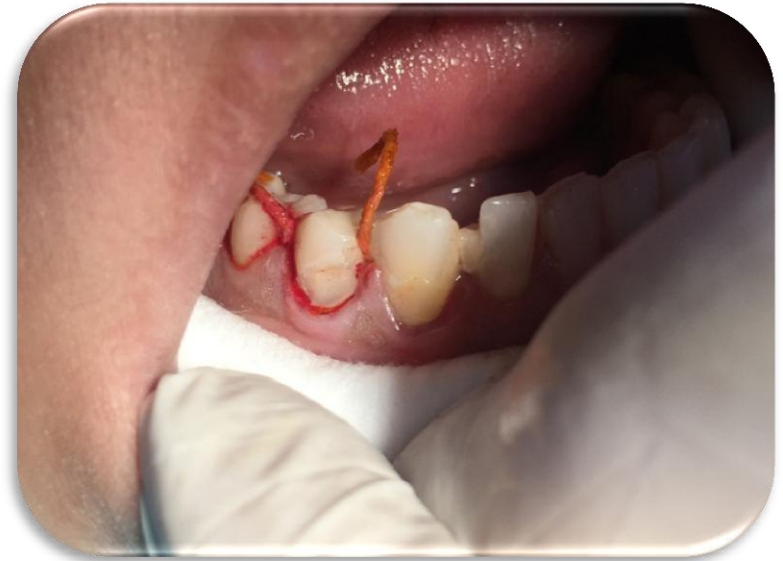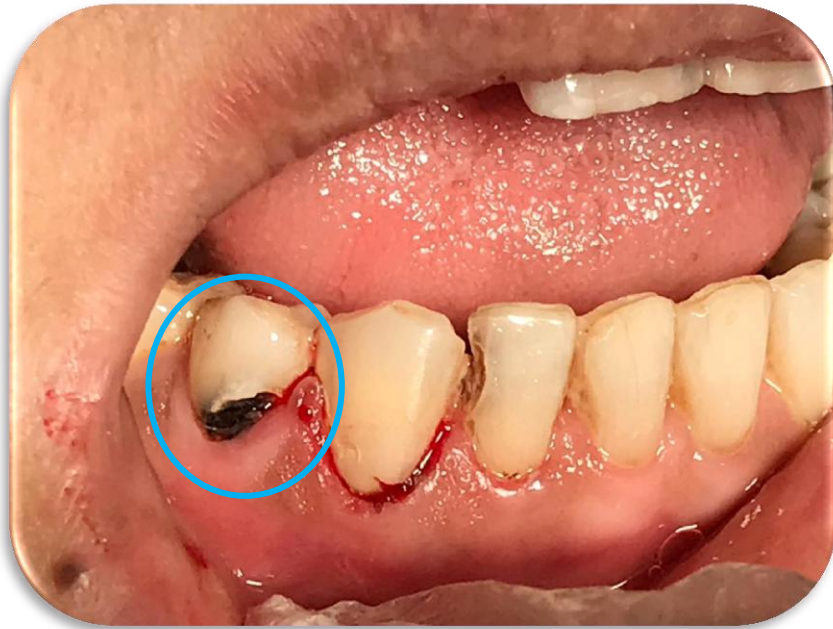
Restoration Lower Right 1st , 2nd premolar



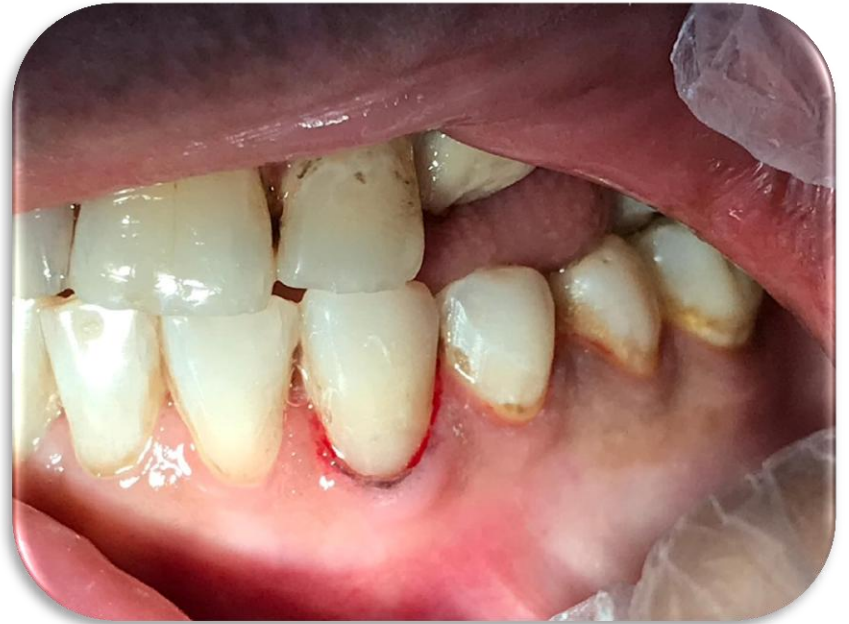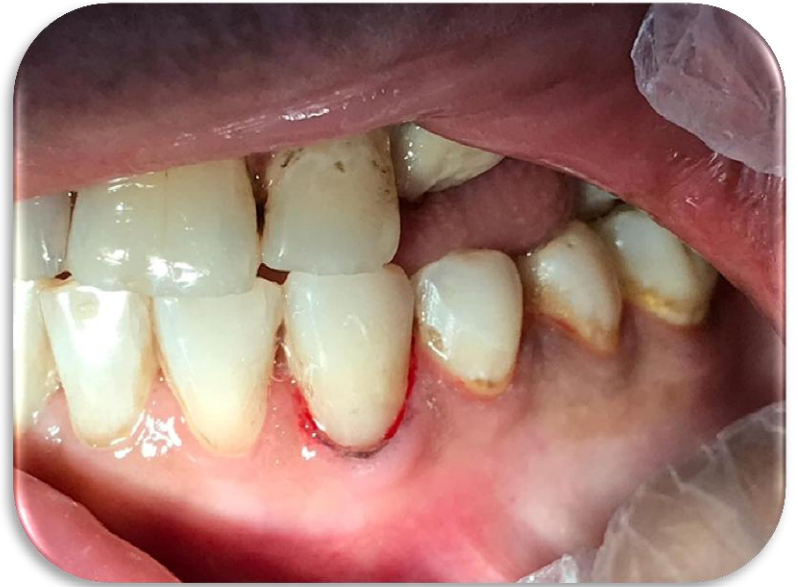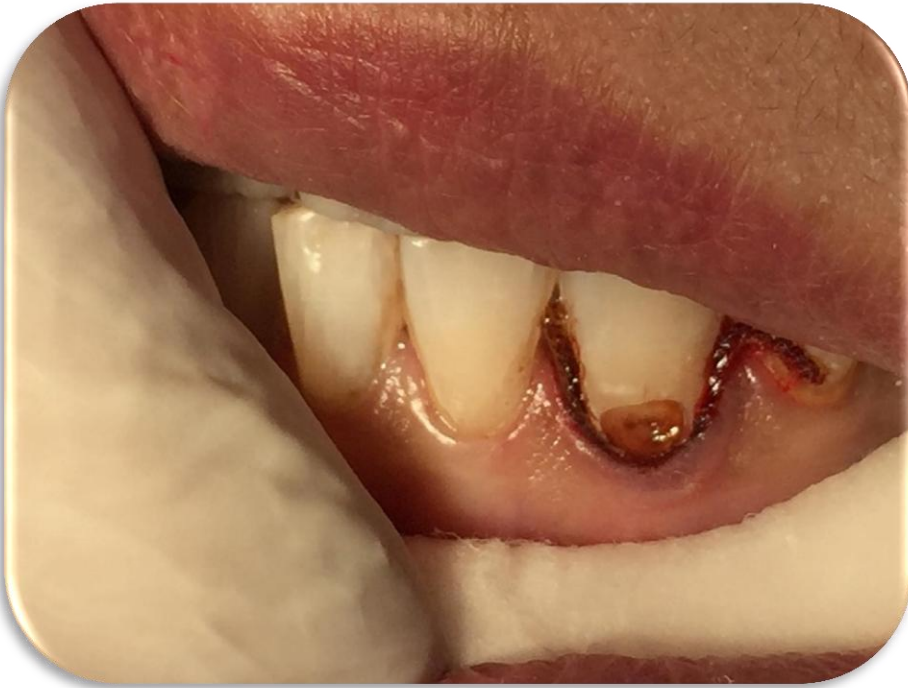Restoration Lower Right Canine



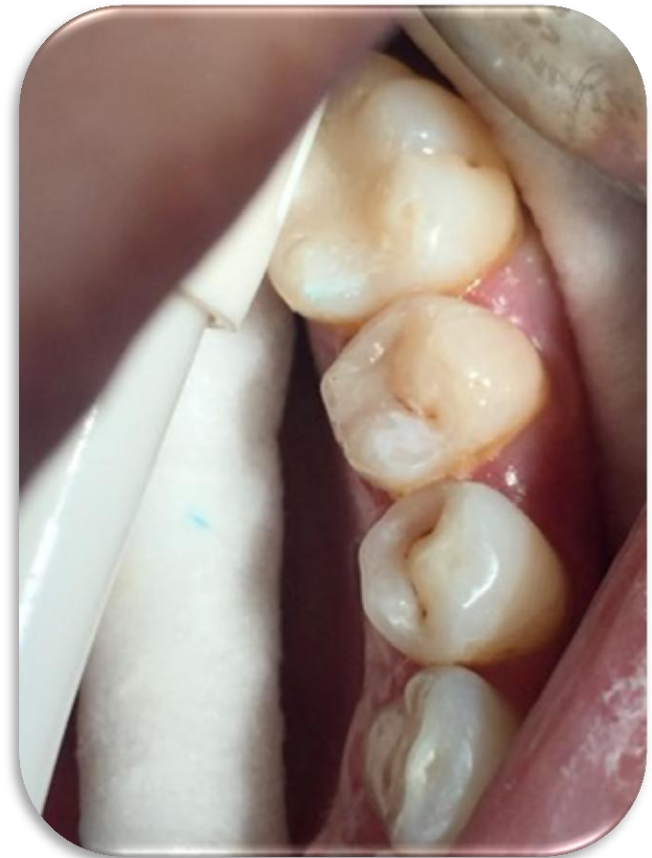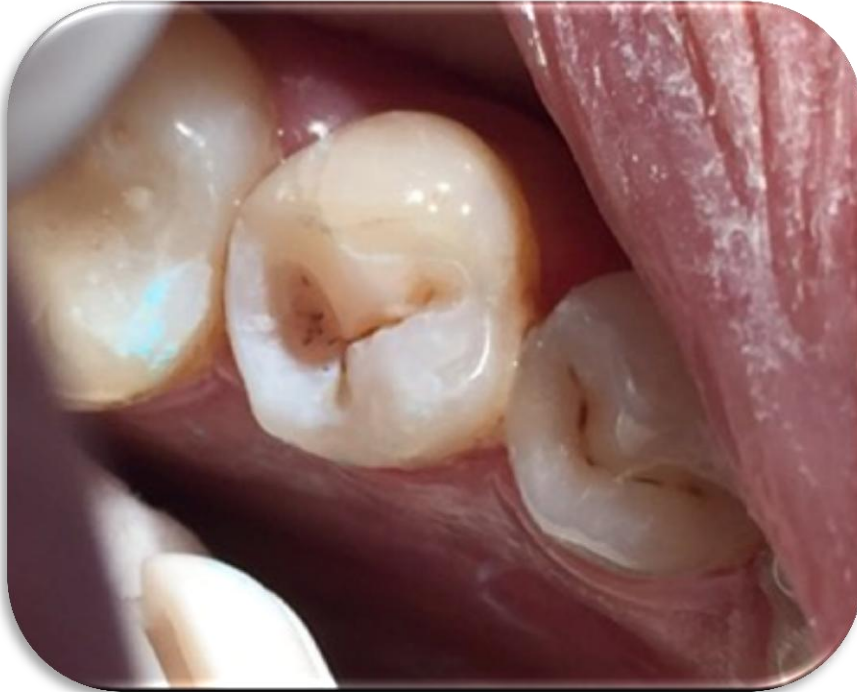Restoration Lower Right 1st premolar



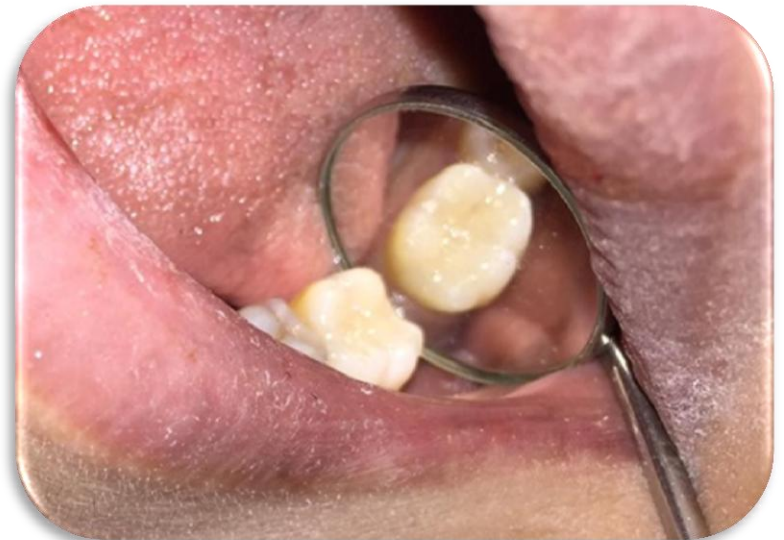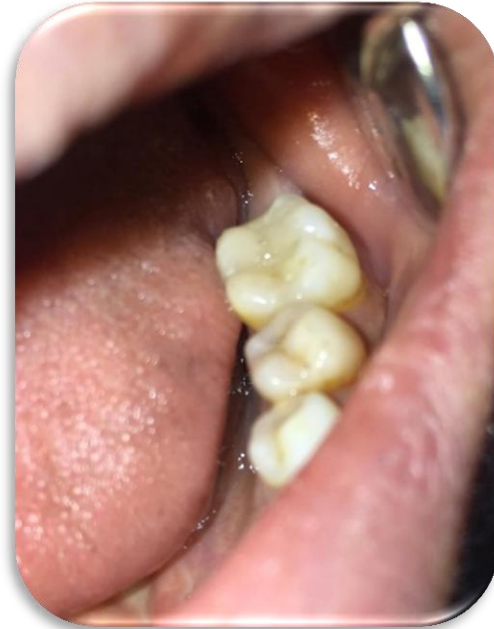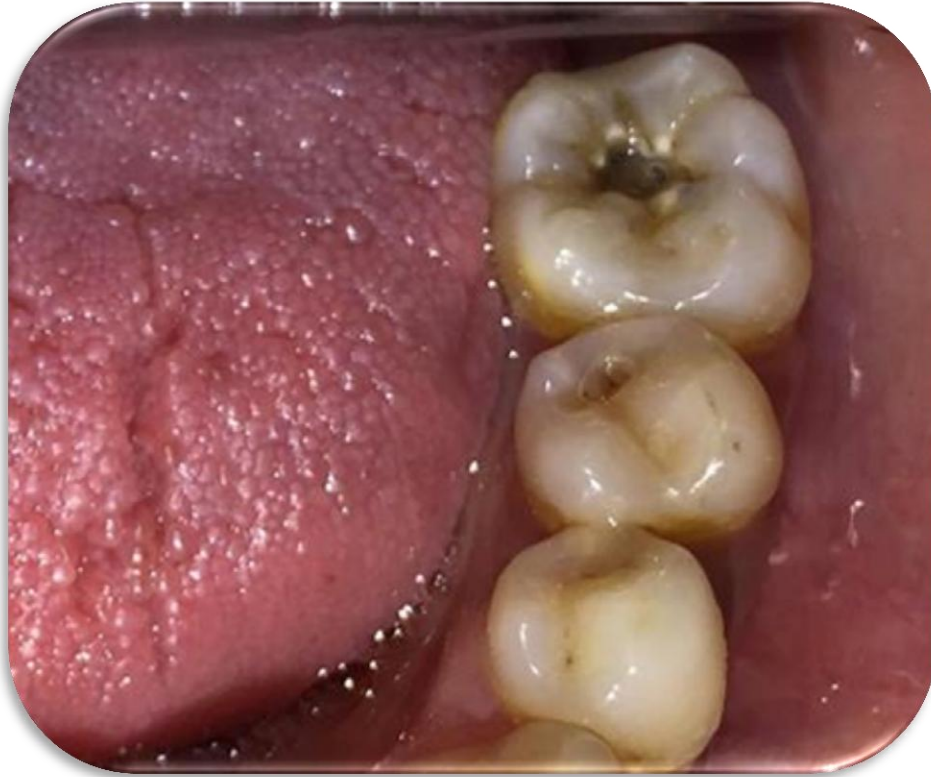Restoration Lower Left Canine



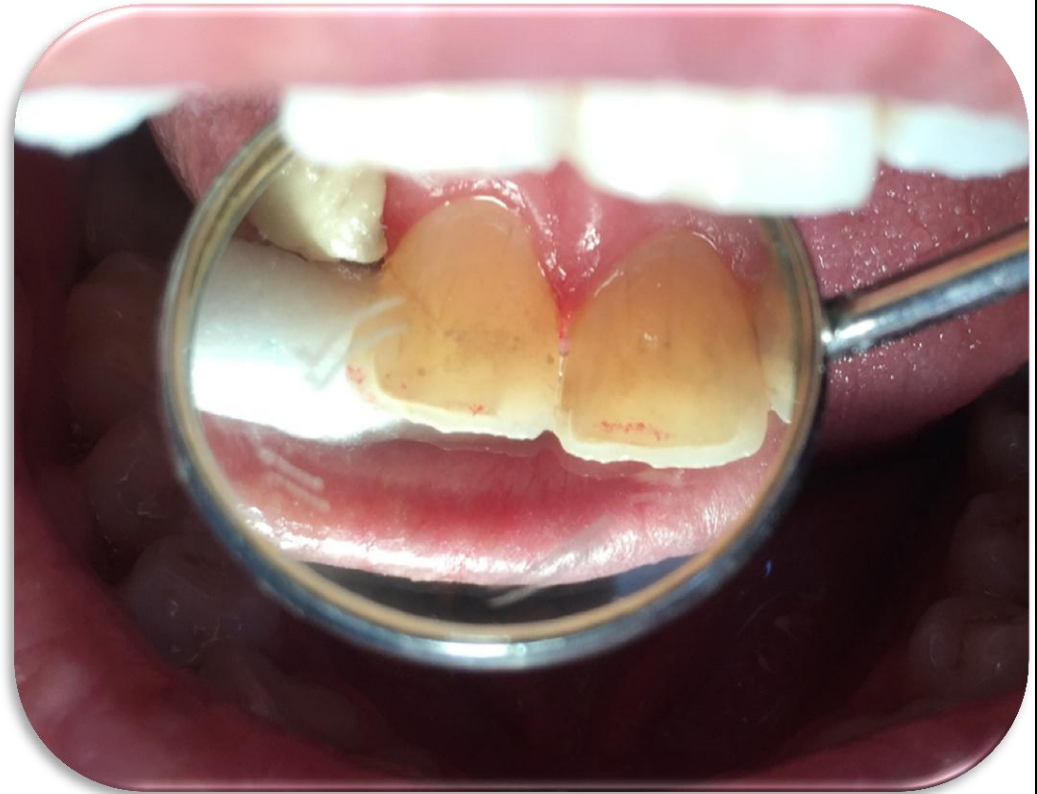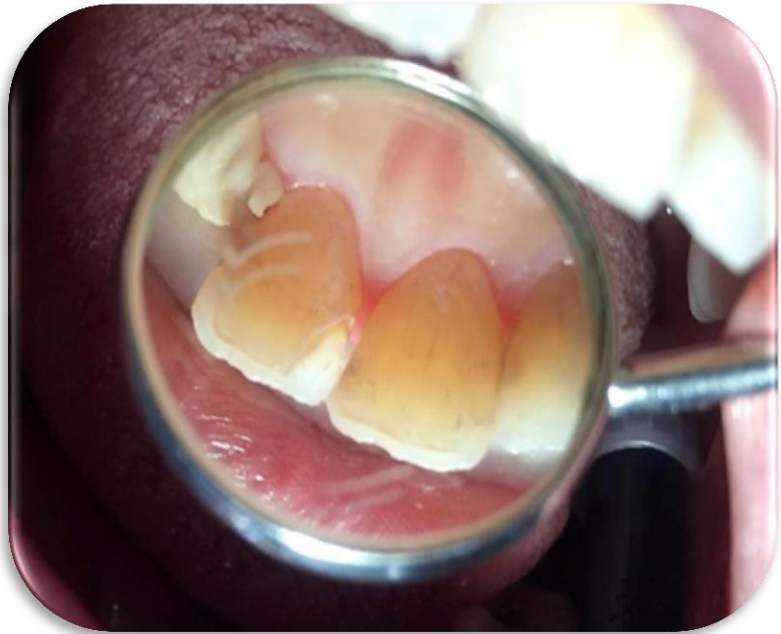Restoration Lower Left 2nd premolar



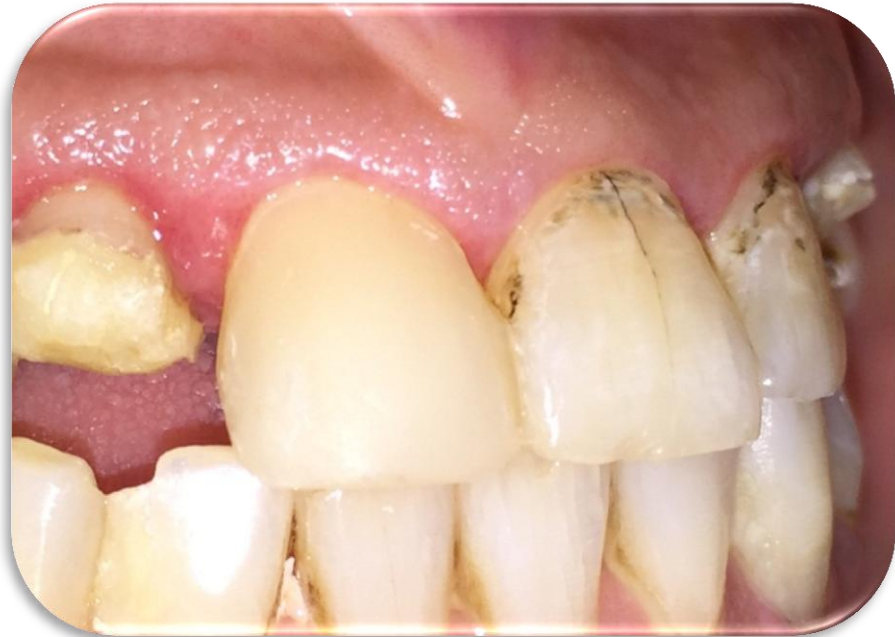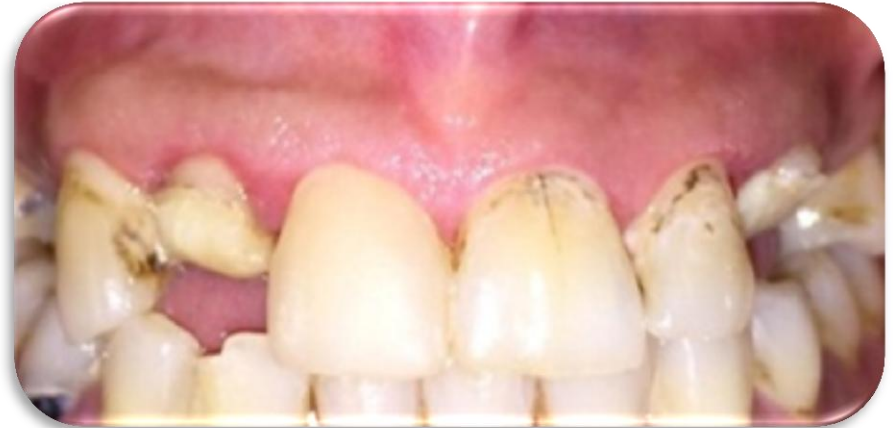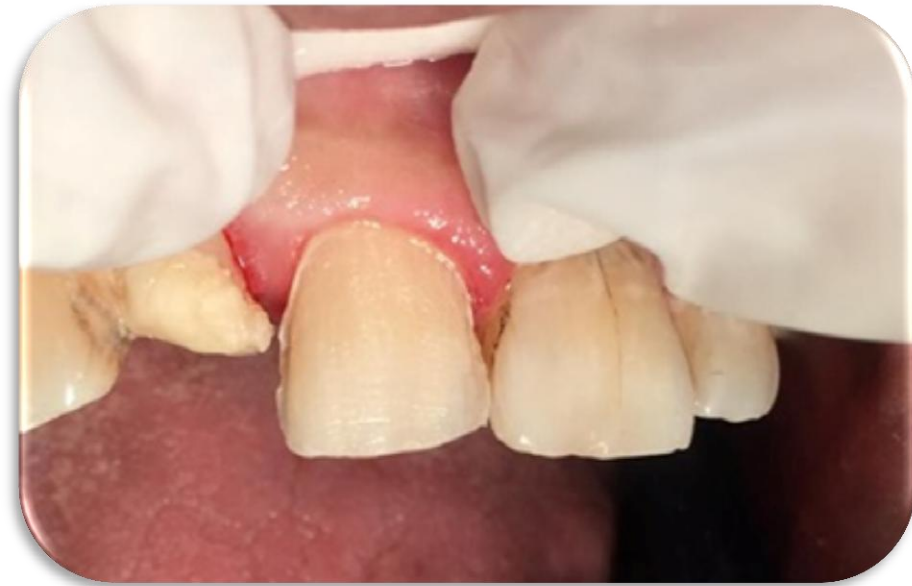Restoration Lower Left 1st Molar



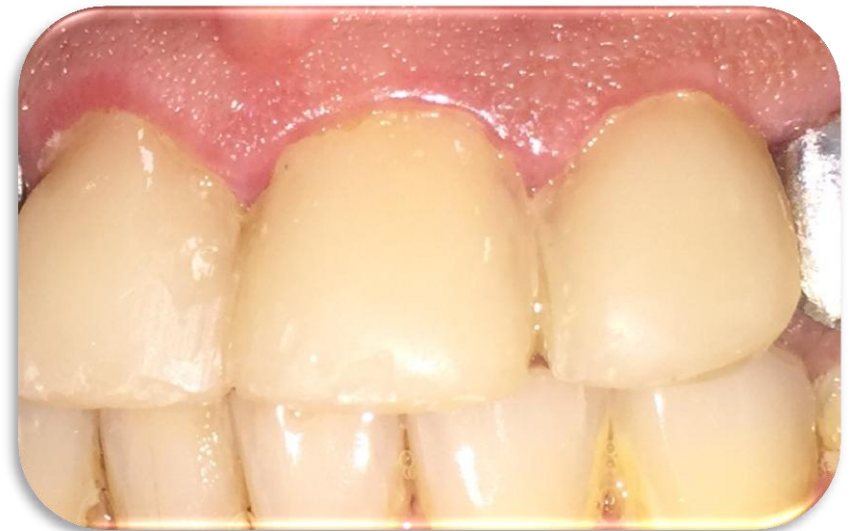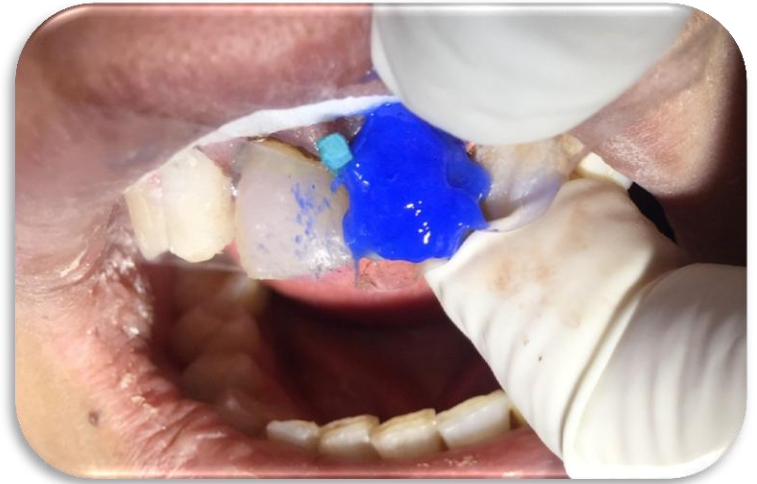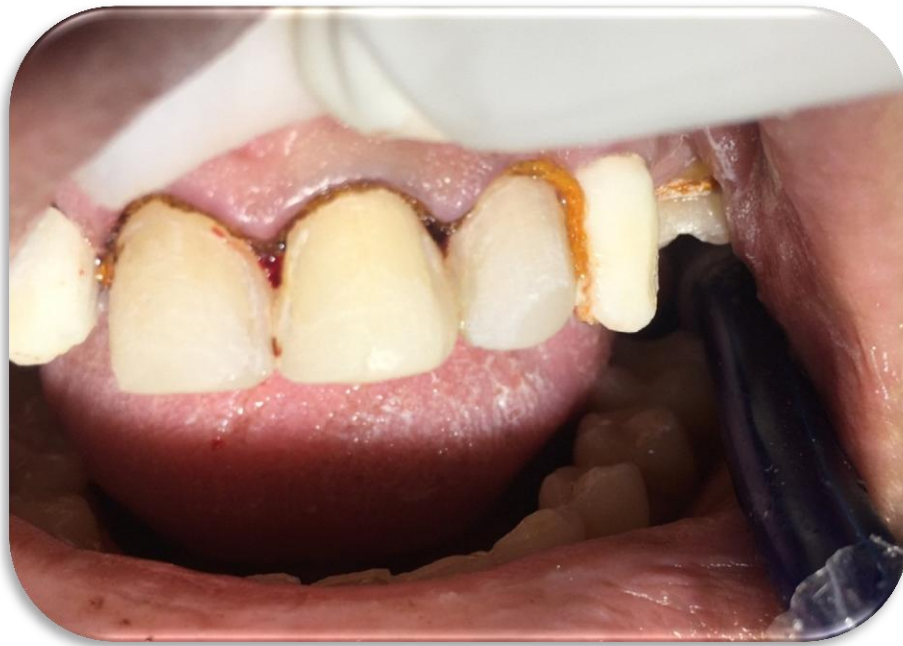Restoration Upper Right Central Incisor



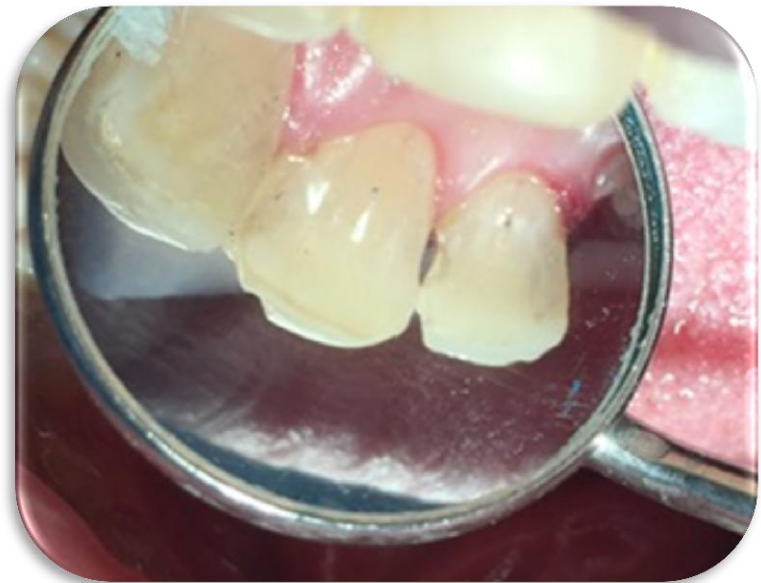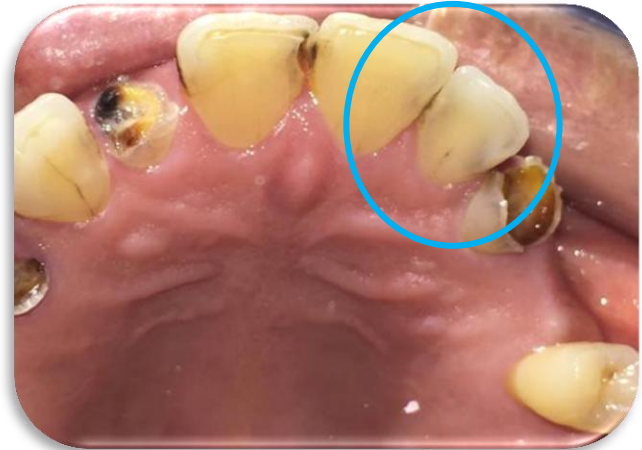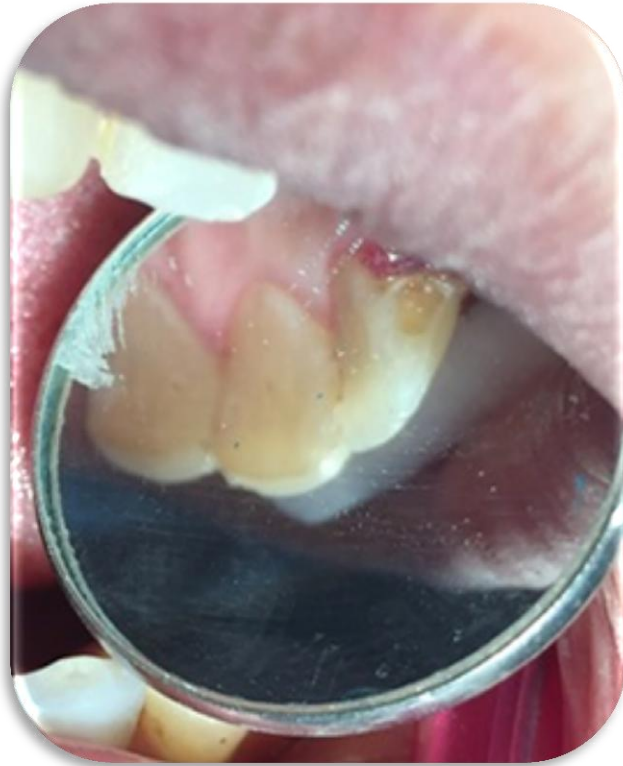Composite Veneer For Upper Right Central Incisor



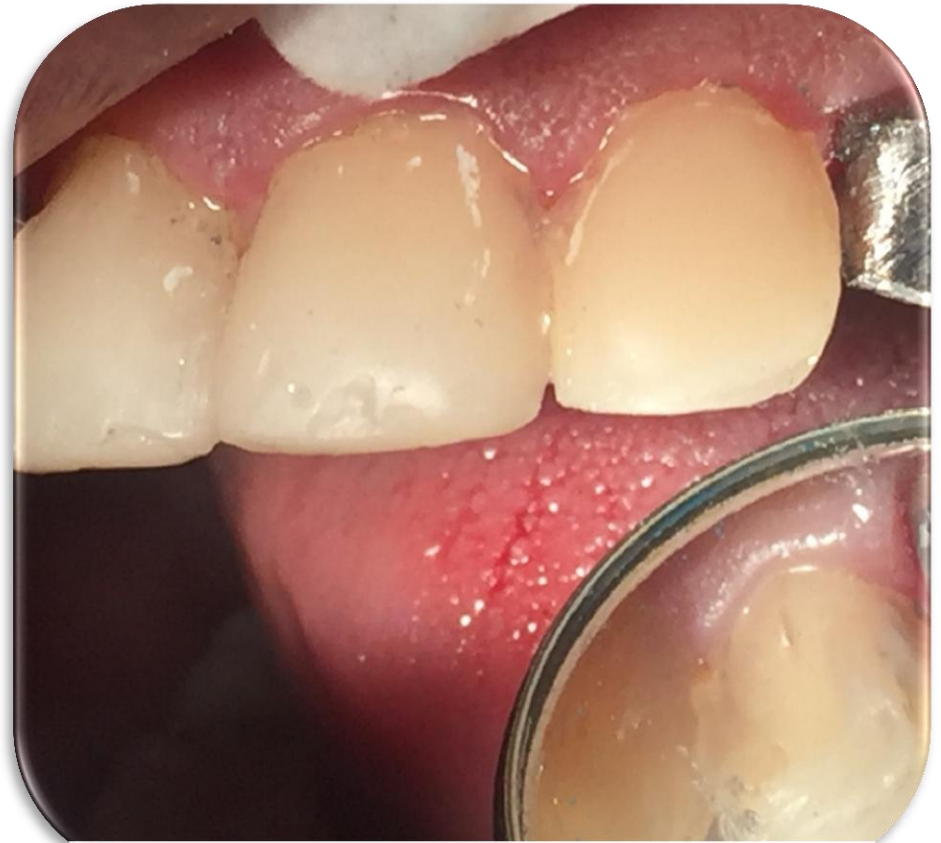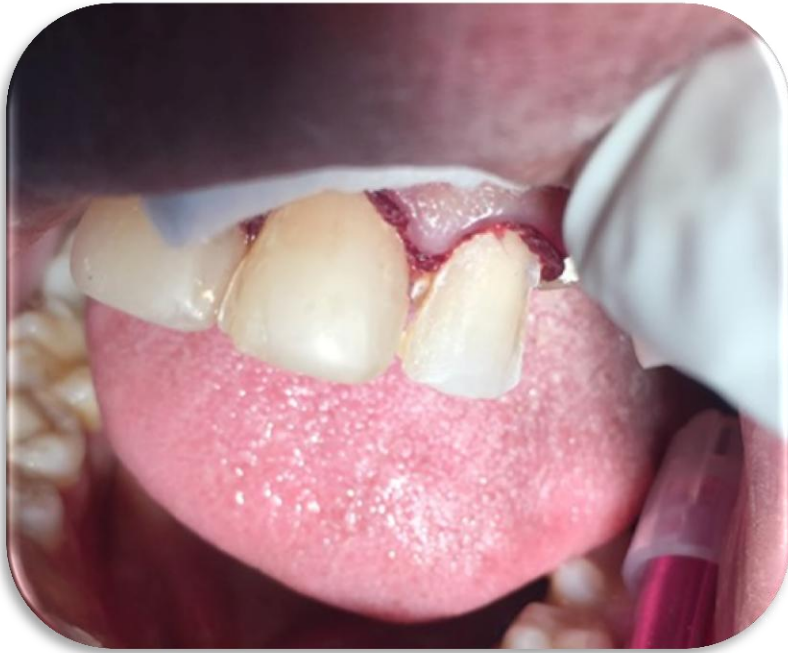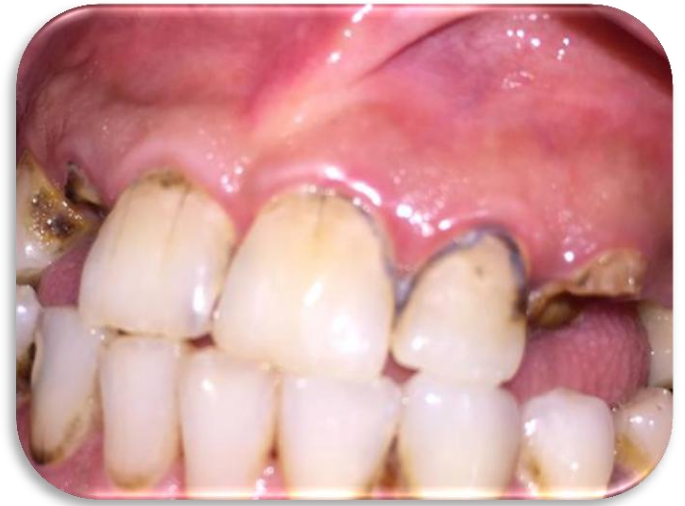Composite veneer For Upper Left Central Incisor



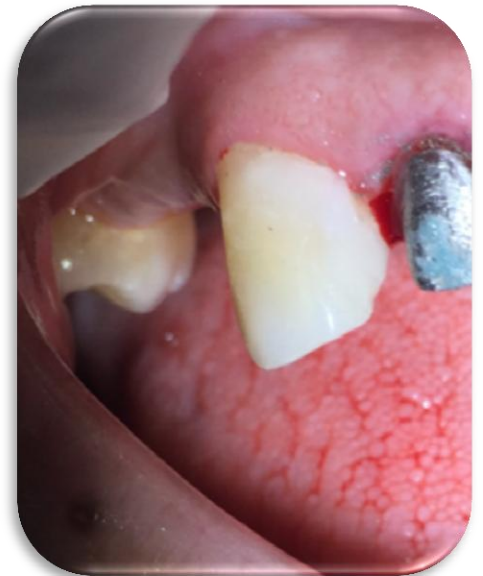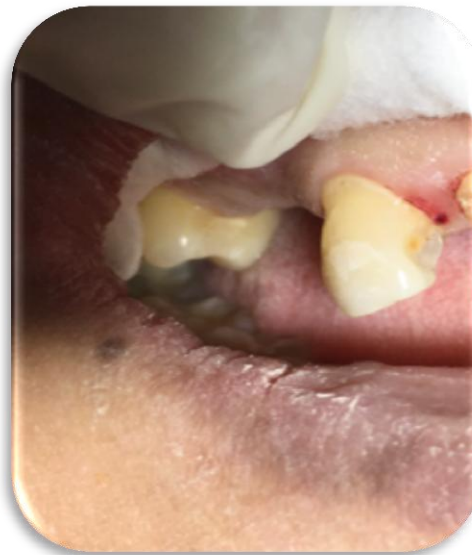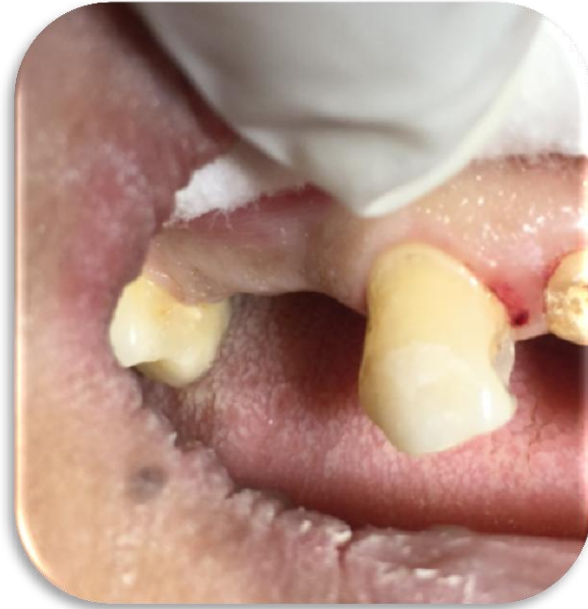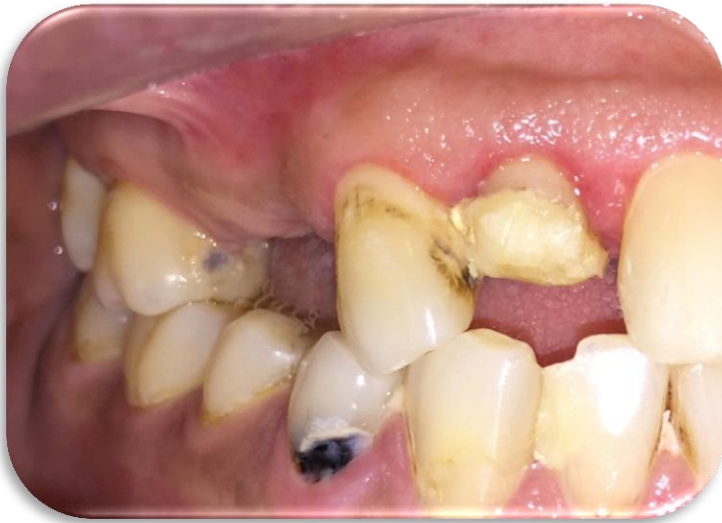Restoration Upper Left Lateral Incisor



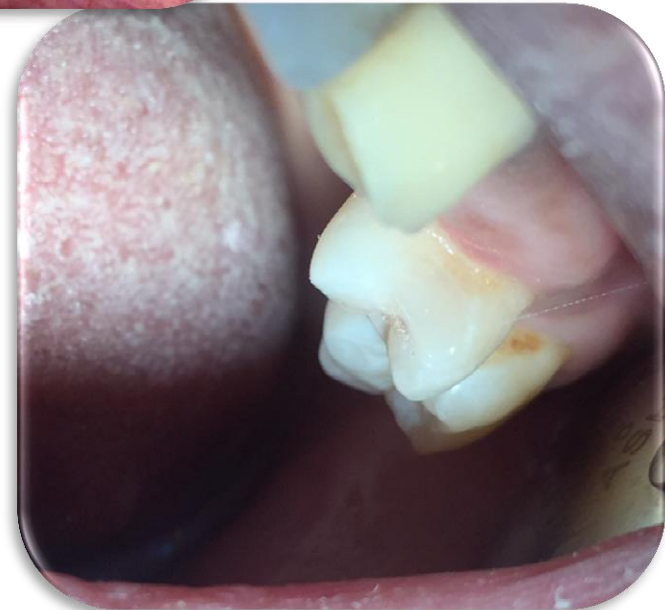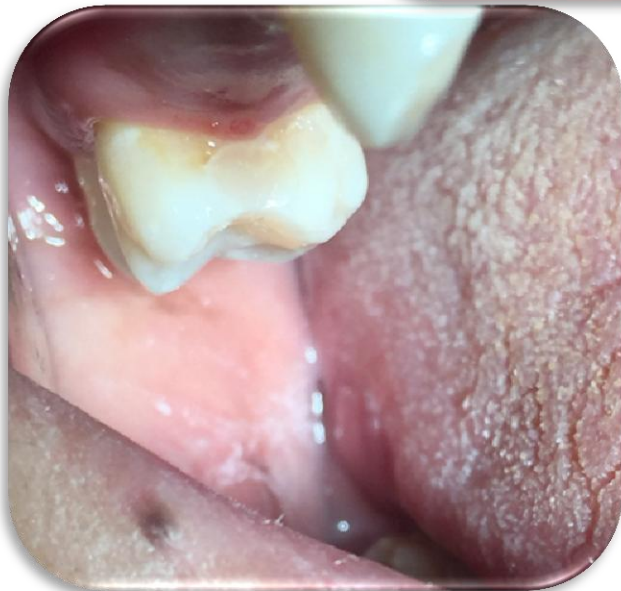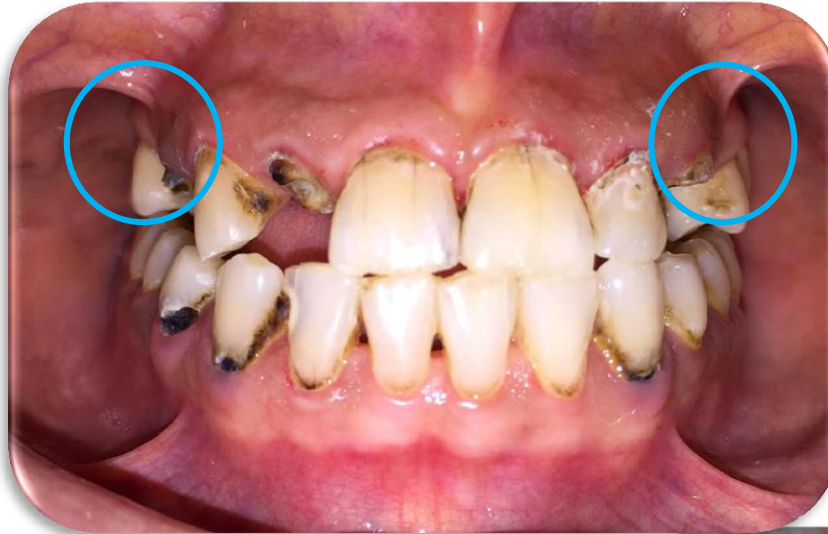Composite Veneer Upper left Lateral Incisor



Restoration Upper Right Canine



Restoration Upper Right 6 And Upper Left 5 class II



Fixed

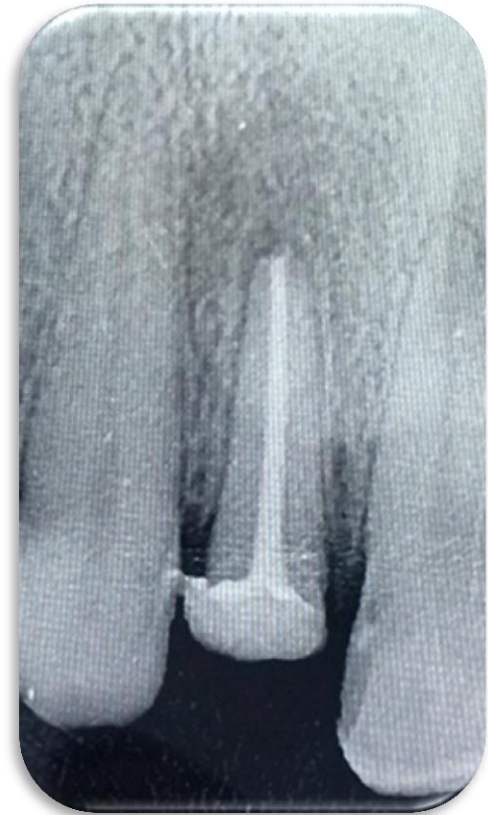```
graph TD; Fixed[Fixed] --- Custom[Custom made post for 2 | 3]; Fixed --- Ready[Ready made post for 2 |]; Custom --- Ready;
```

Custom
made
post for 2 | 3

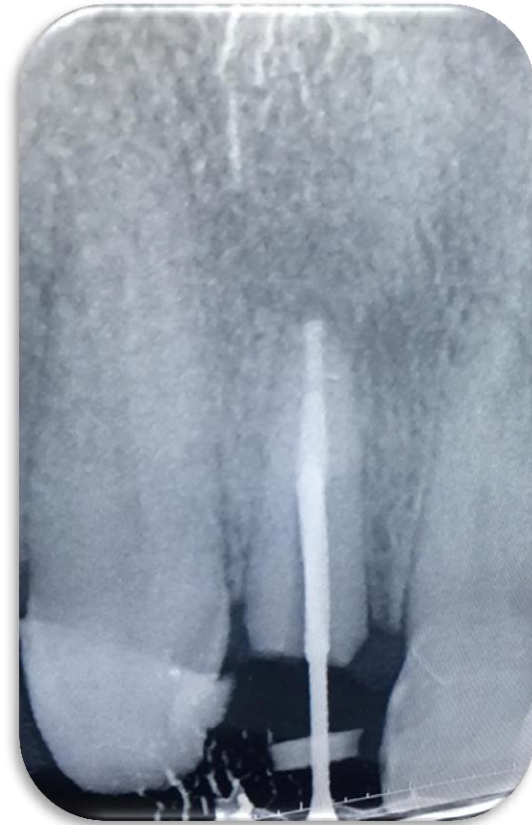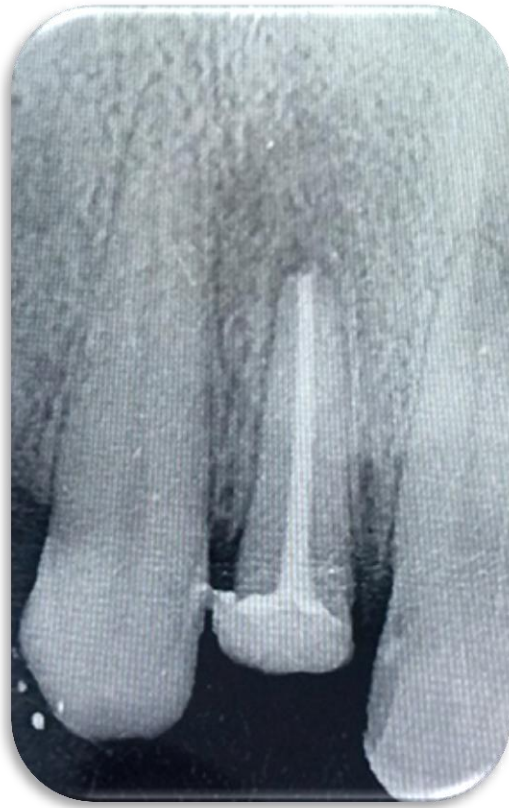Ready made
post for 2 |

**Post preparation for
upper right lateral
incisor**

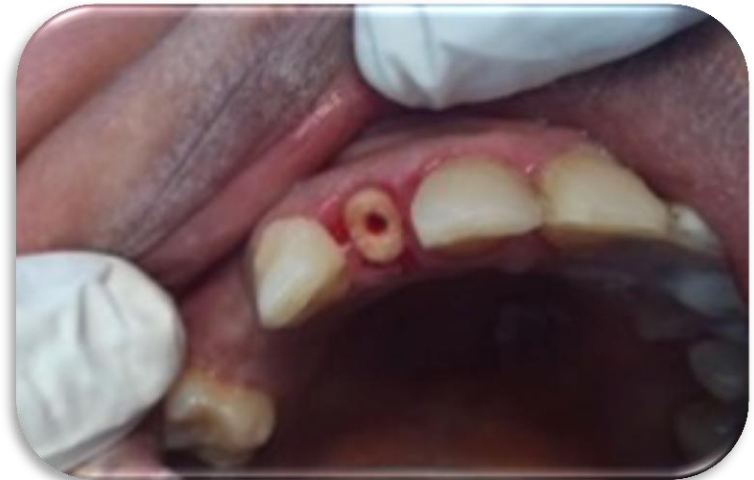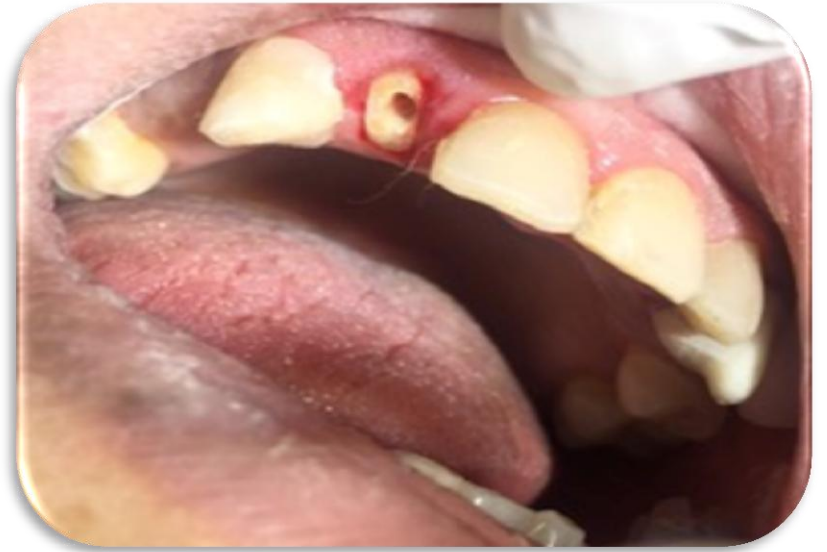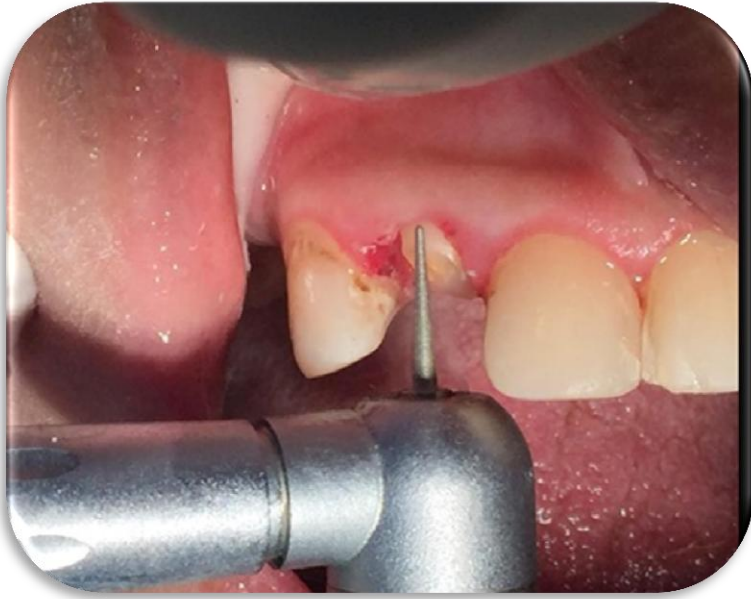After 2 month



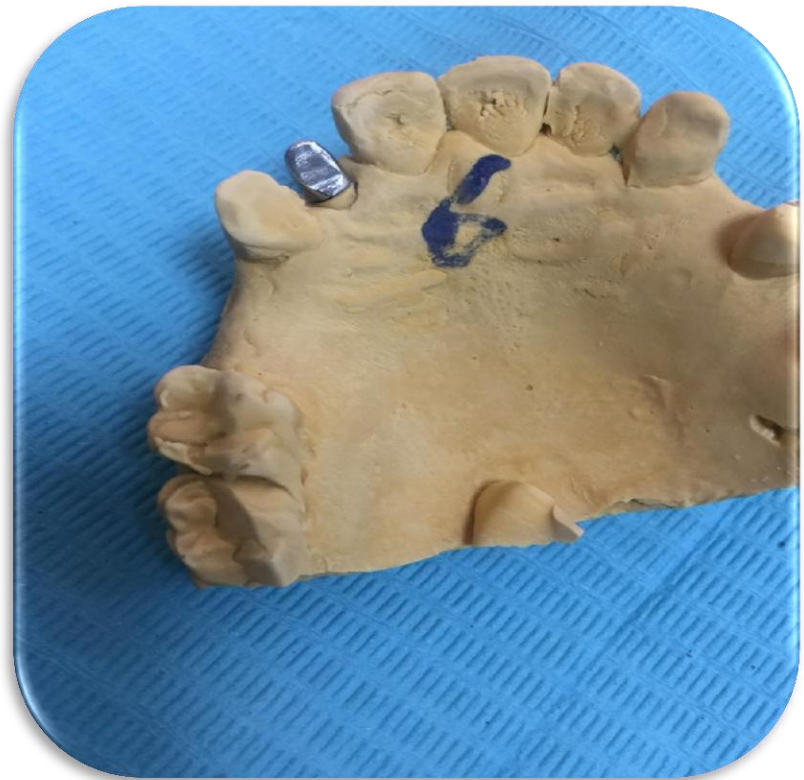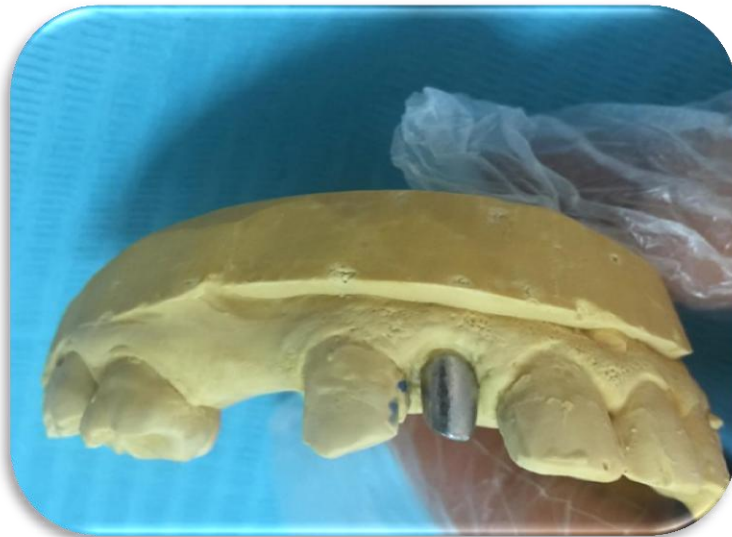
Post preparation For Upper Right Lateral Incisor



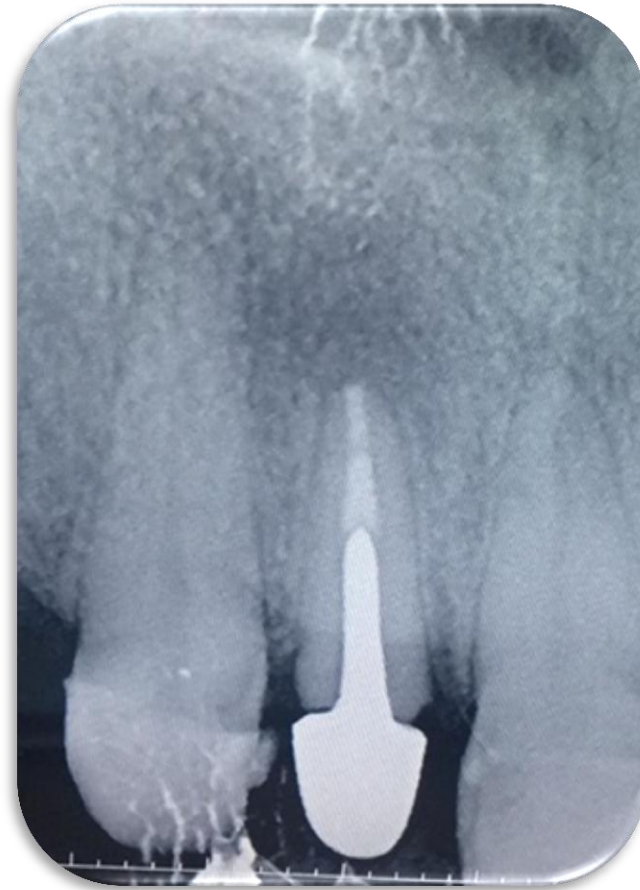
Coronal preparation



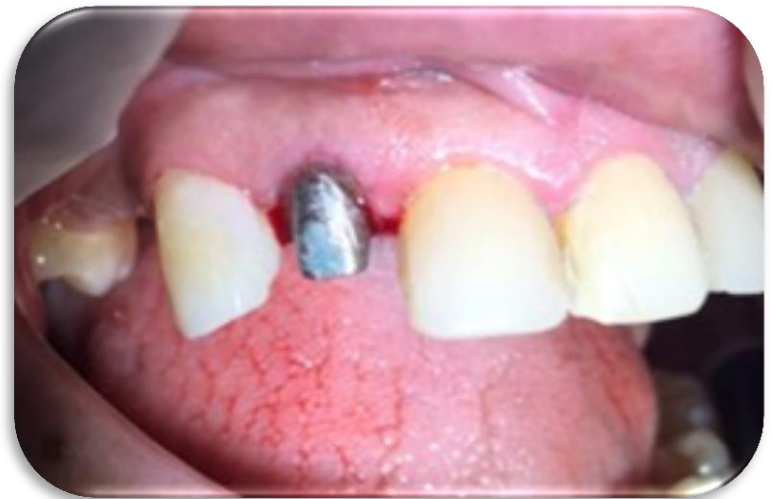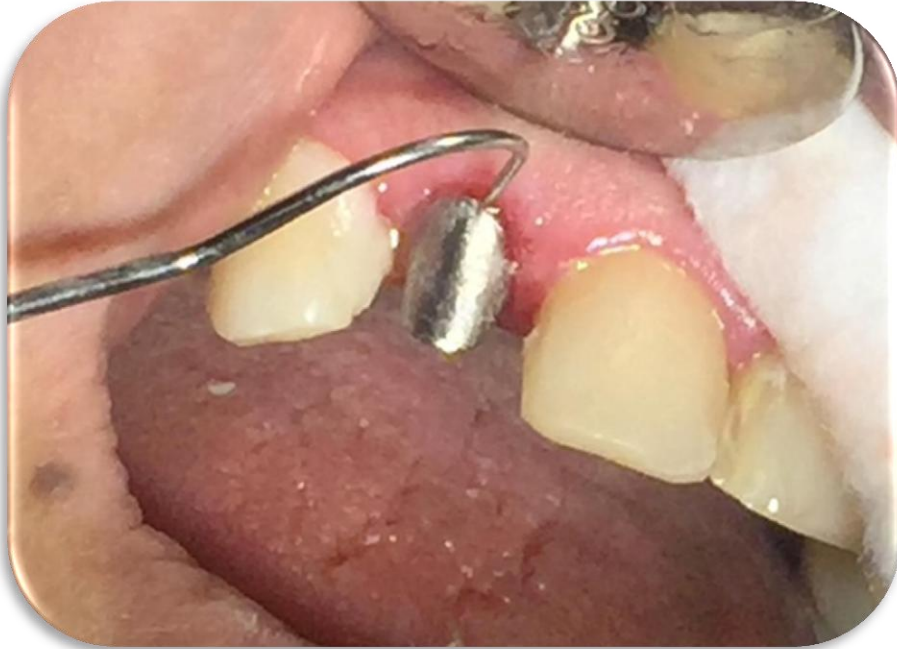
Custom-Made Post For Lateral Incisor

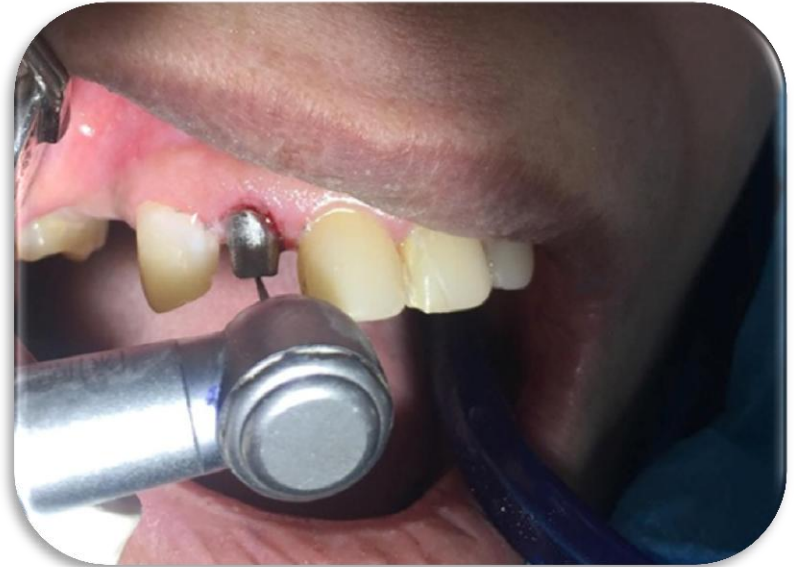
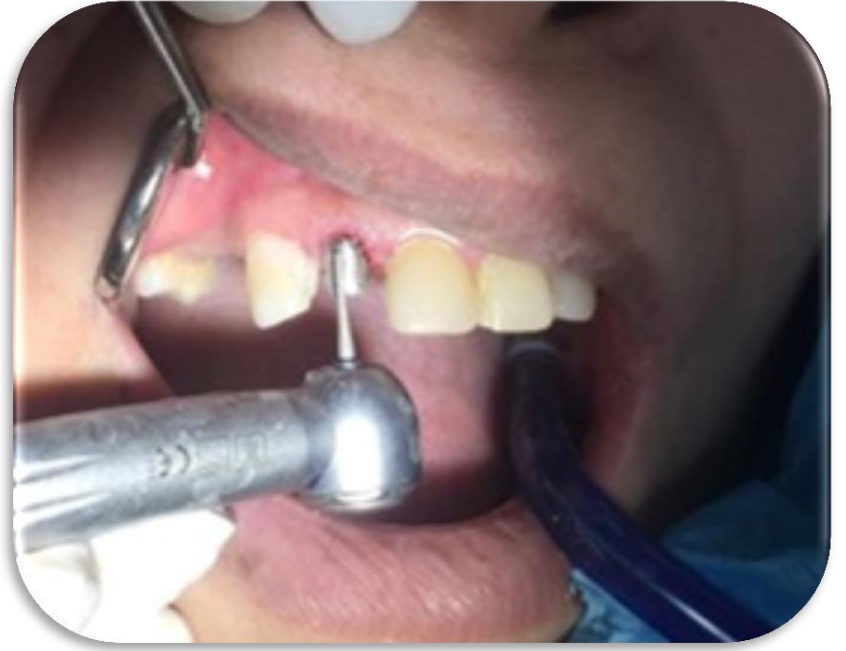
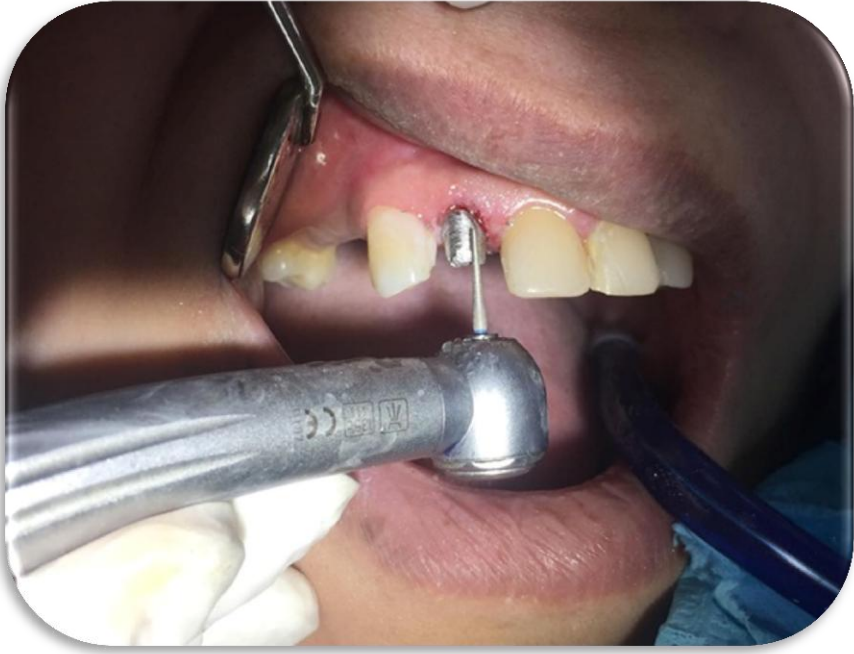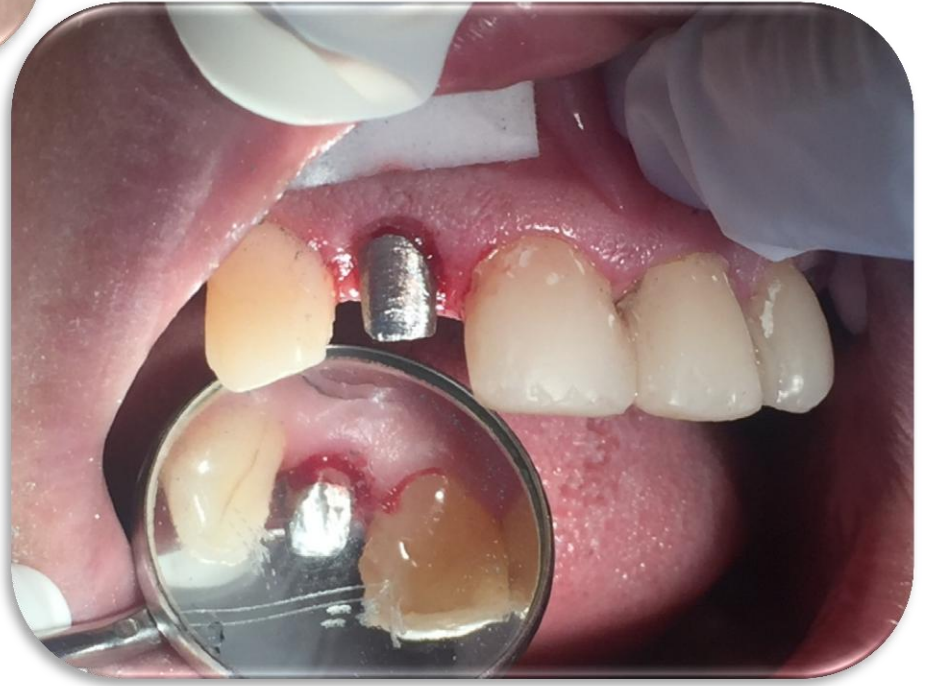
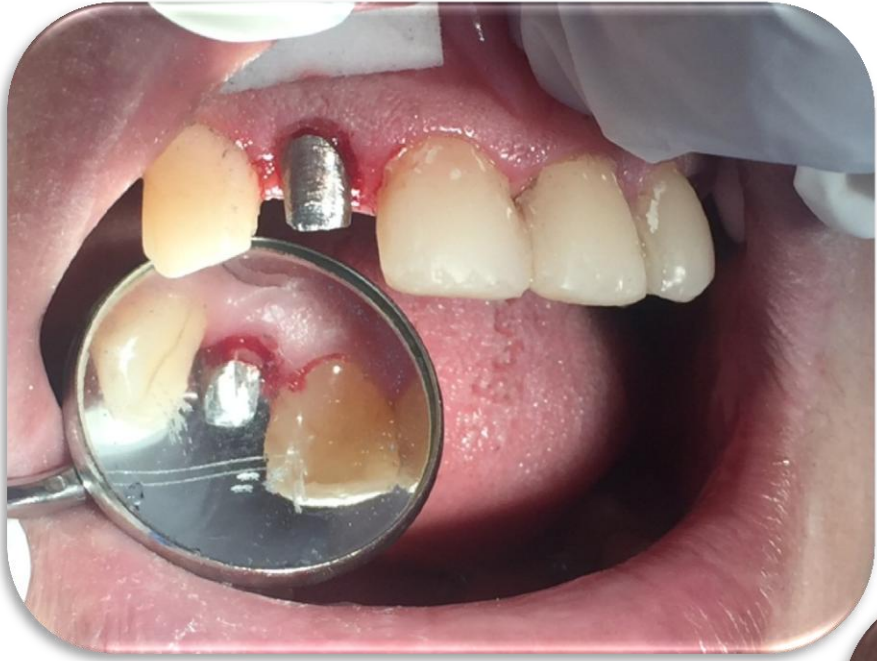X-Ray For Custom Made Post



Cementation For Custom-Made post

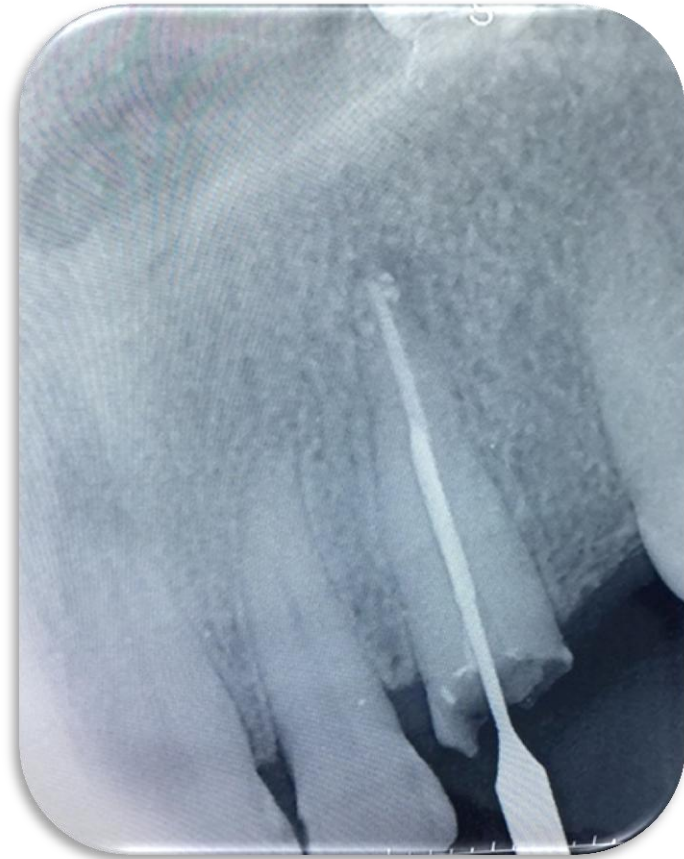
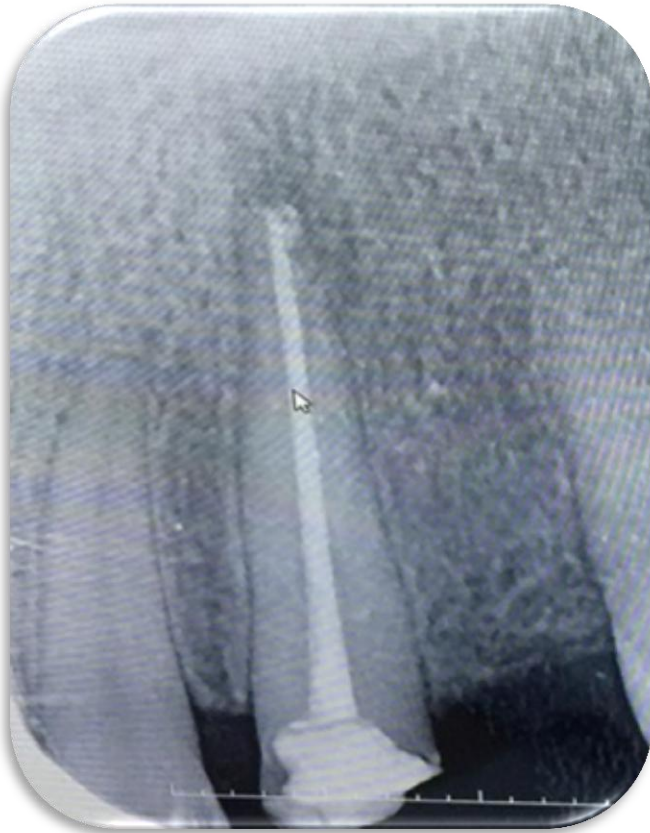




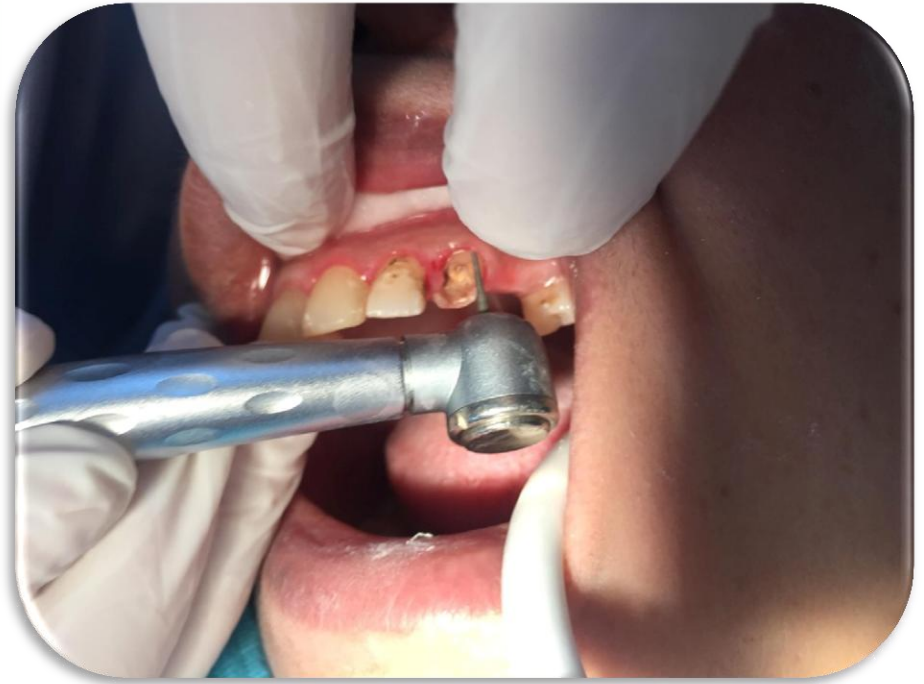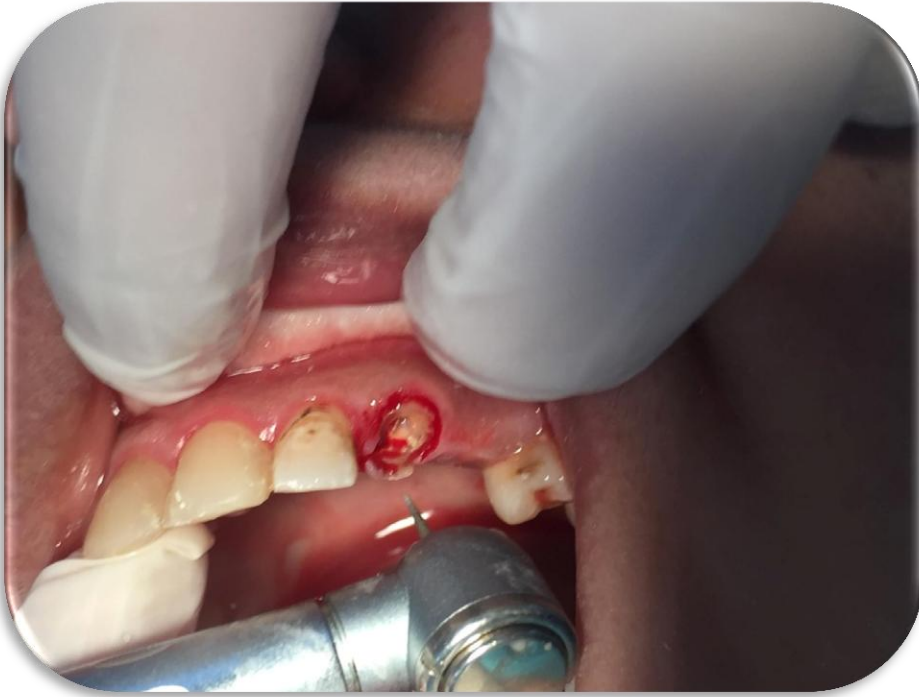preparation For Upper Left Canine

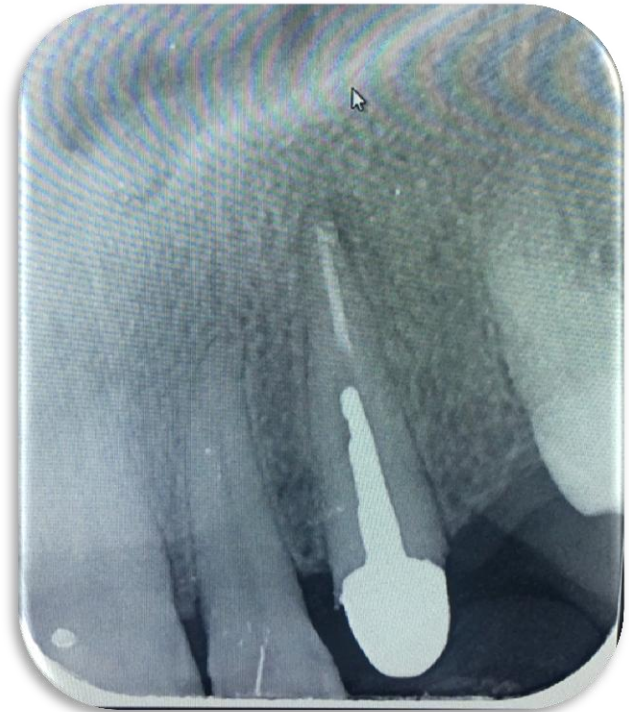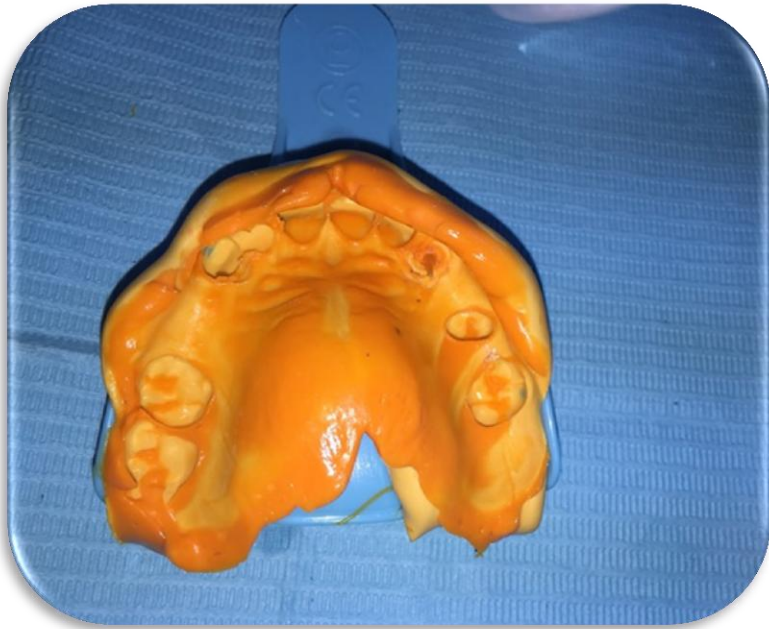Post preparation For Upper Left Canine



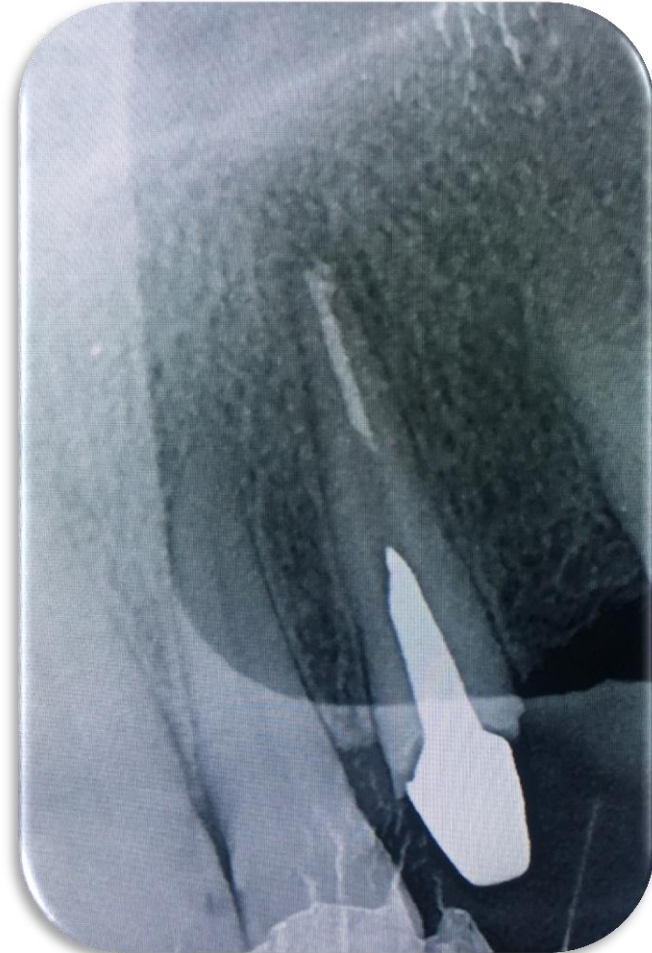
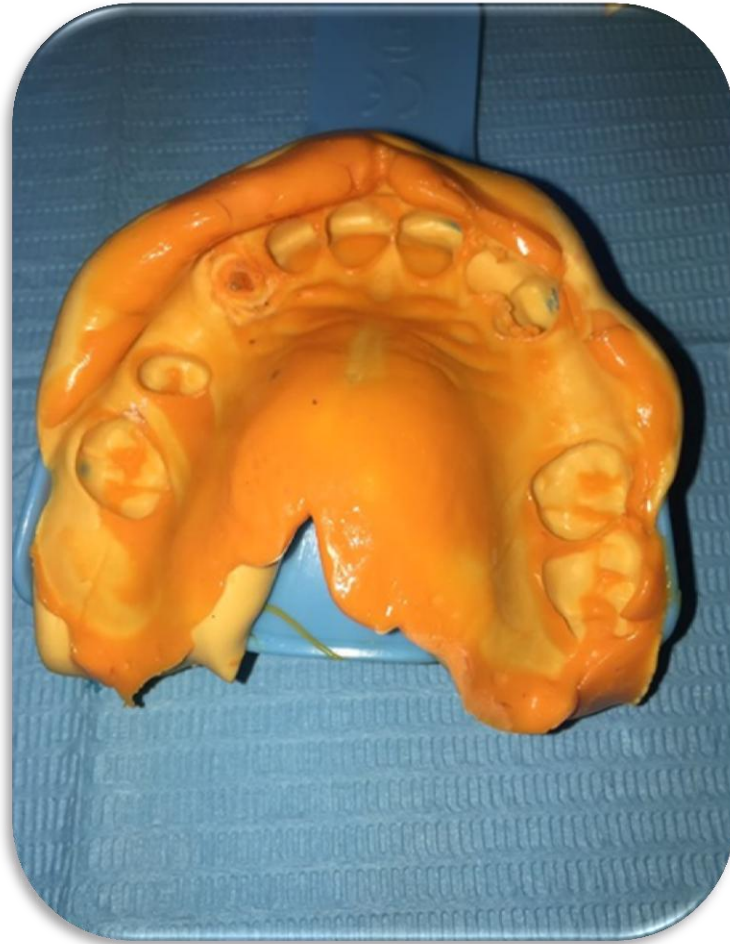Coronal Preparation



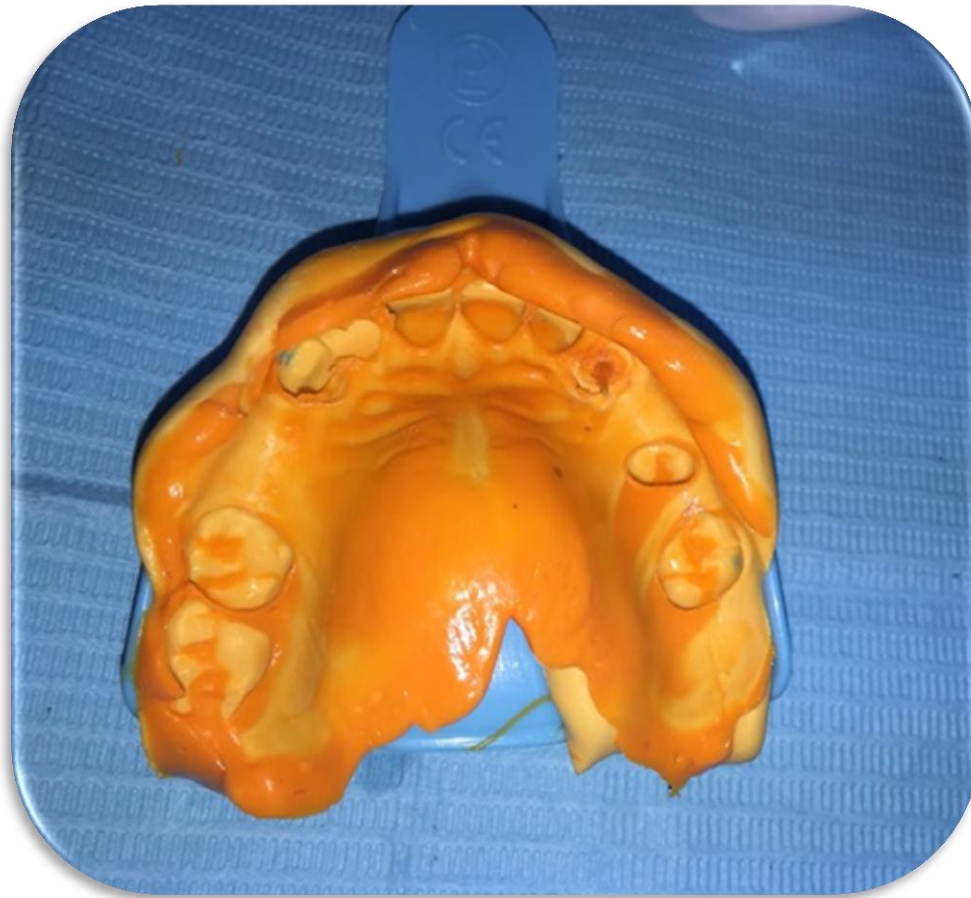Impression For Post



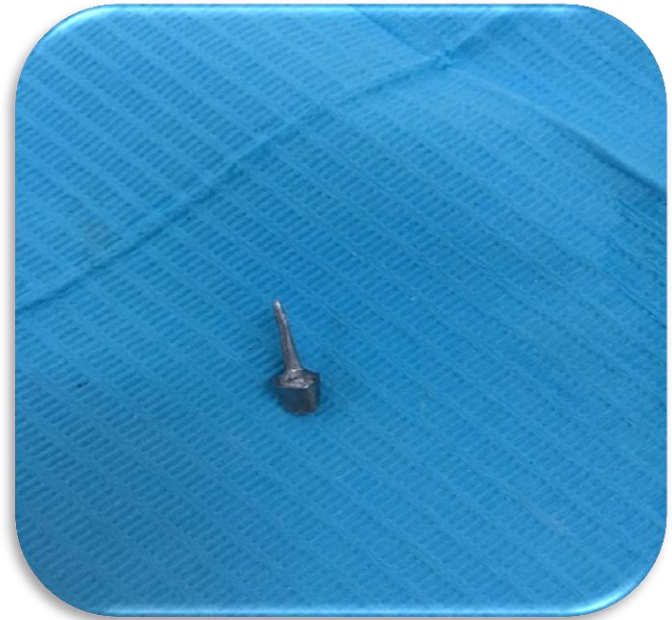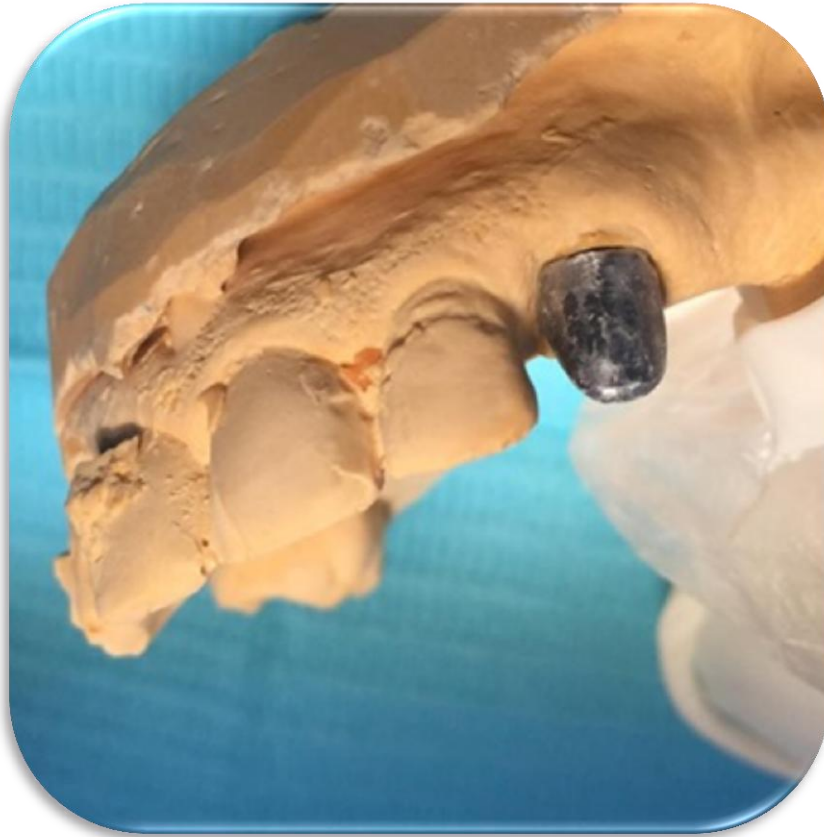Re_impression For Post



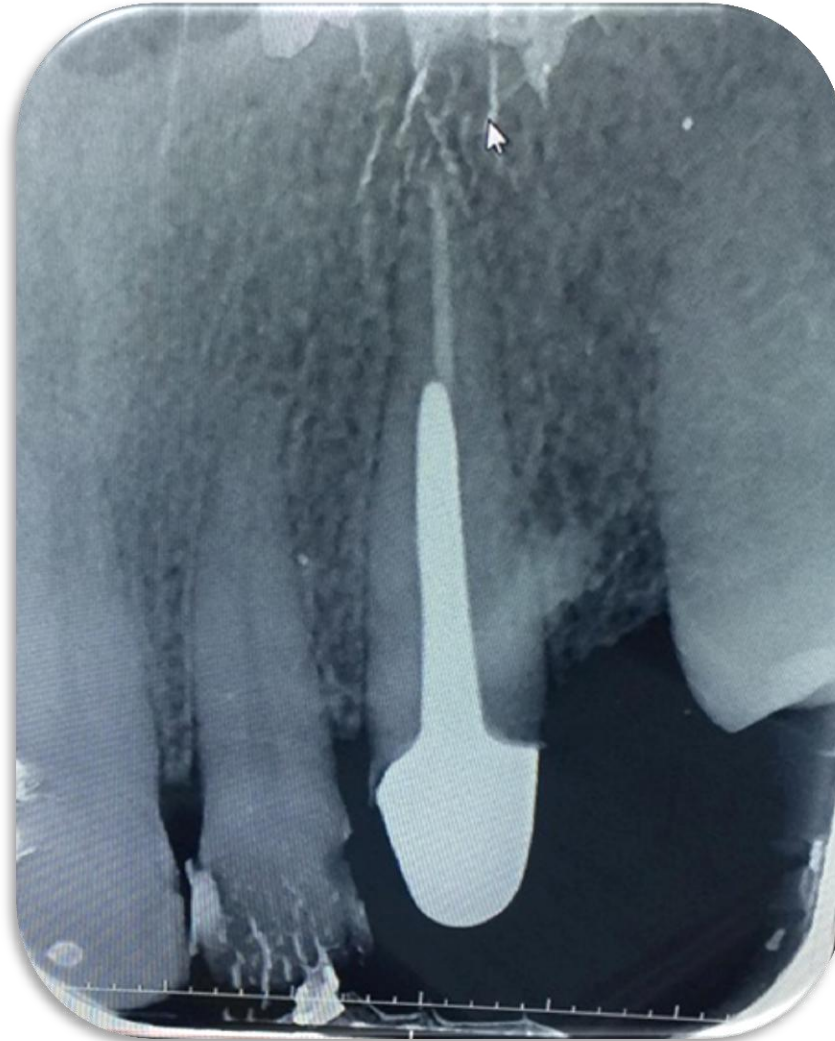
Fainal impression



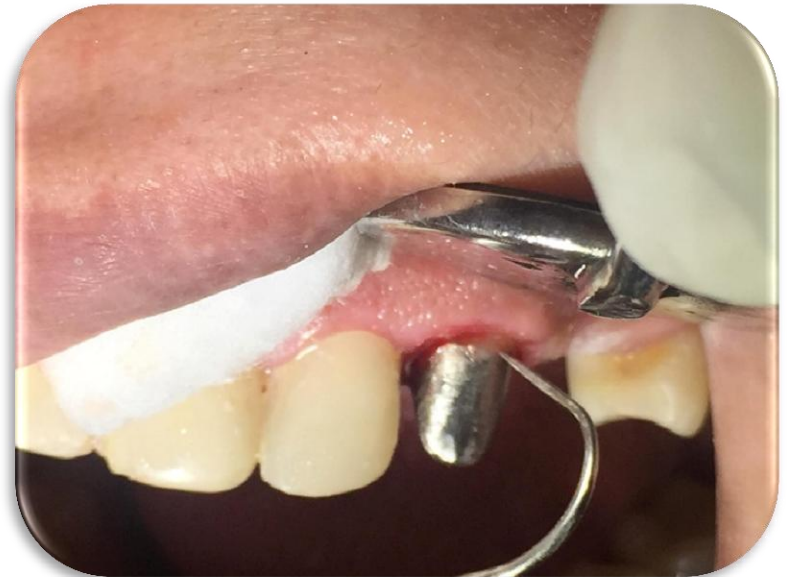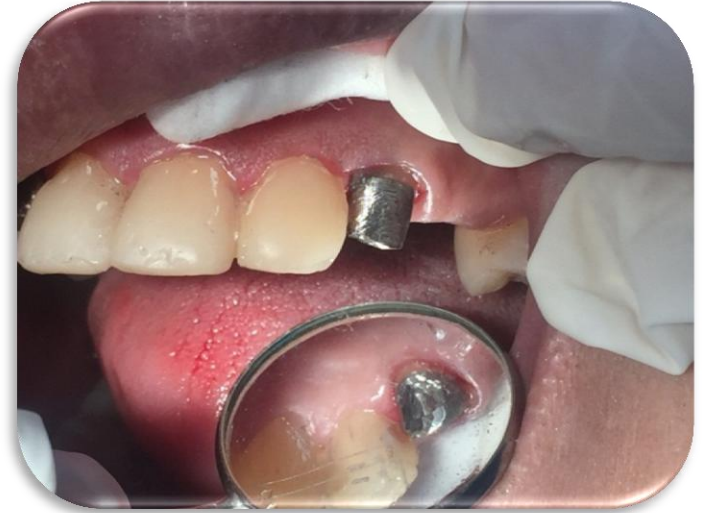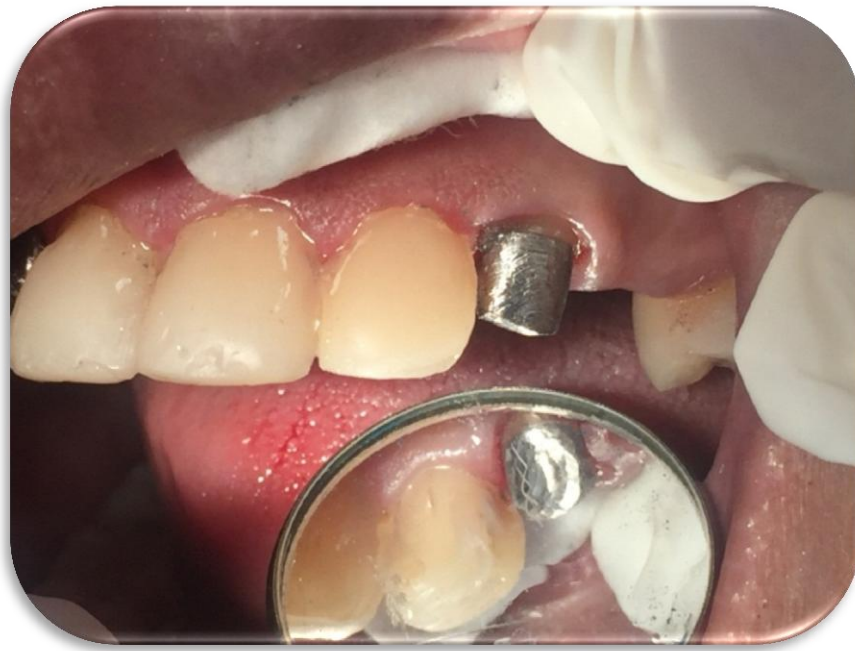Custom-Made Post



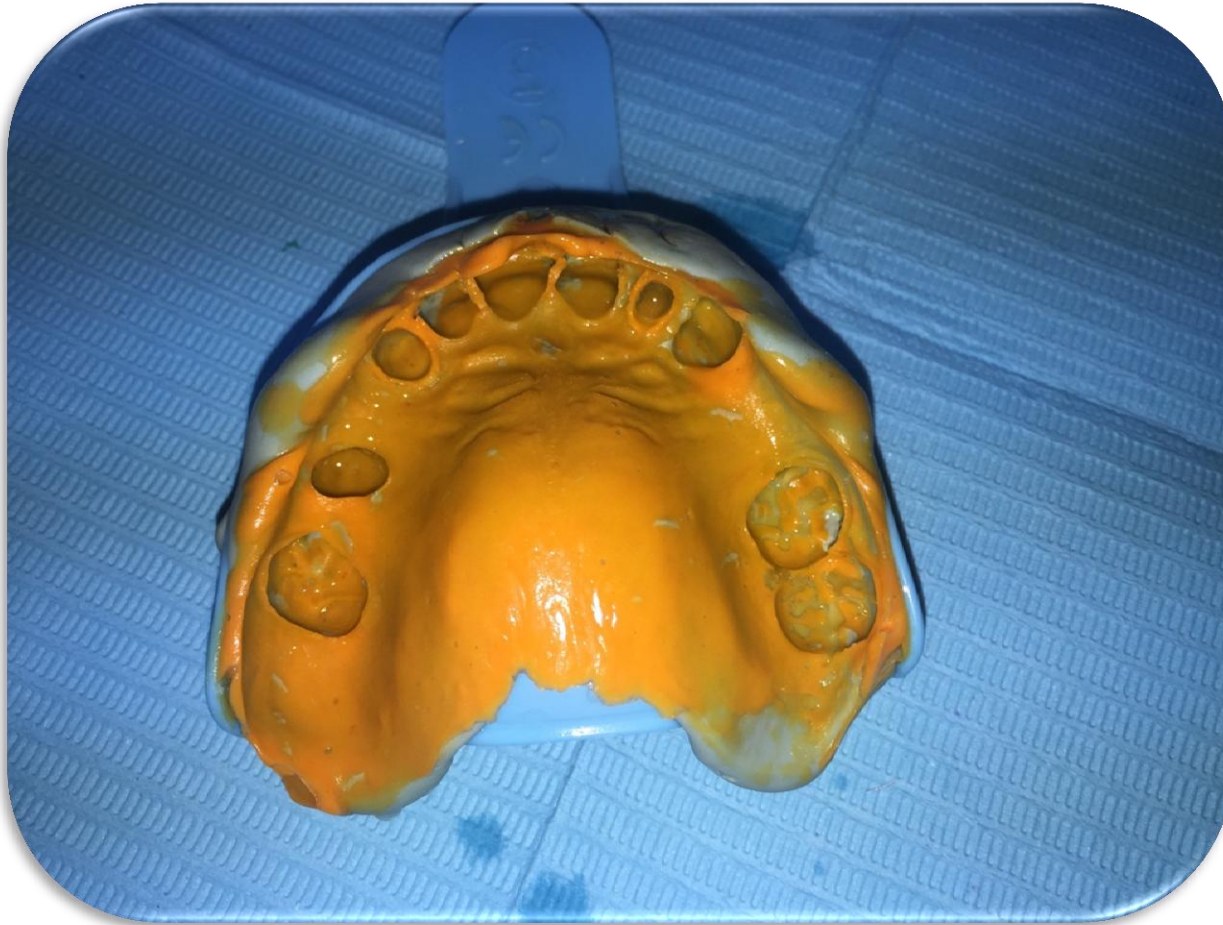X-ray Custom-Made Post



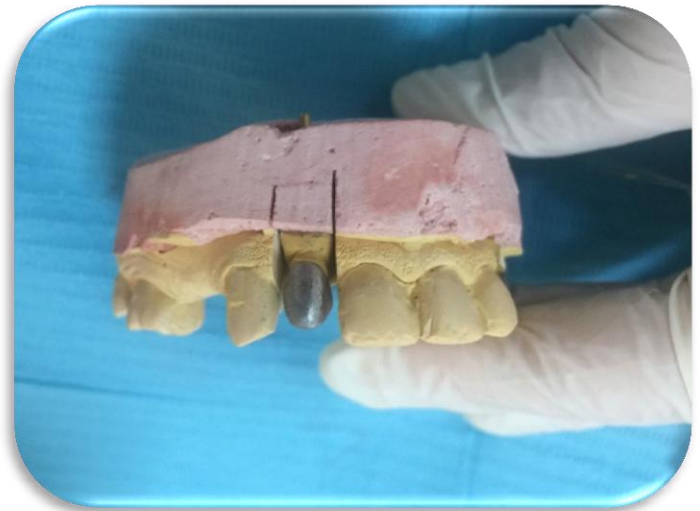
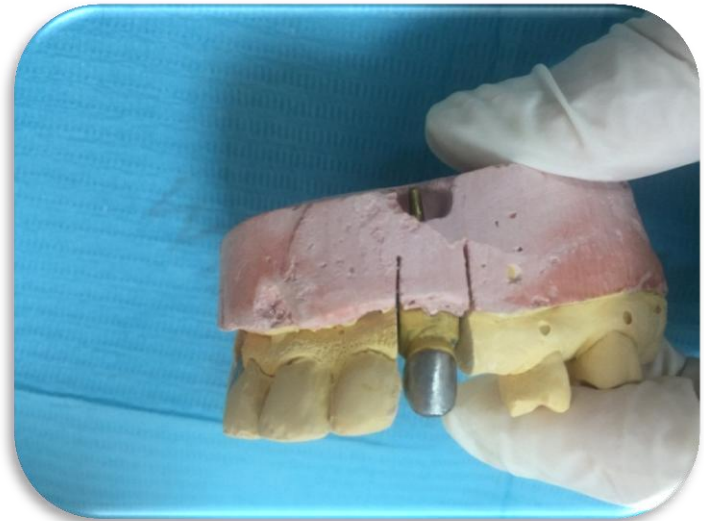
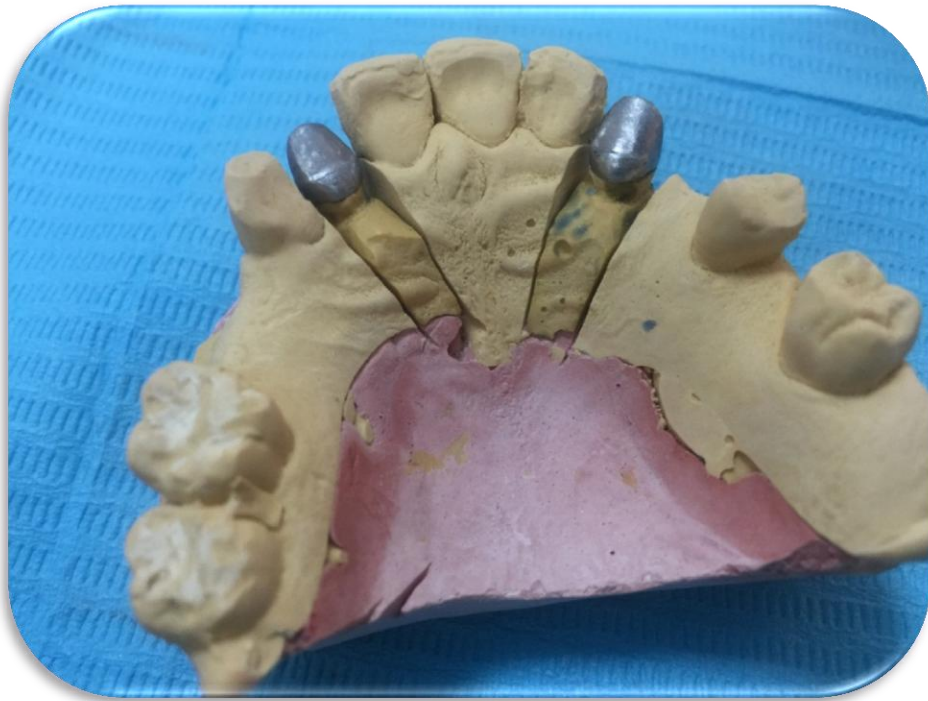Cementation For Custom-Made Post



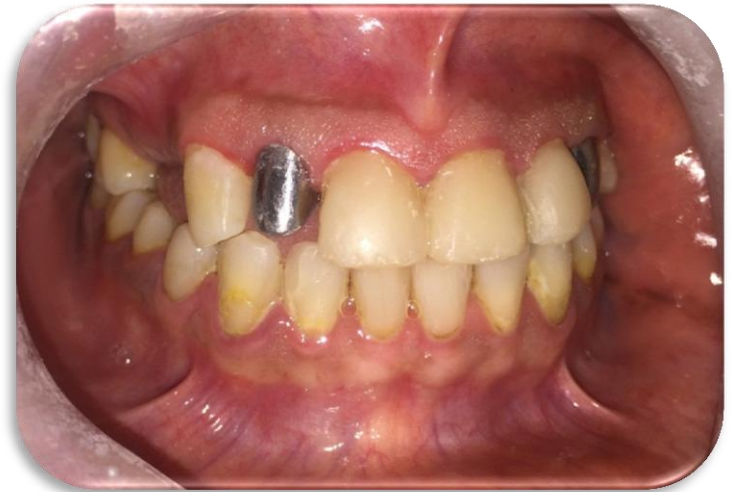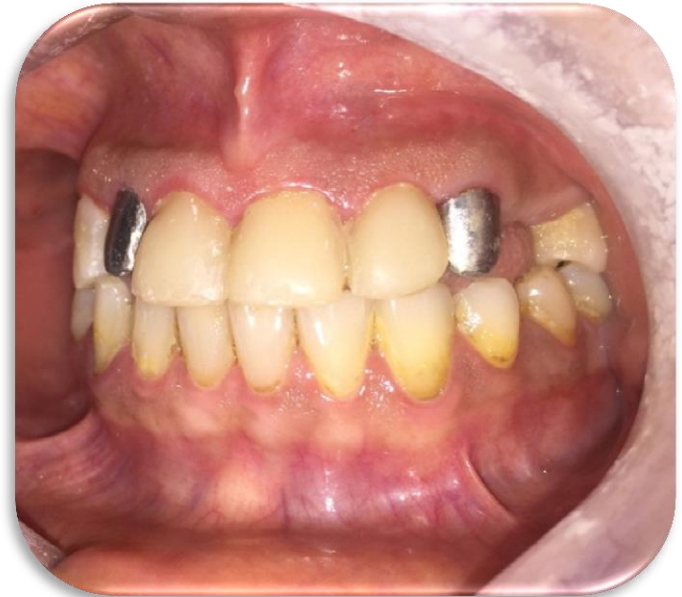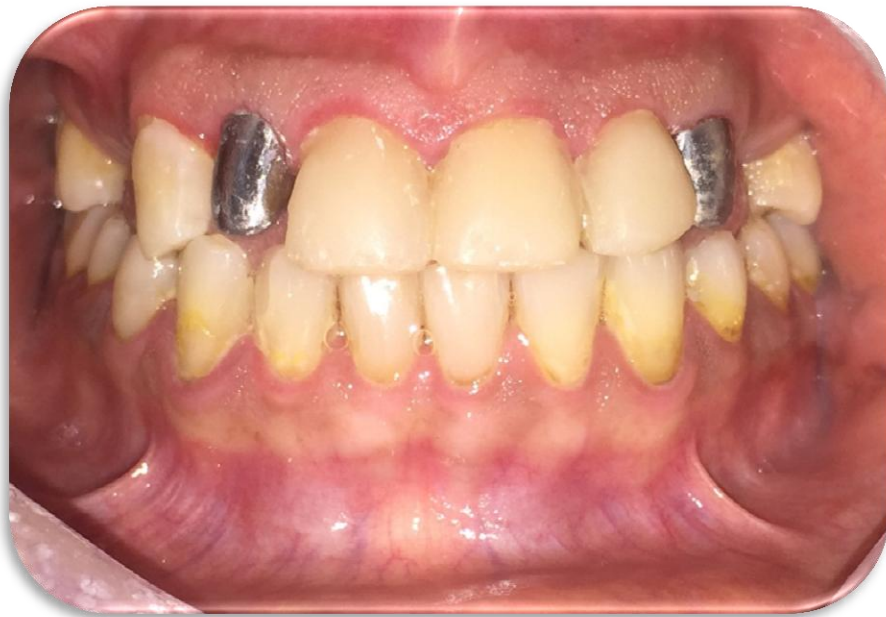Final Impression



Metal Try-in

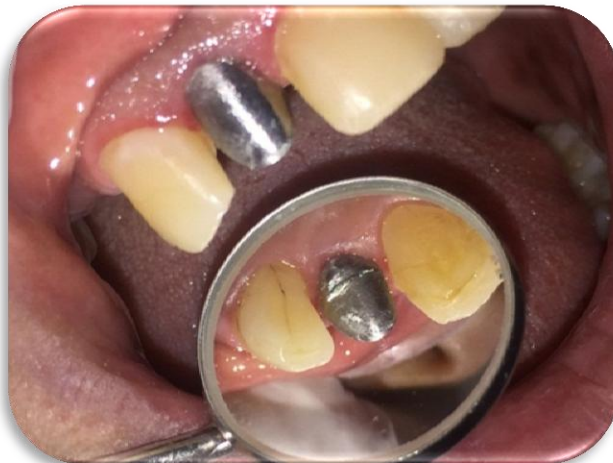
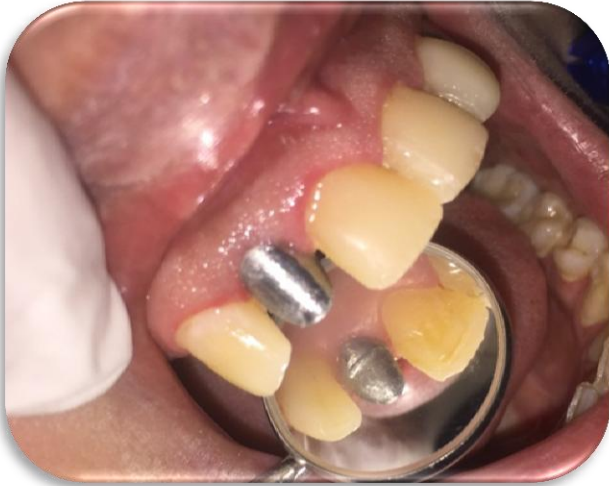
Metal Try-in

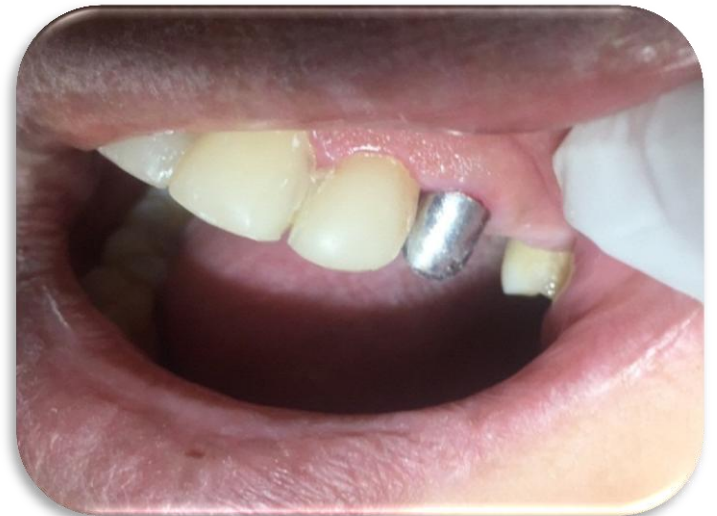
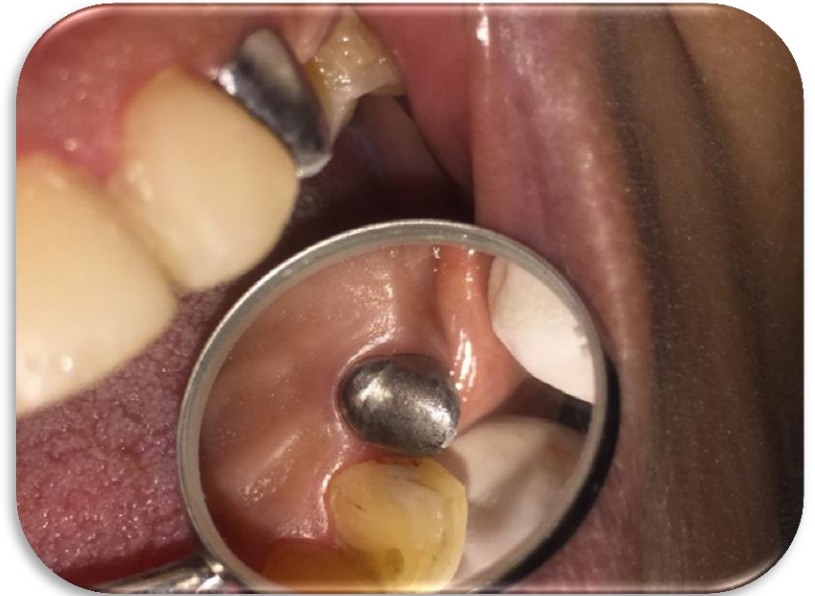
Metal Try_in

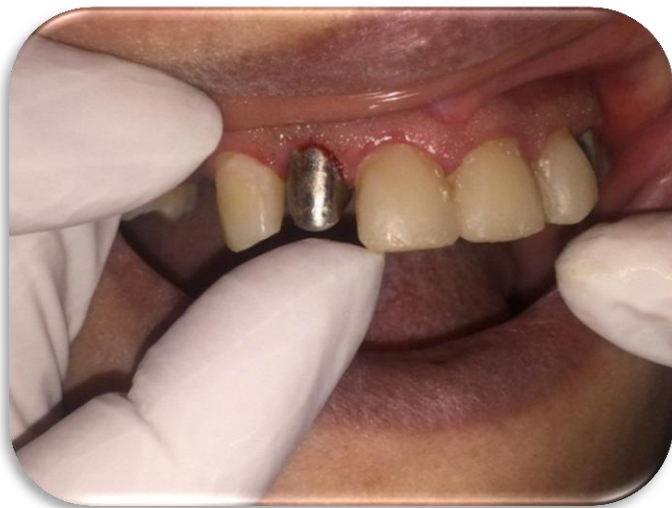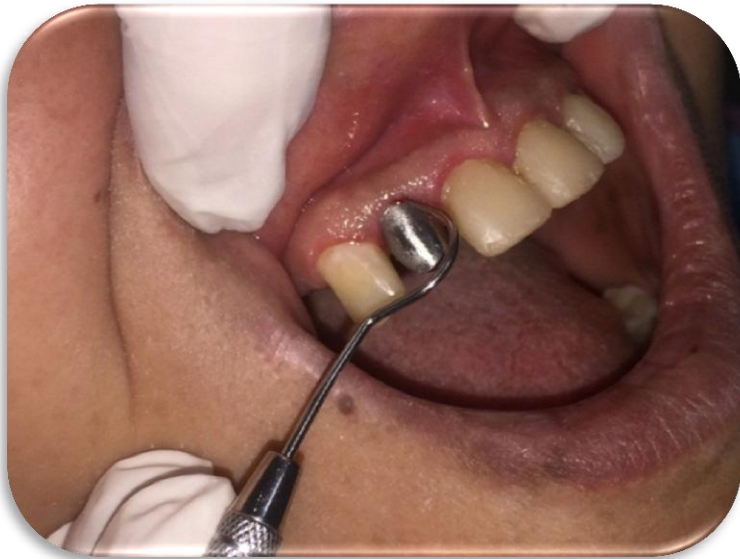Right incisor



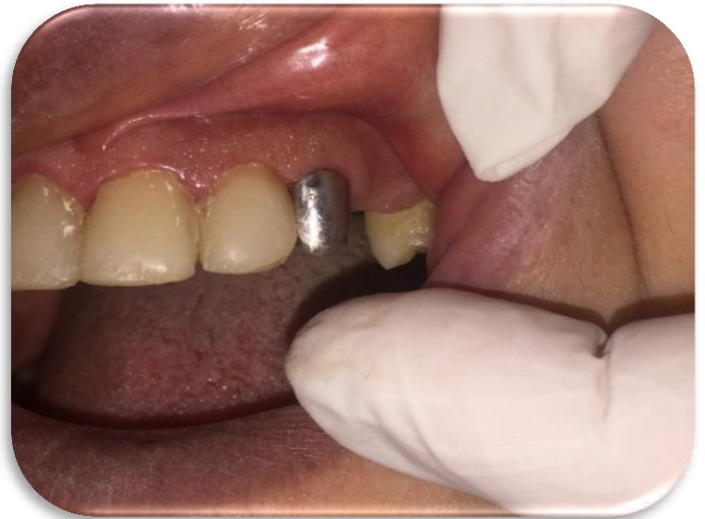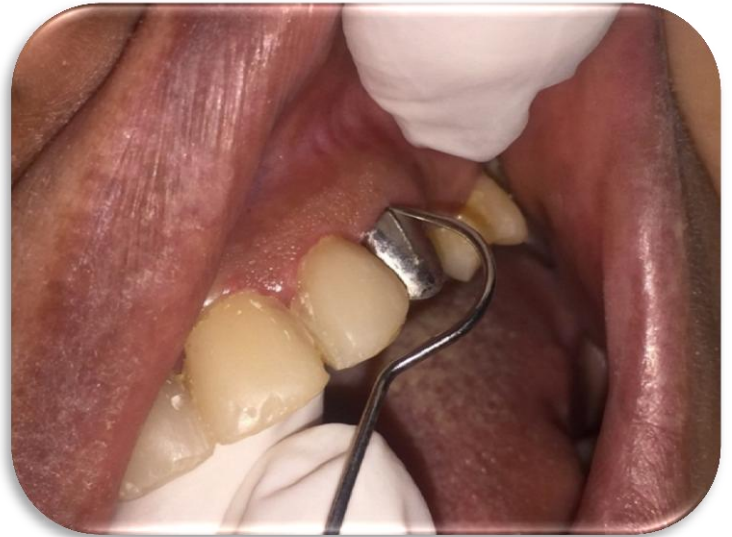Left canine



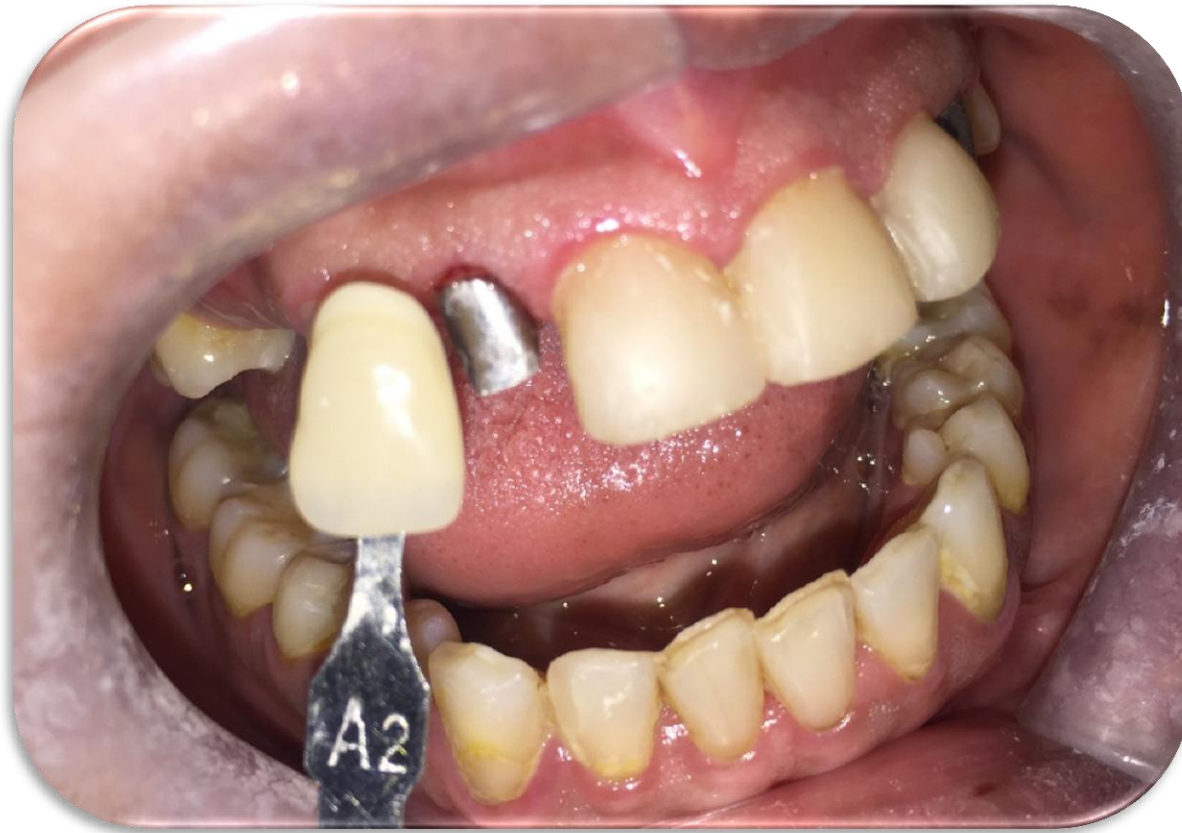Right incisor



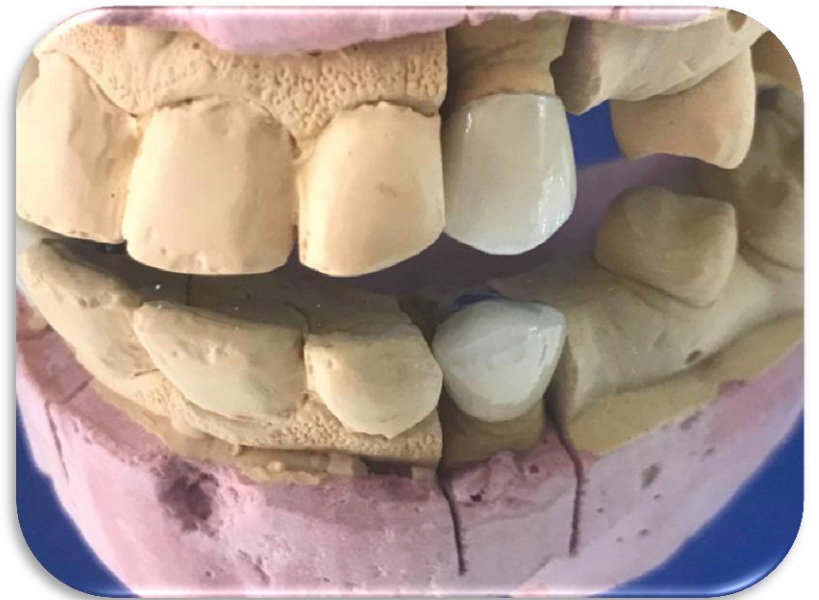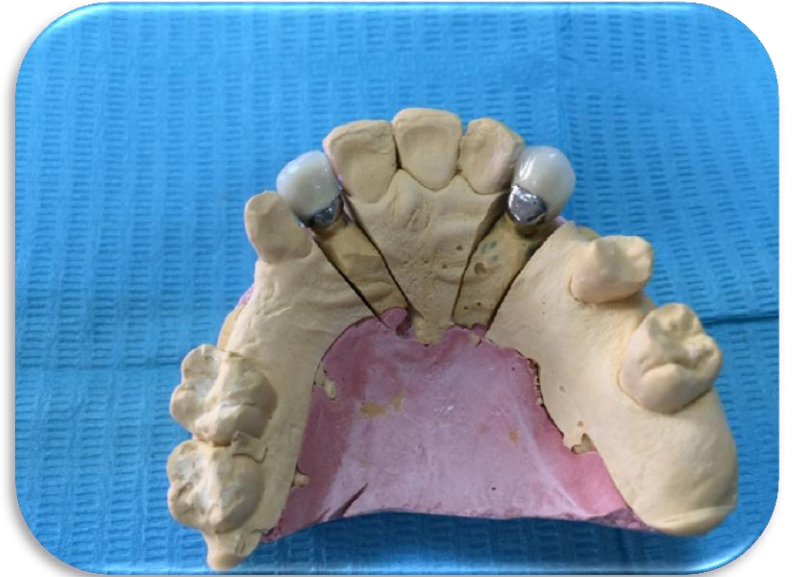
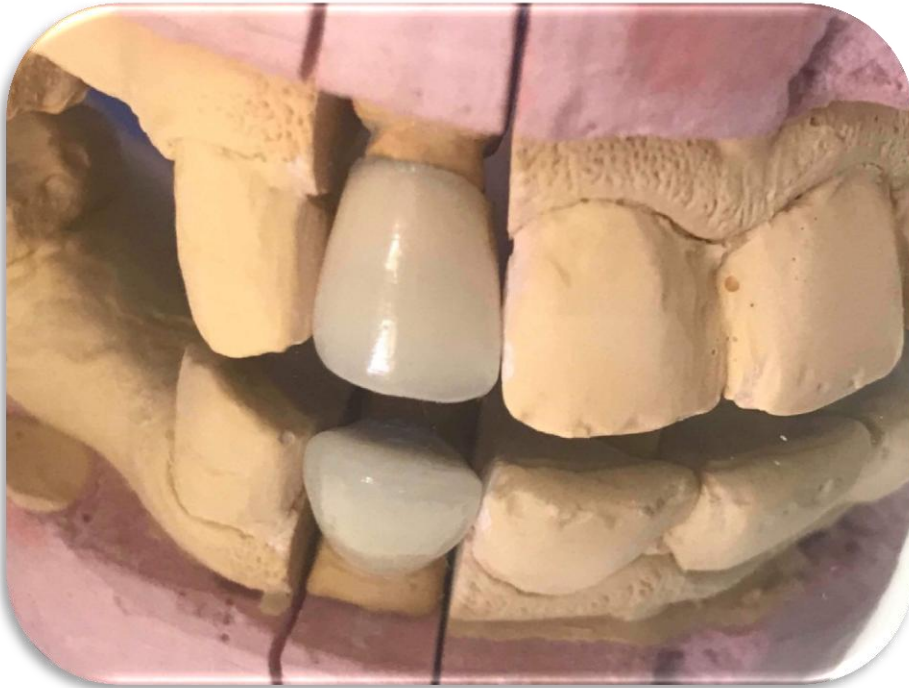Left canine



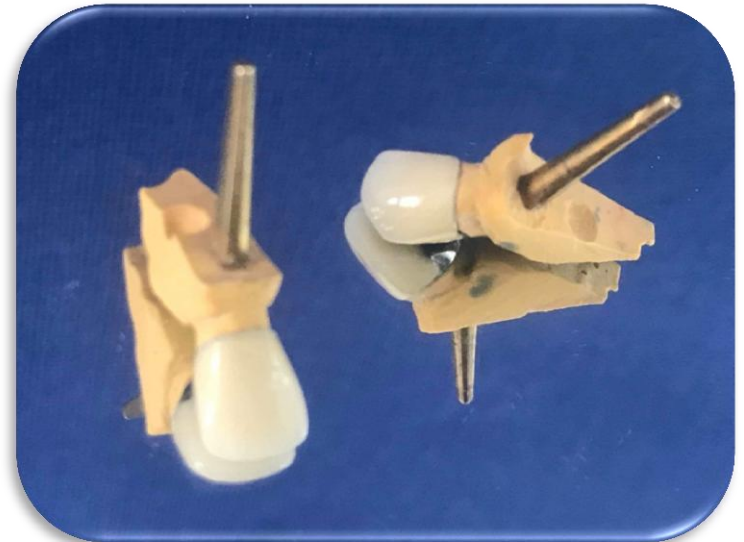
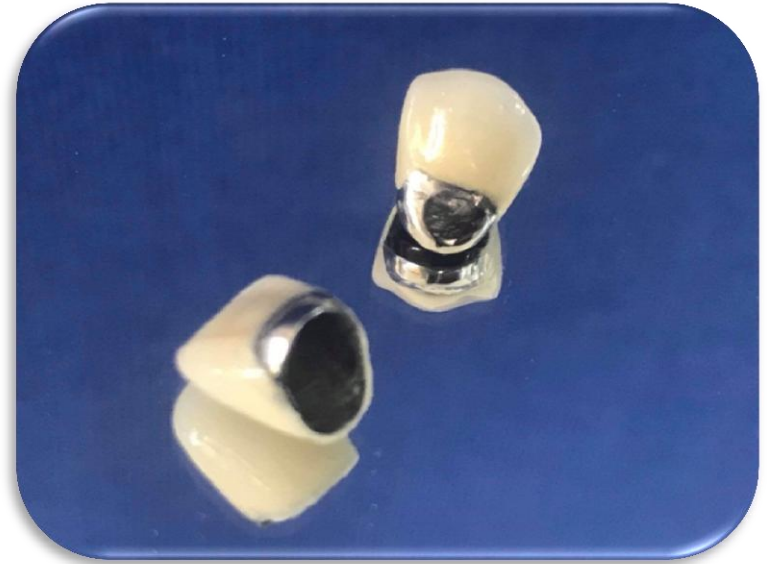

Shade Selection



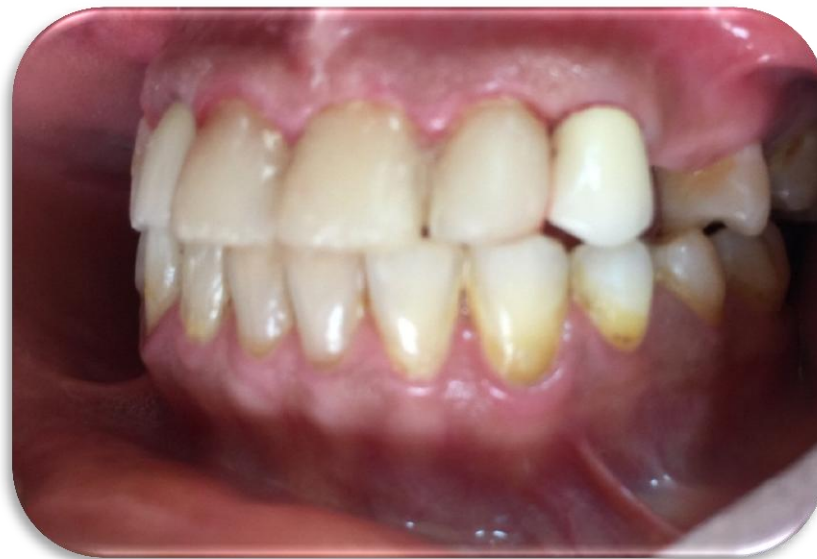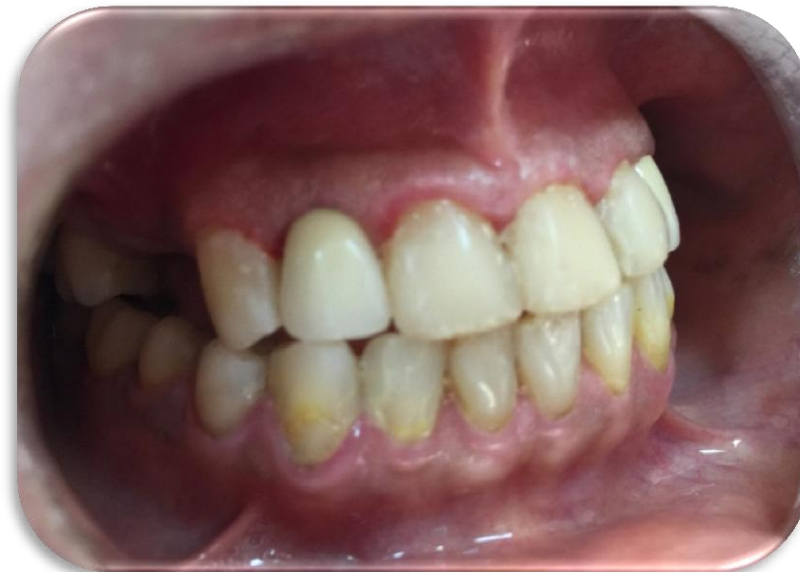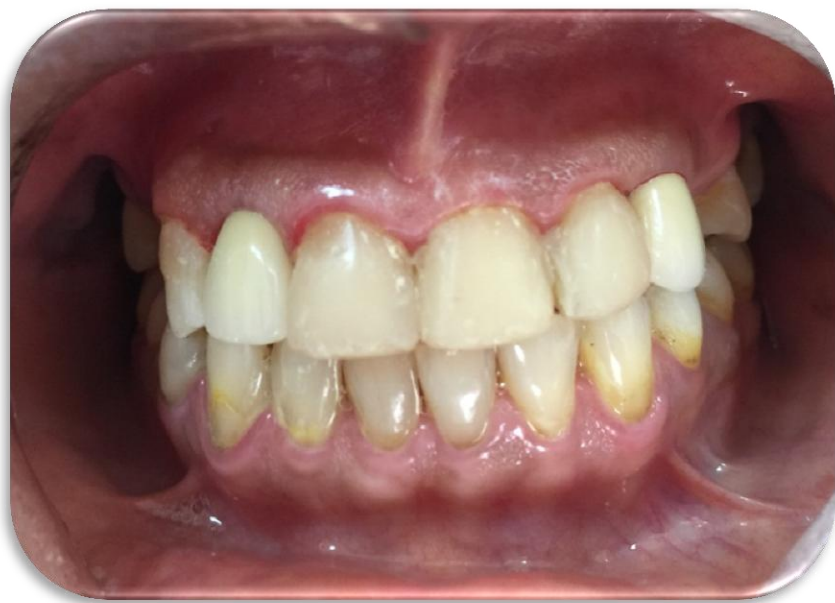PFM Crown

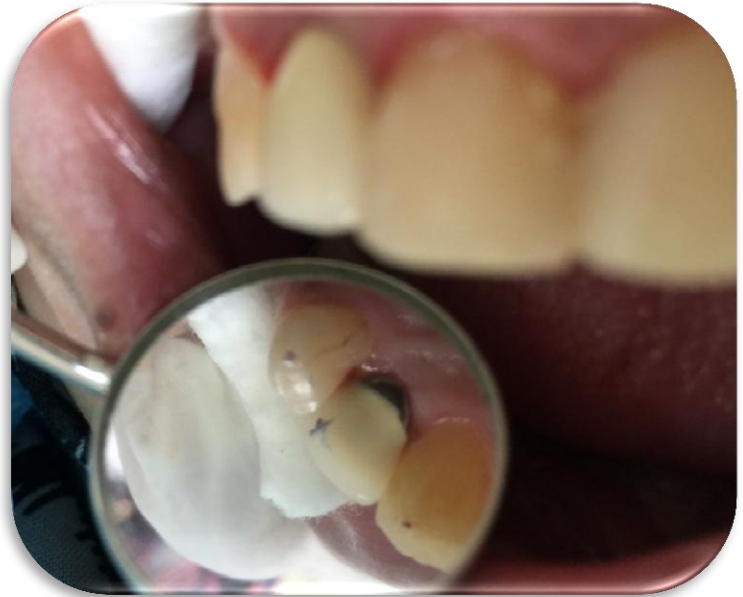
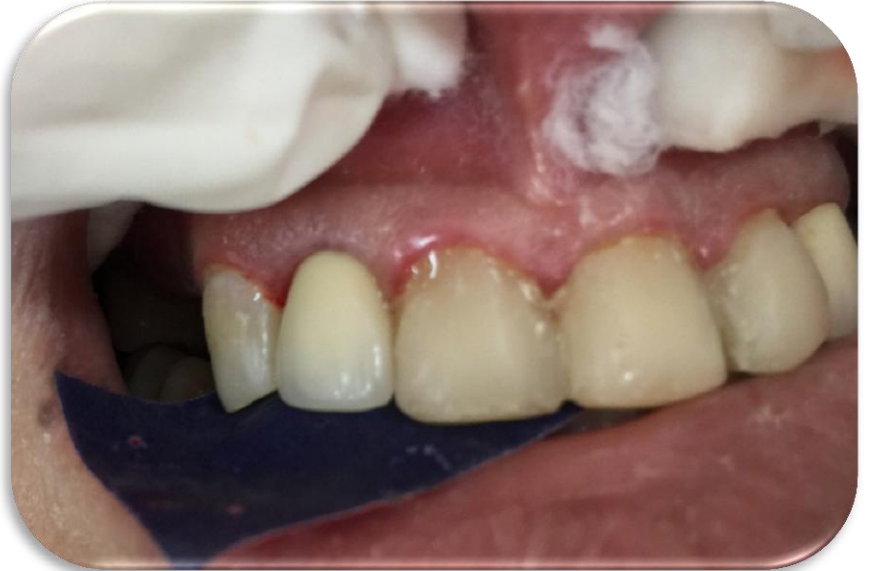
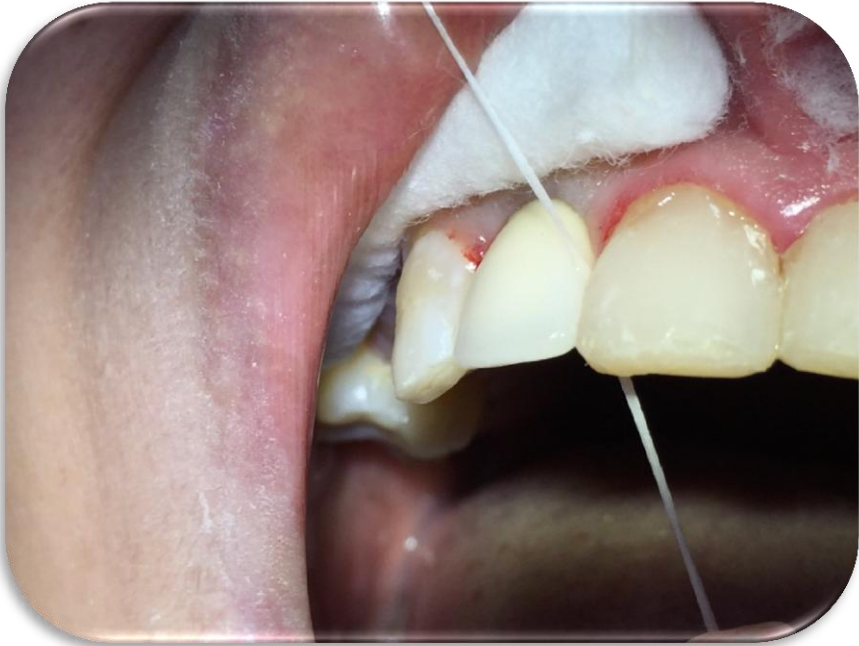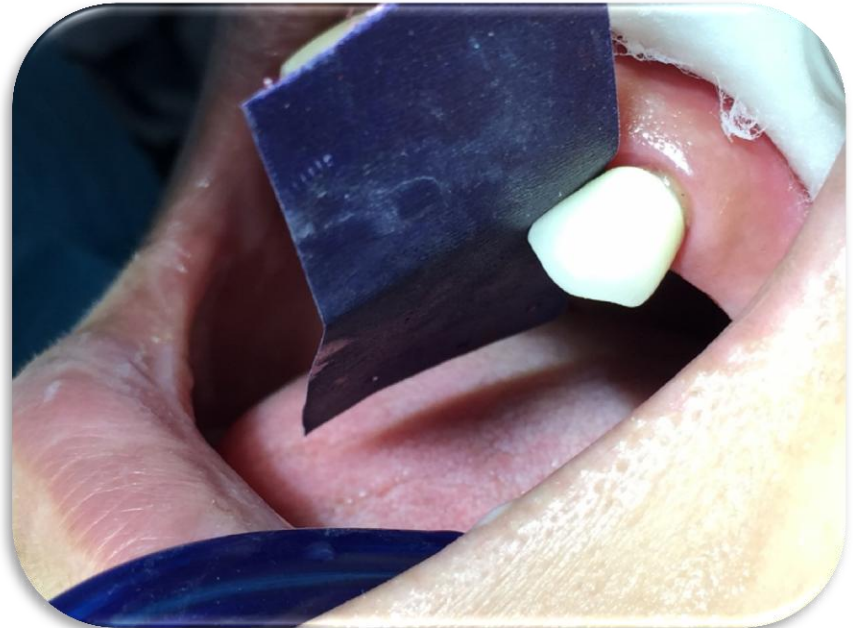
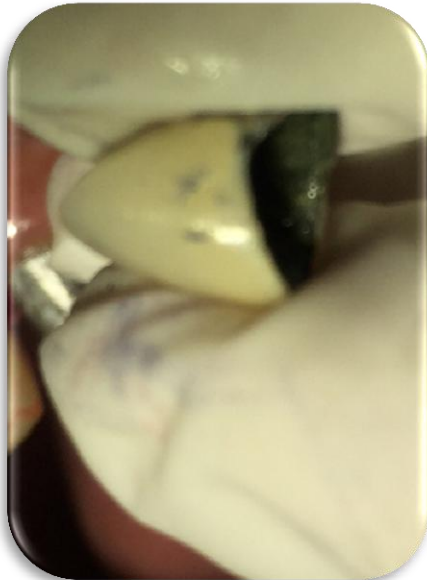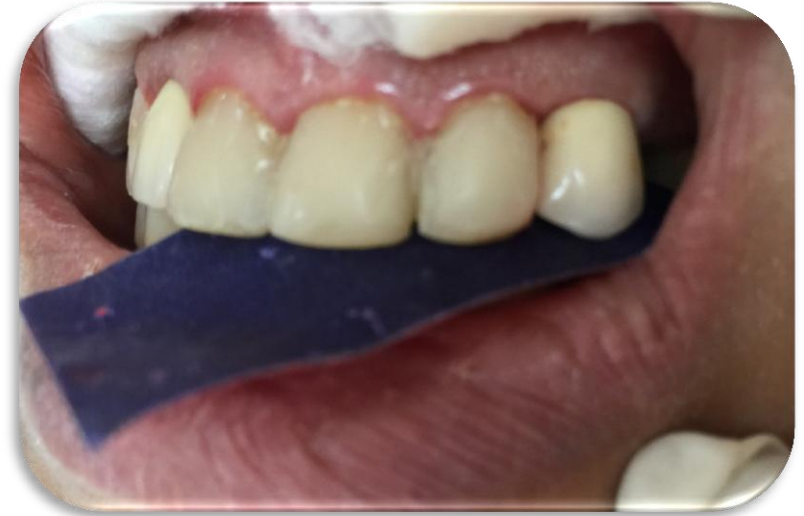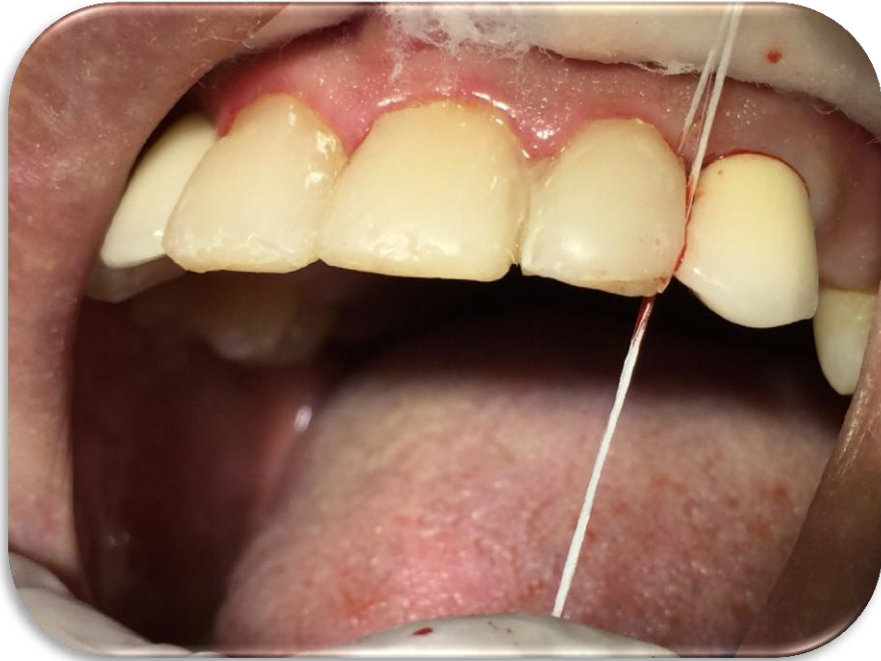PFM Crown



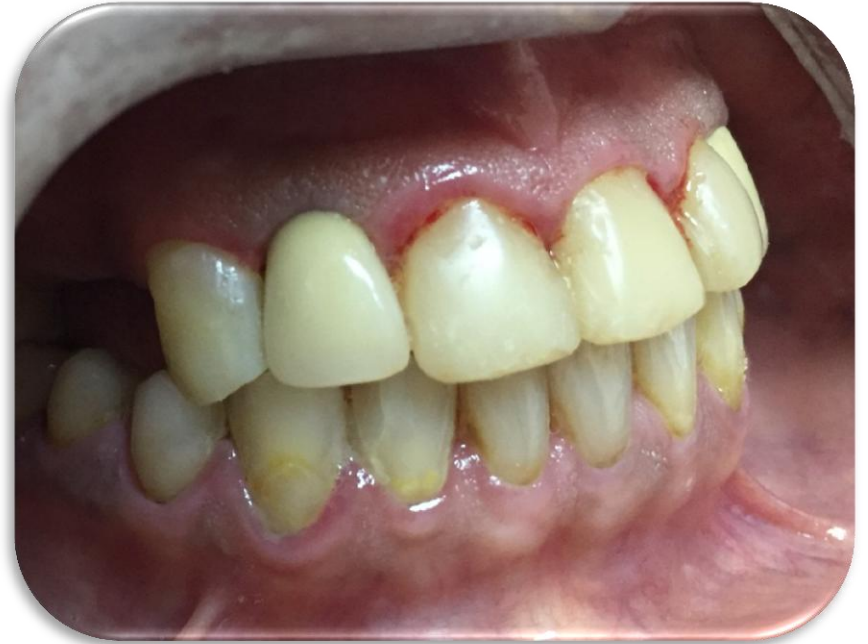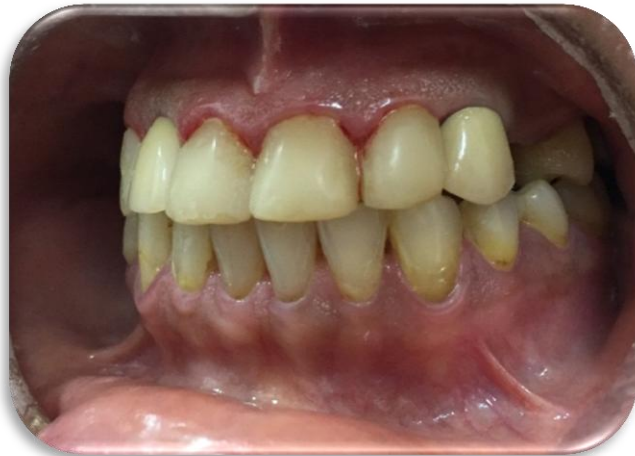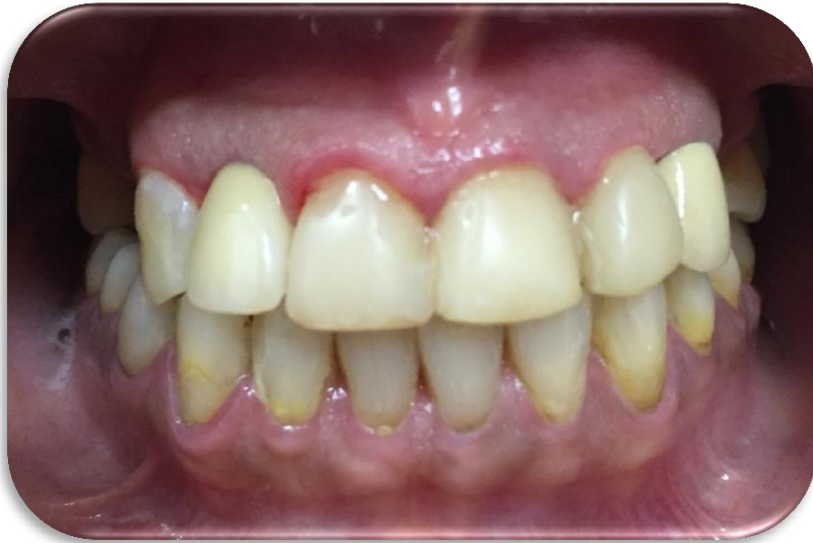Shade Not Matched



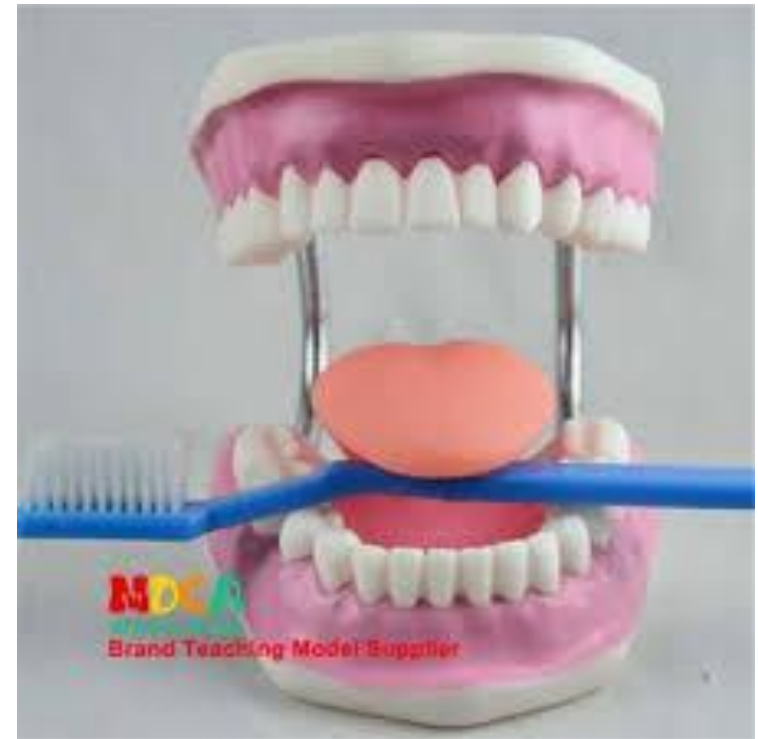
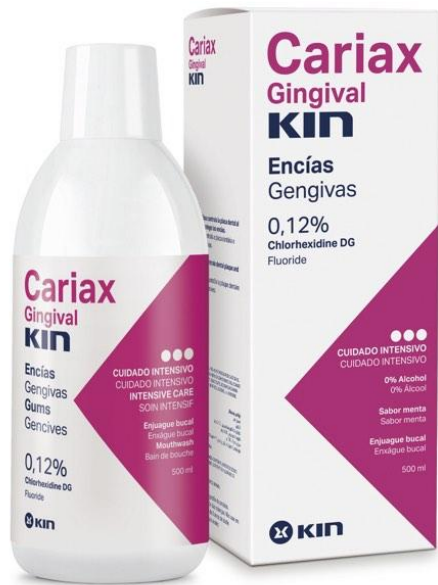


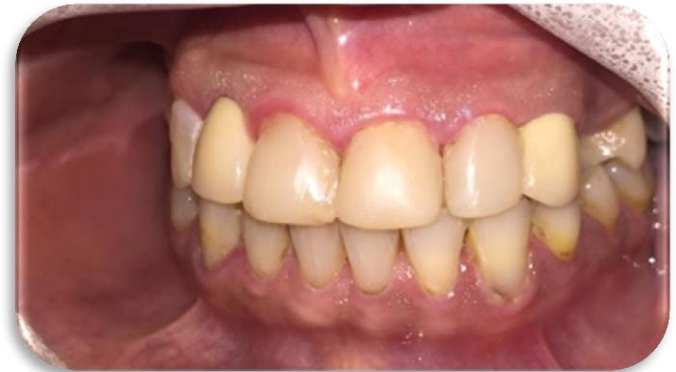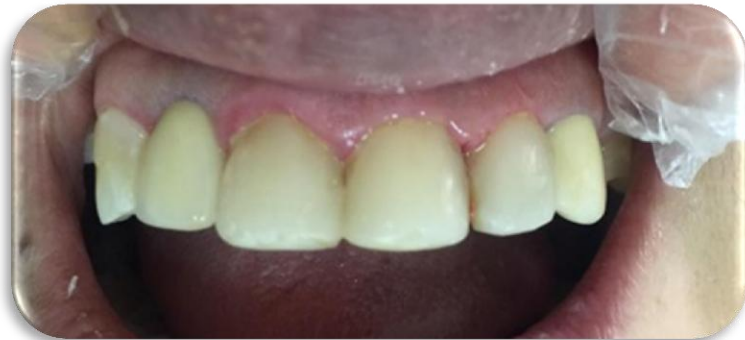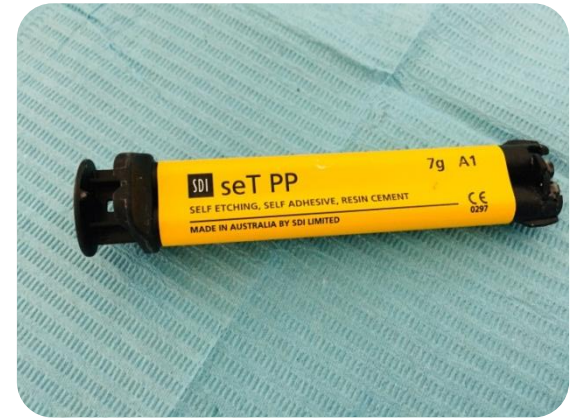
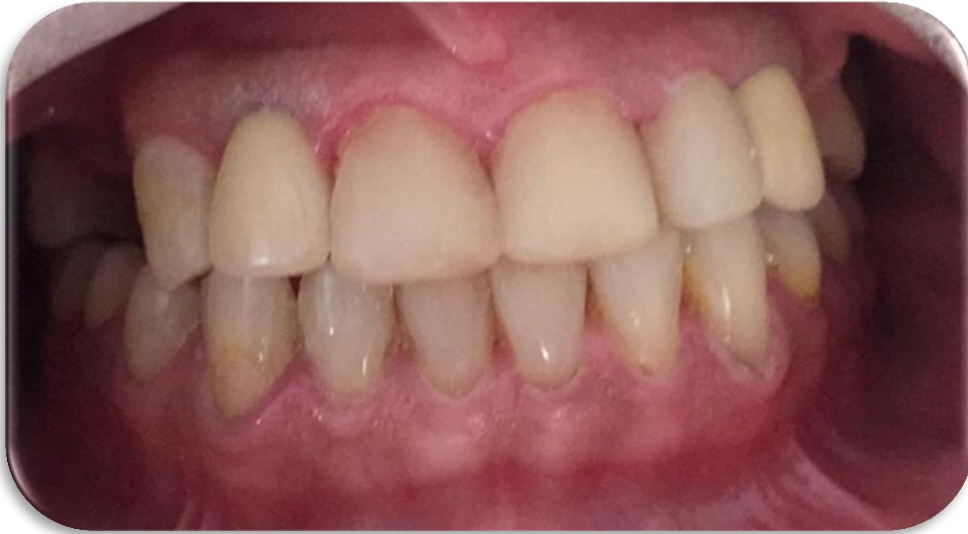Temporary Cementation



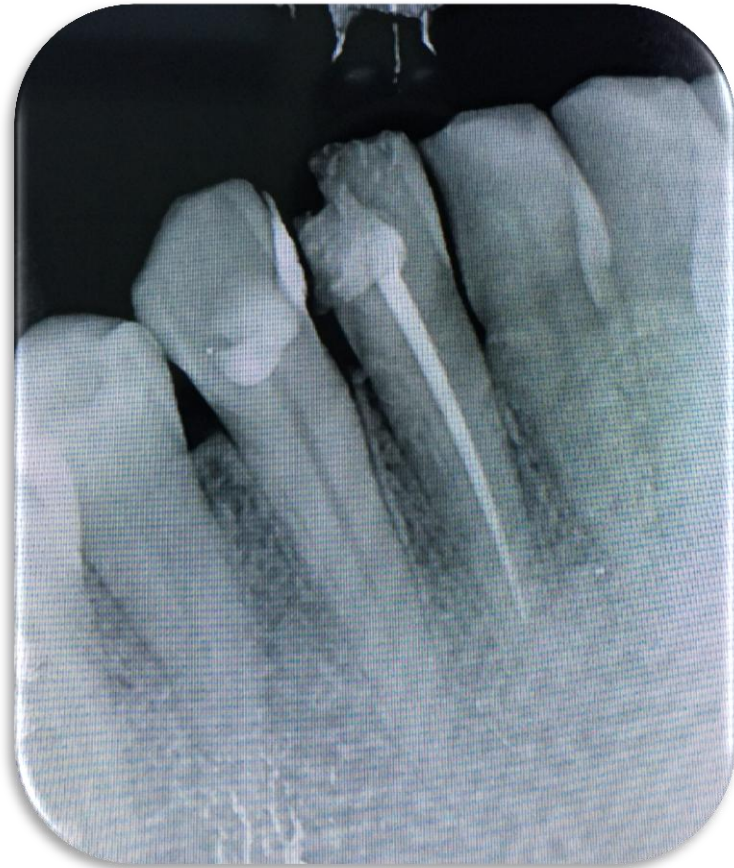Instruction



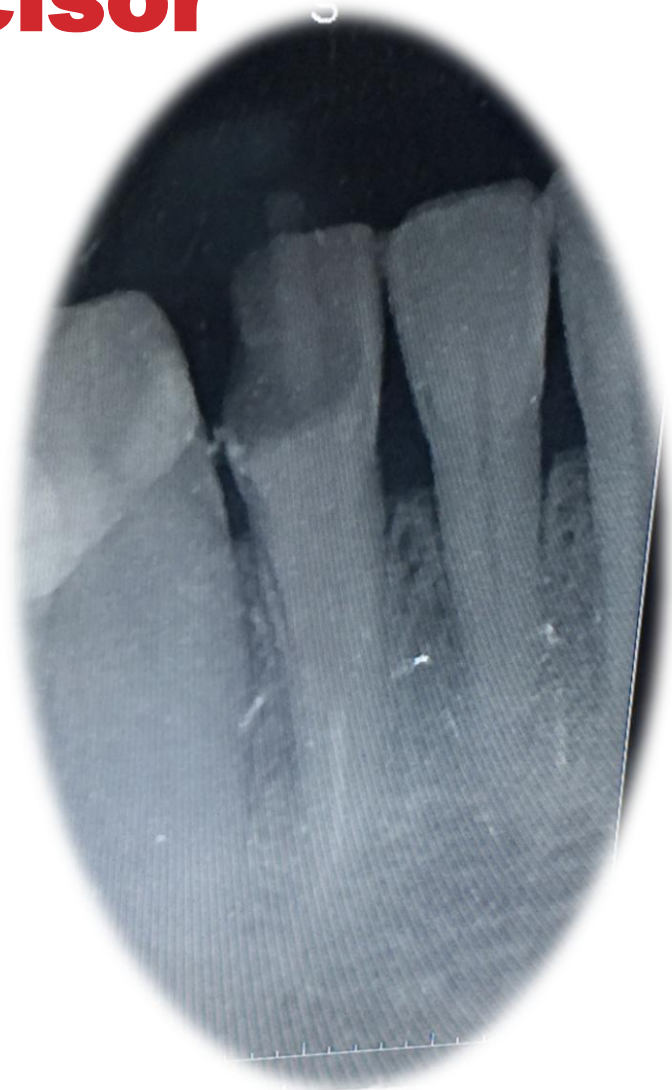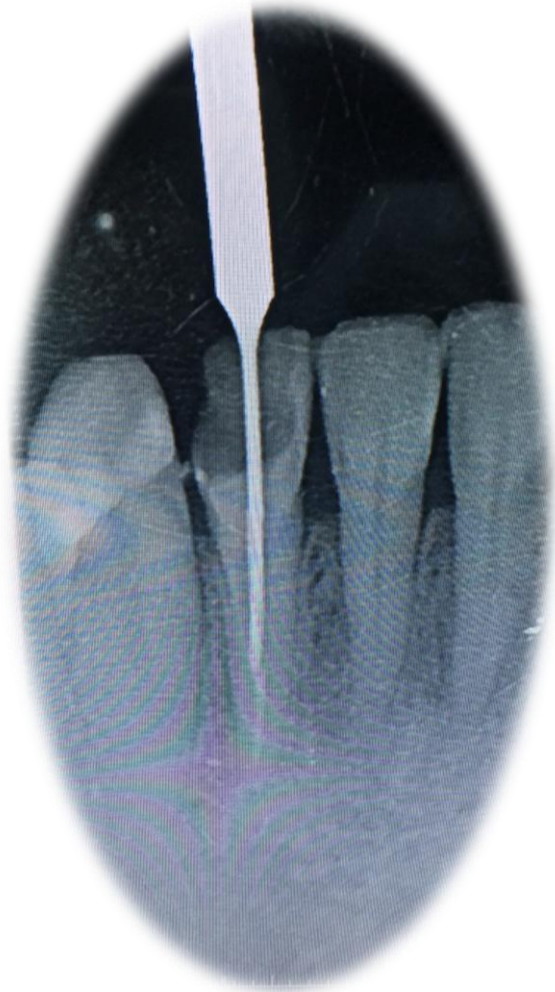
Final Cementation



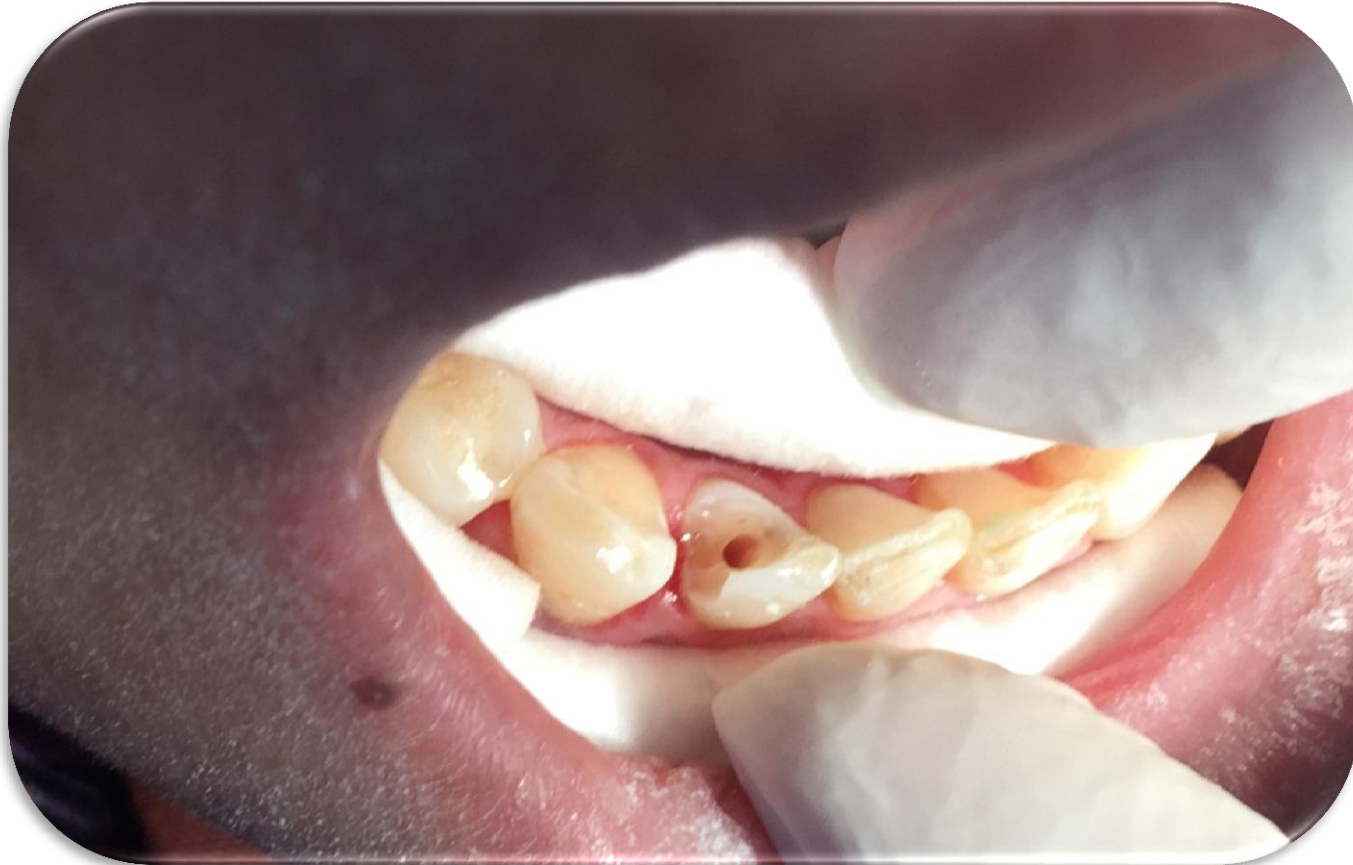Preparation For Lower Right Lateral Incisor



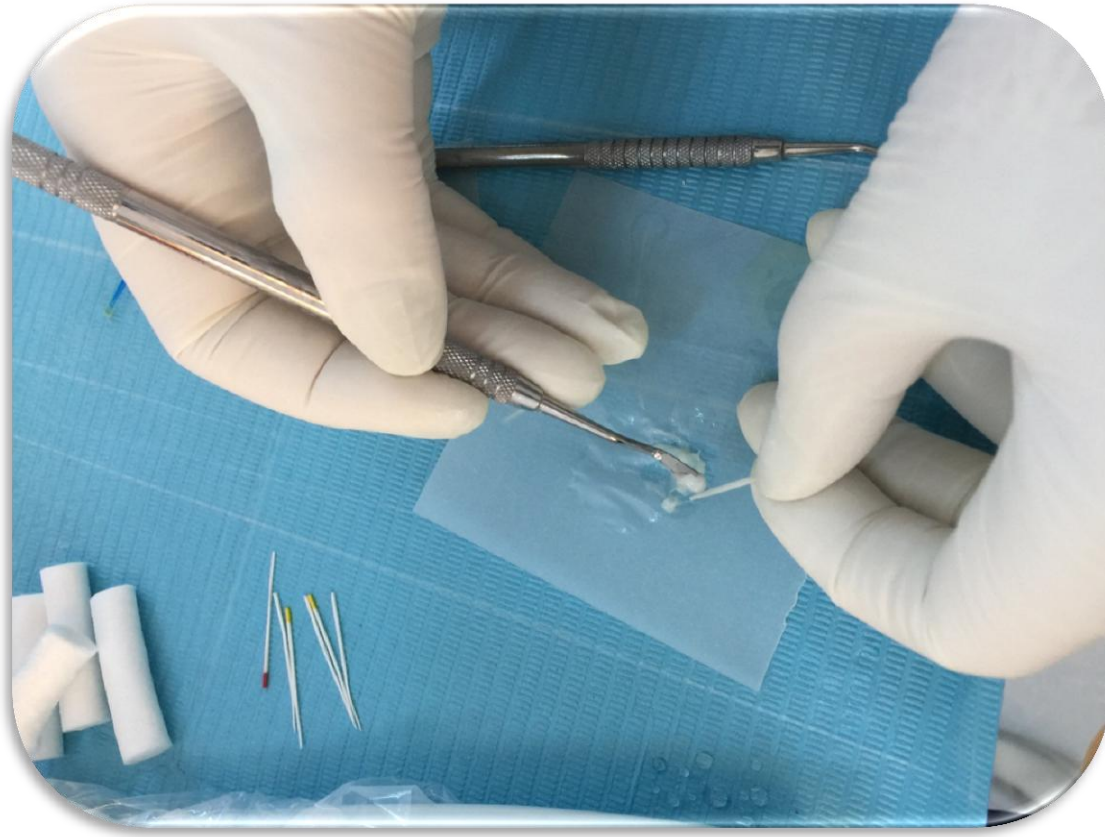Post Preparation For Lower Right Lateral Incisor



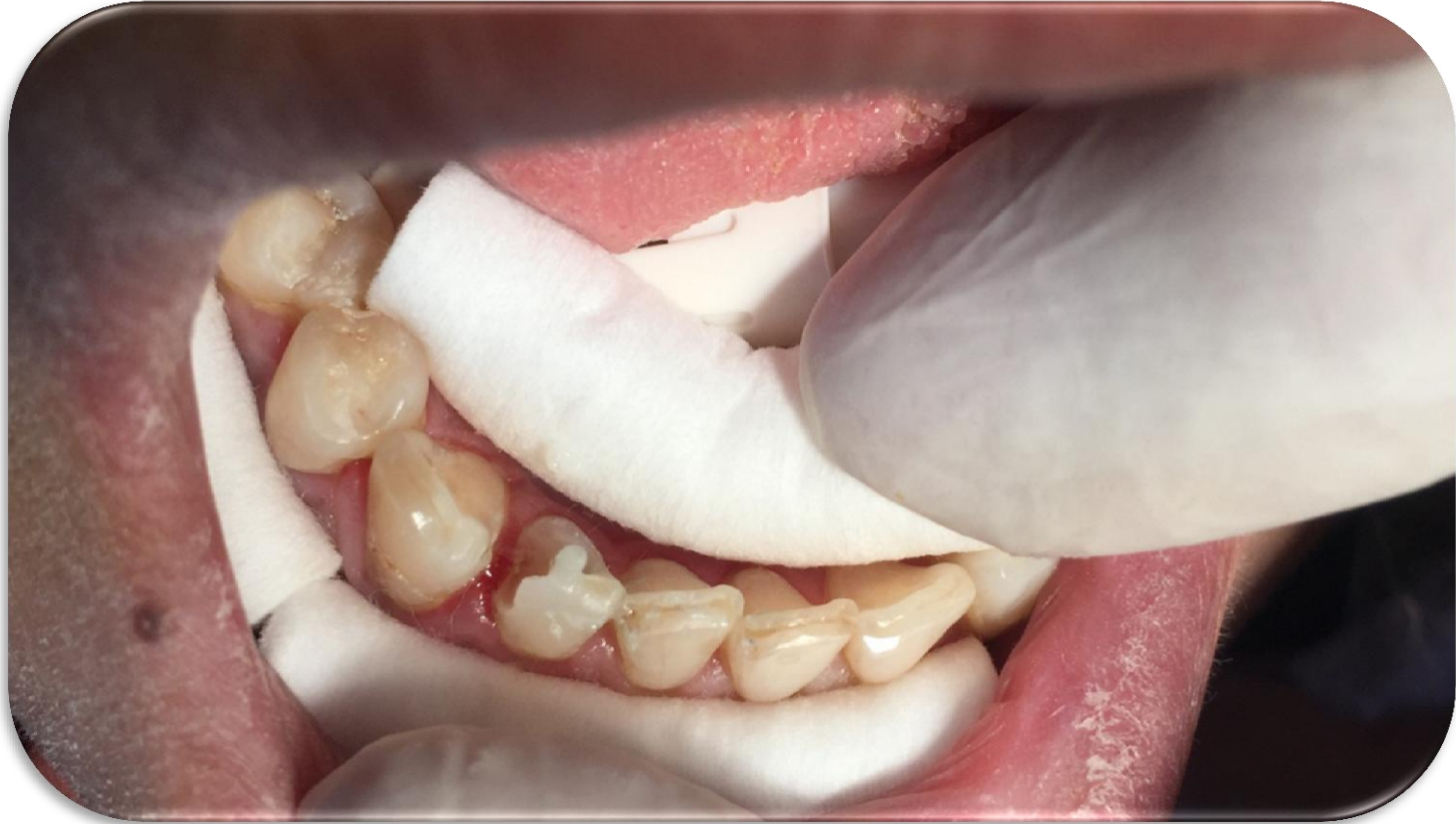Intra Oral Photo



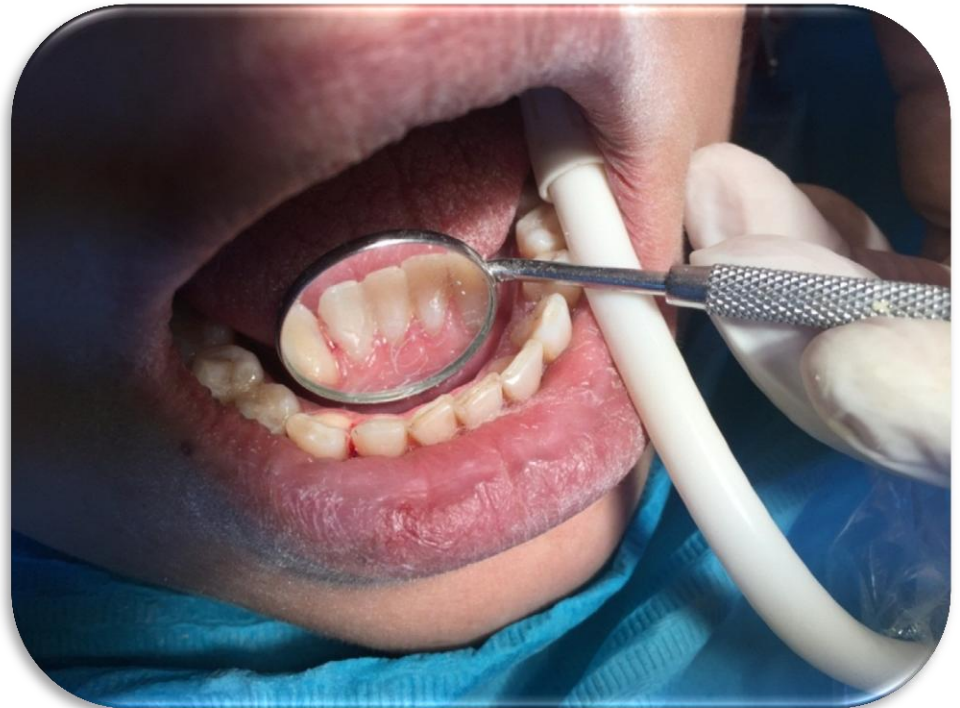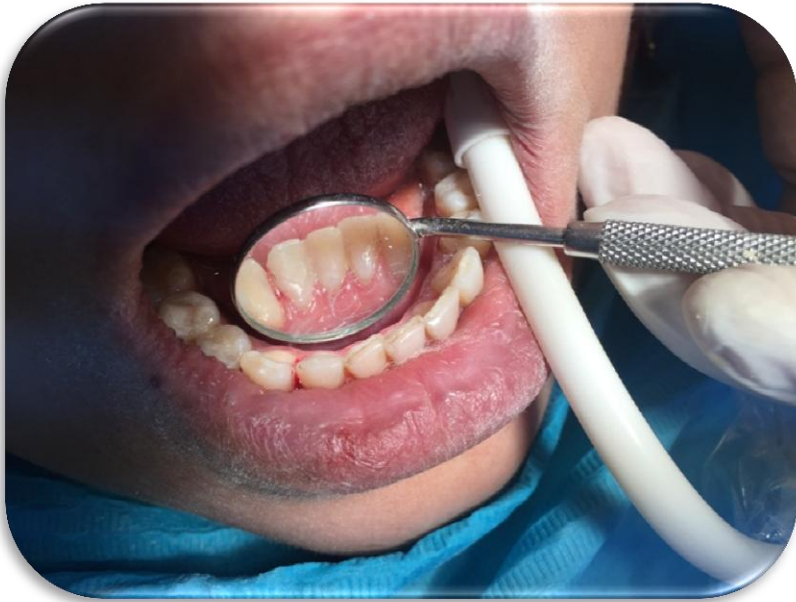Final Cementation For Ready Made Post



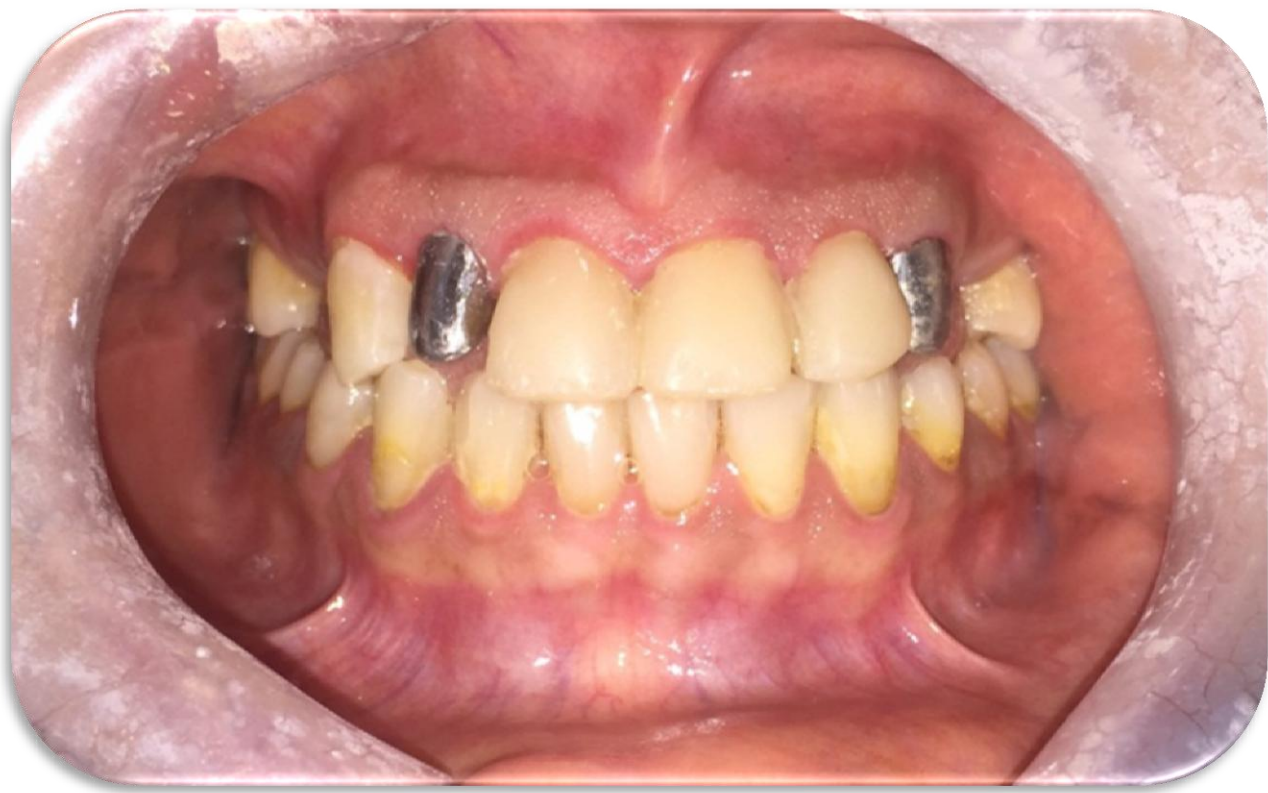Cementation For Post



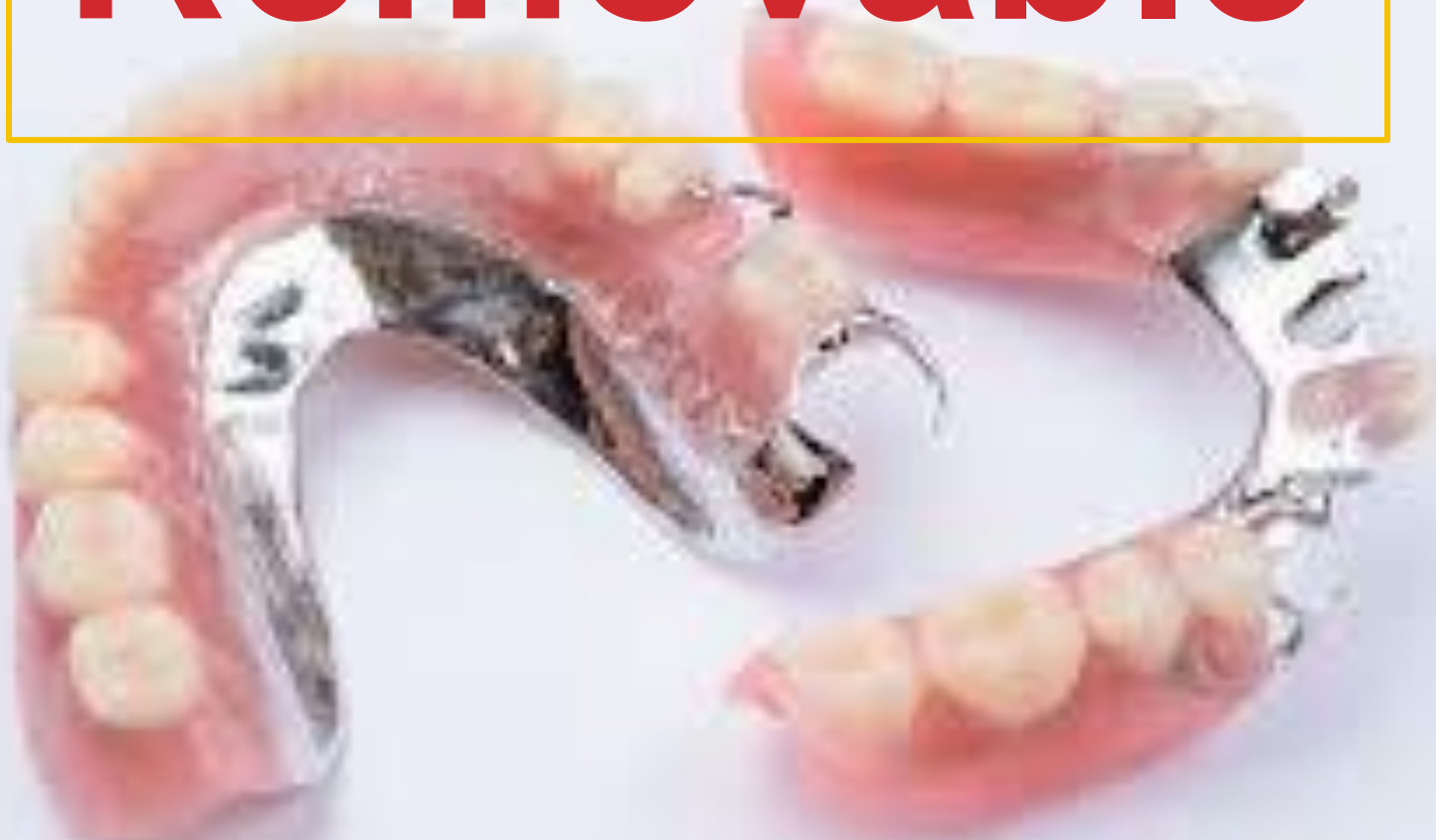Composite Restoration (Build up)



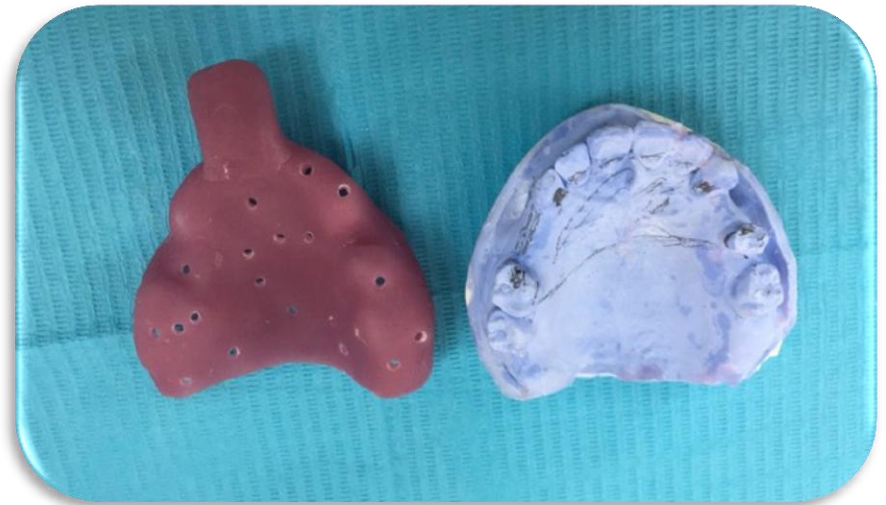
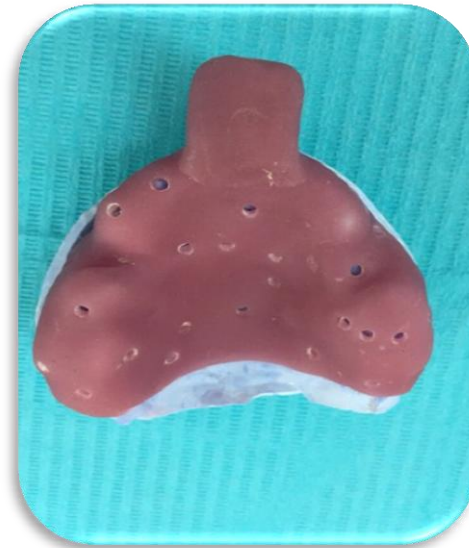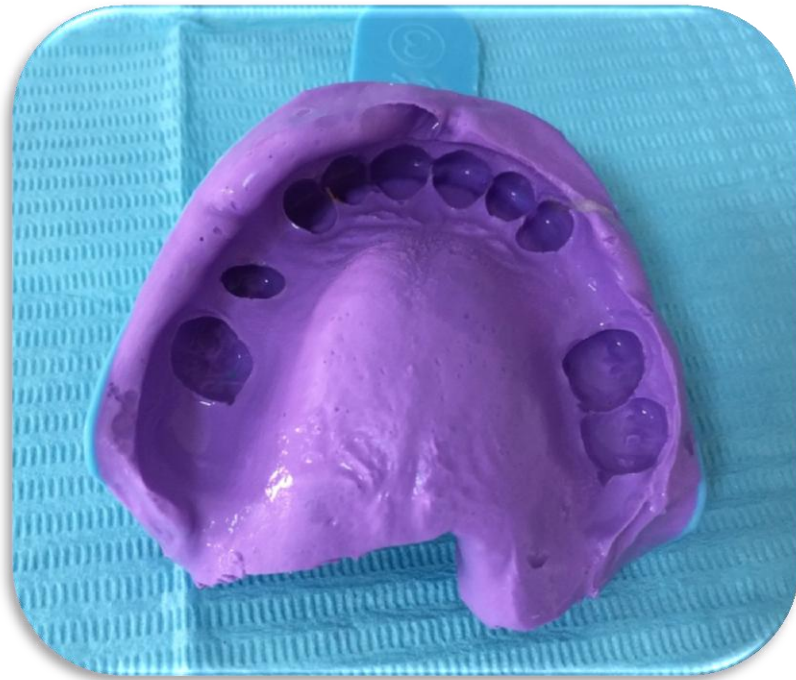Re-evaluation after 6 week



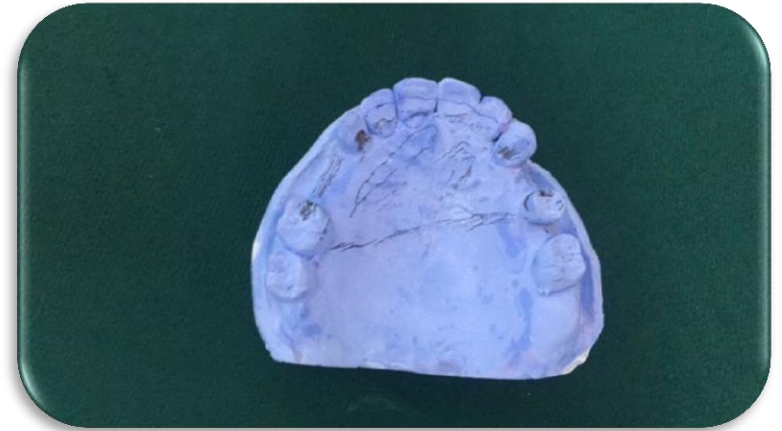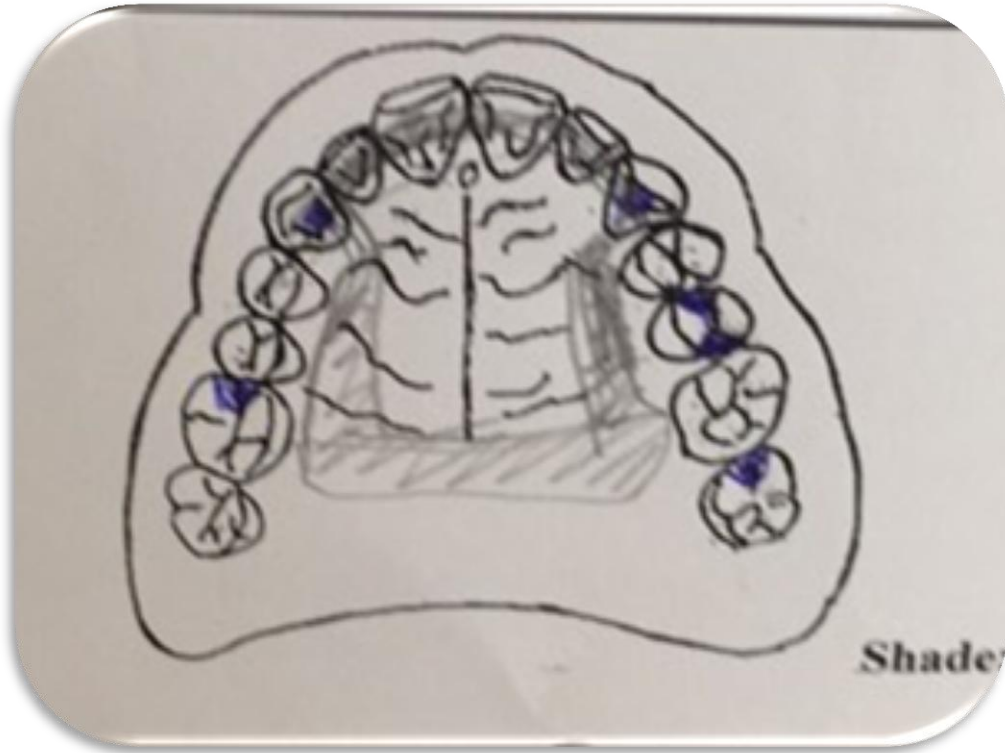
Removable



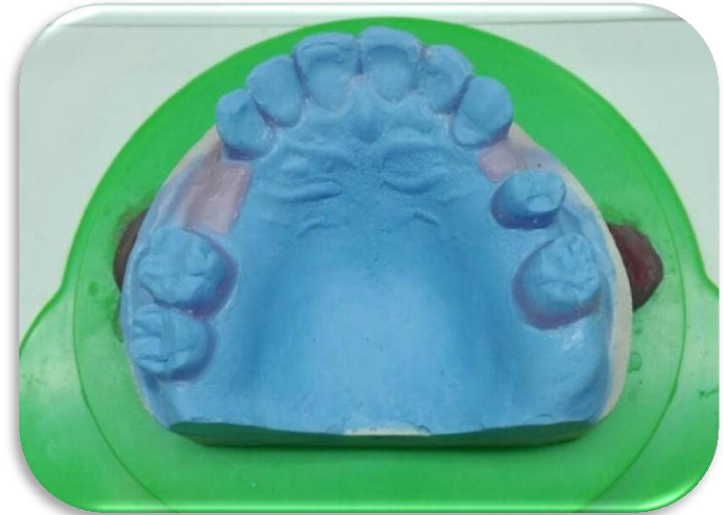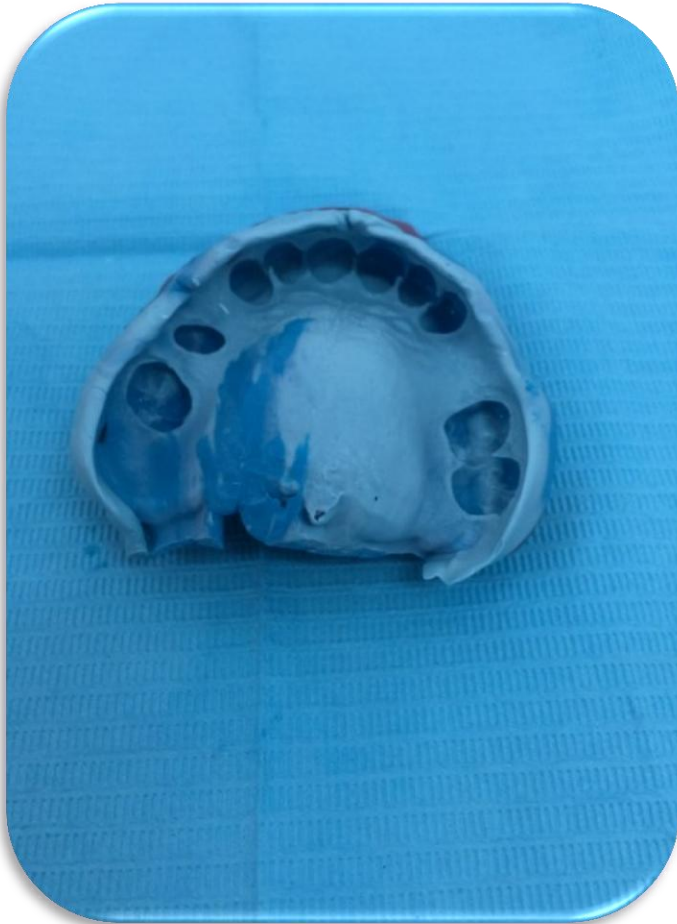
Primary impression (Special Try)

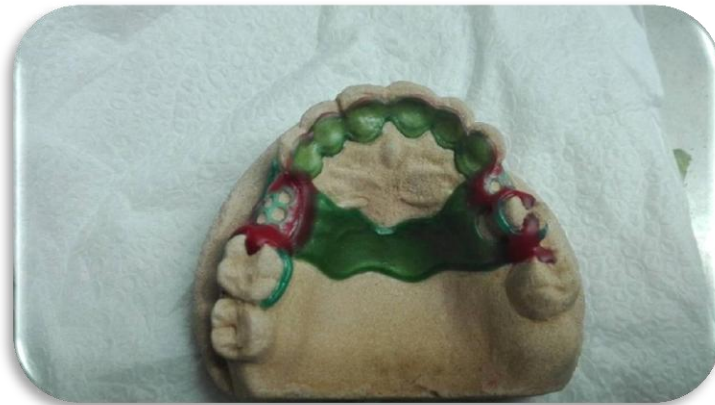
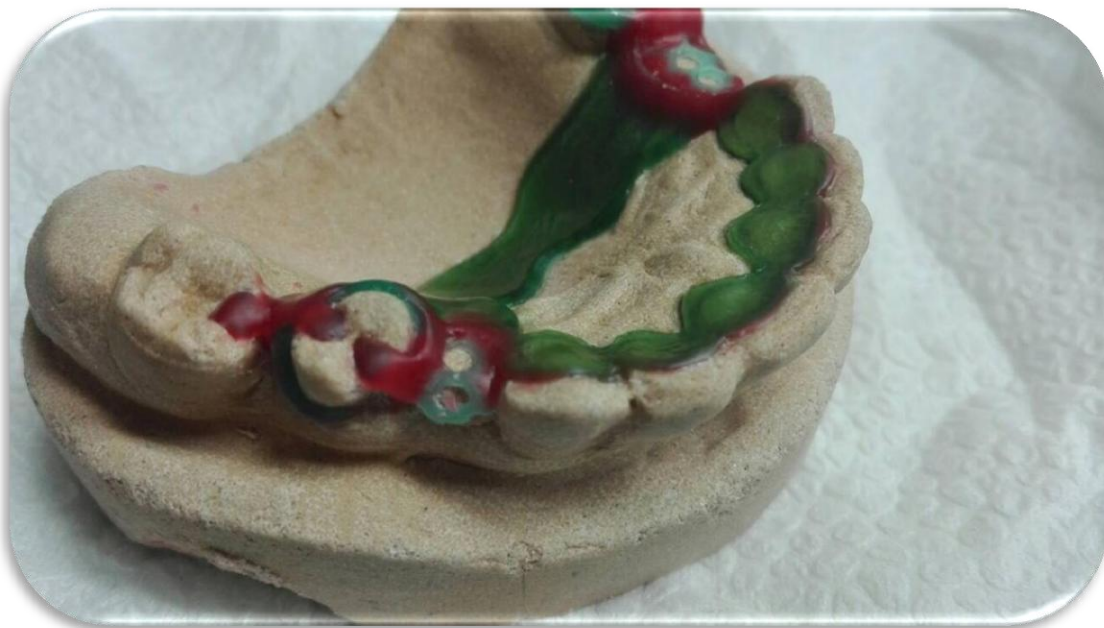
Design

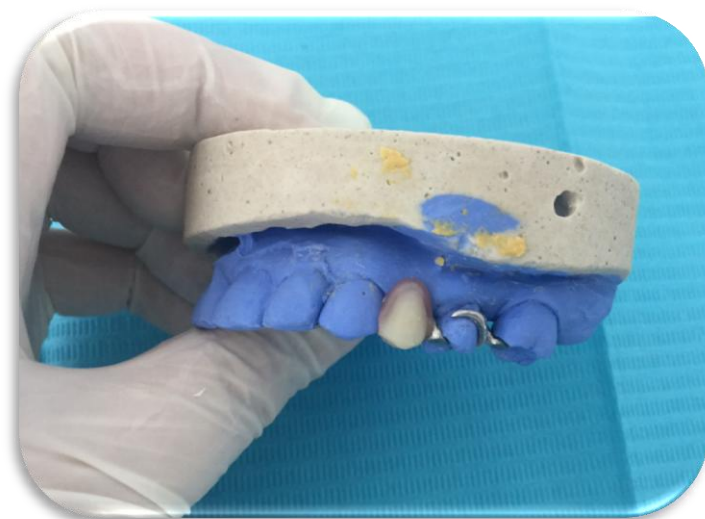
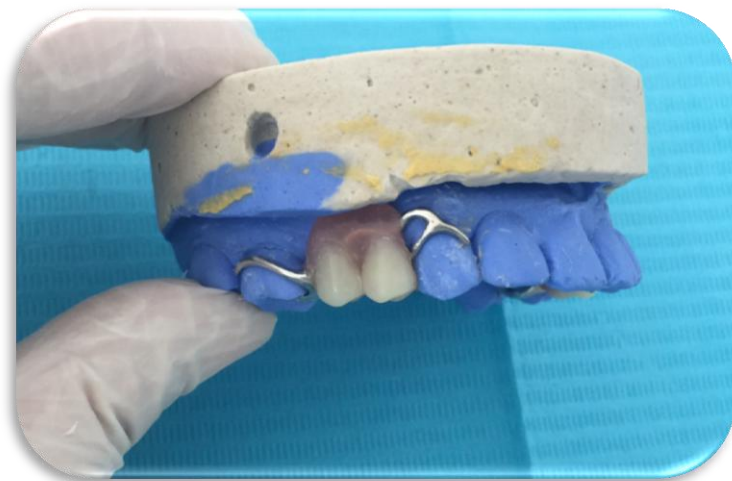
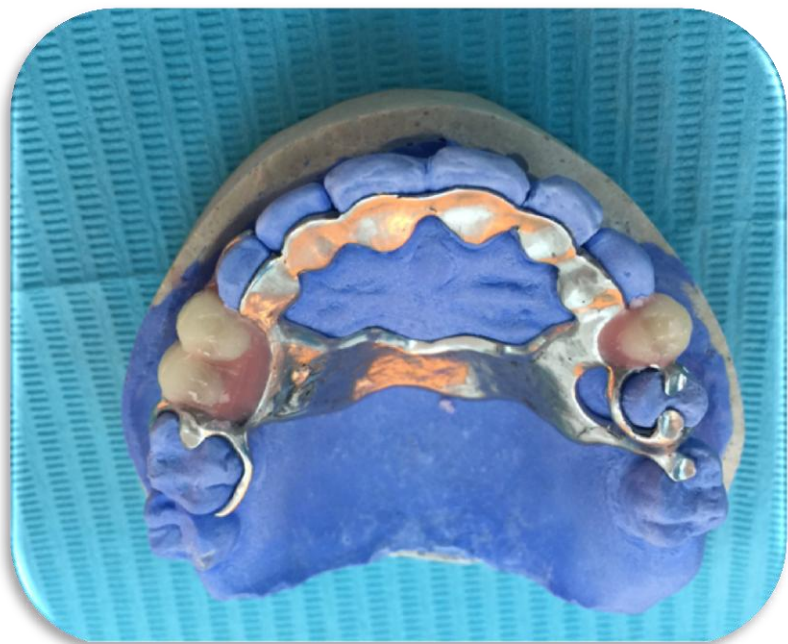

Final impression

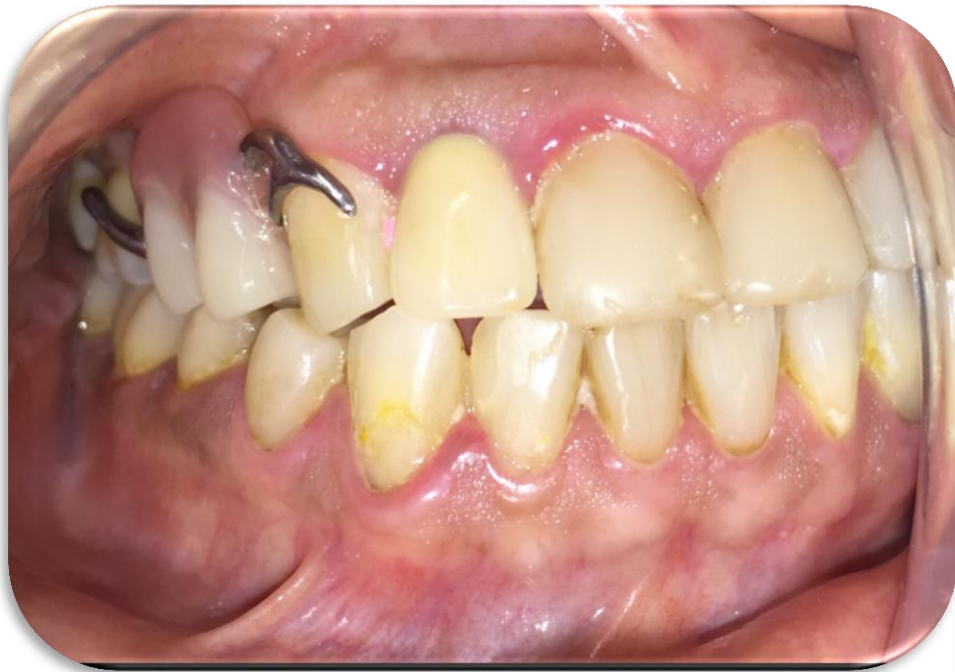
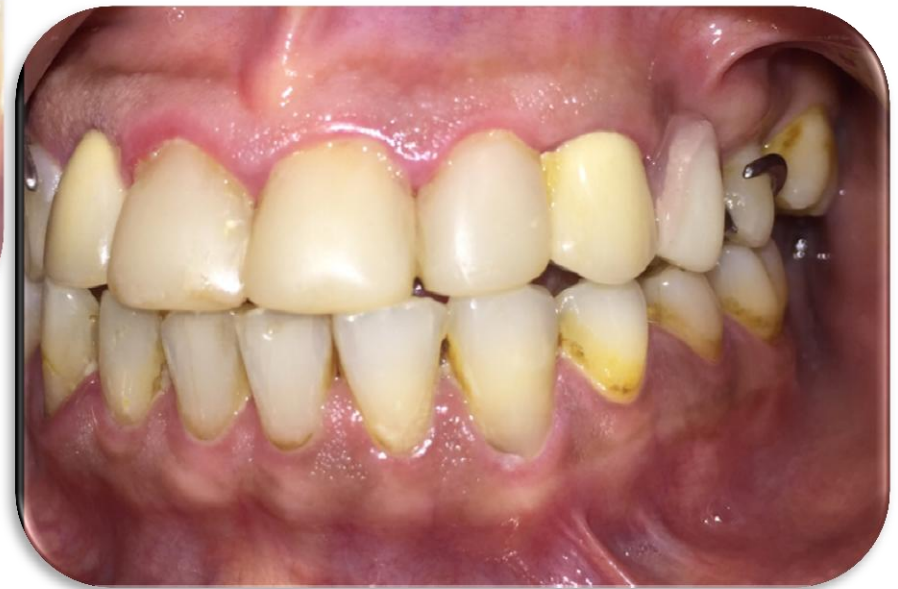
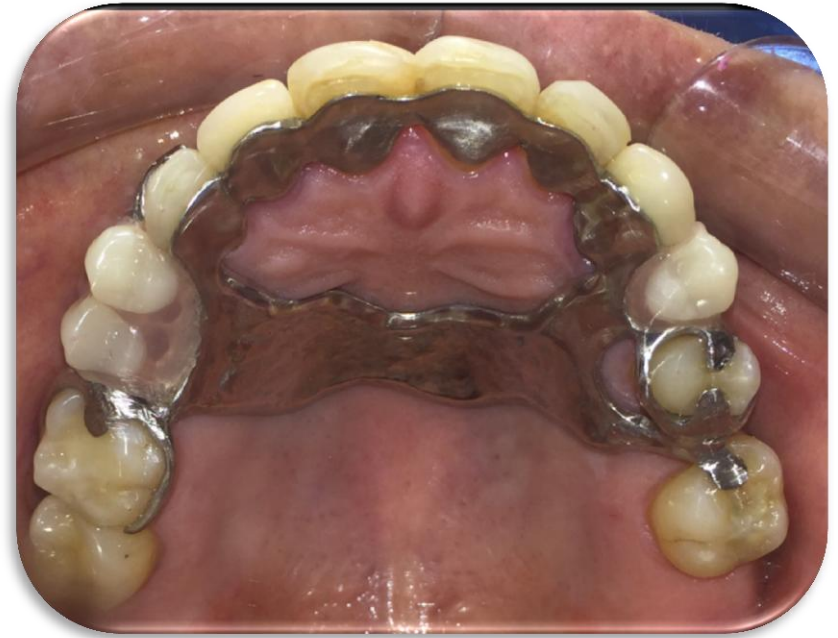

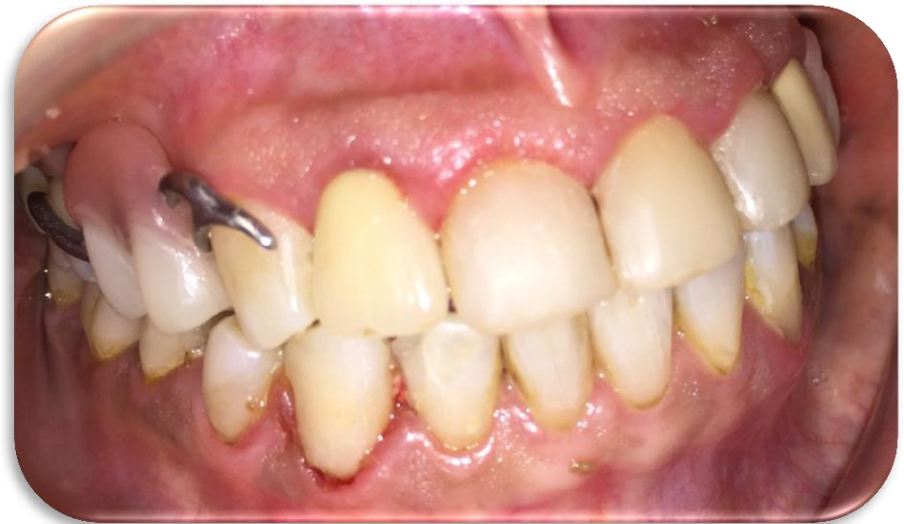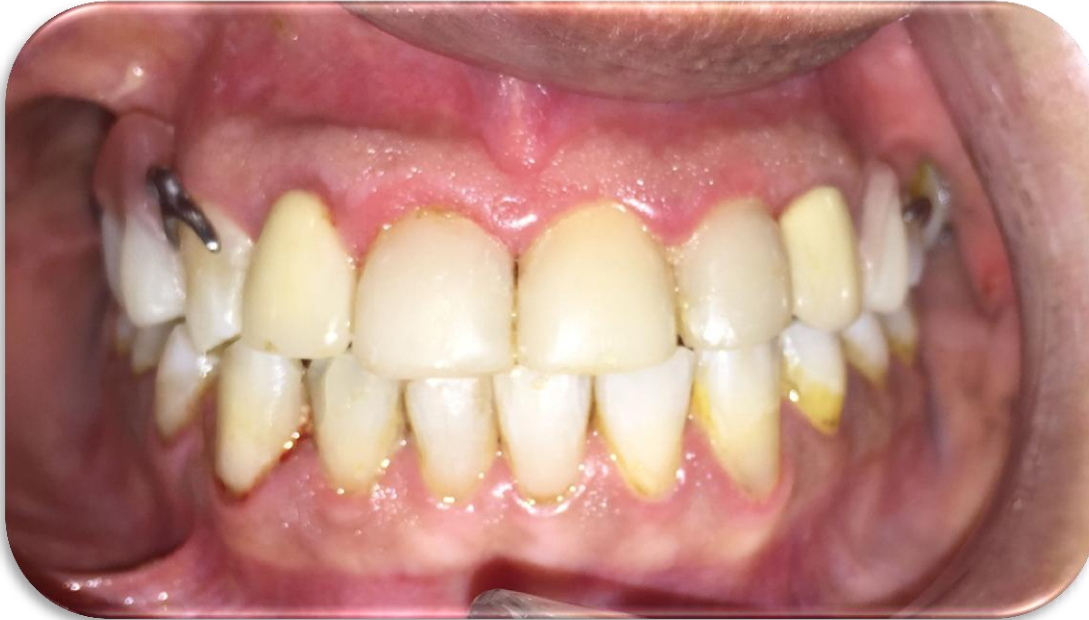Try-in



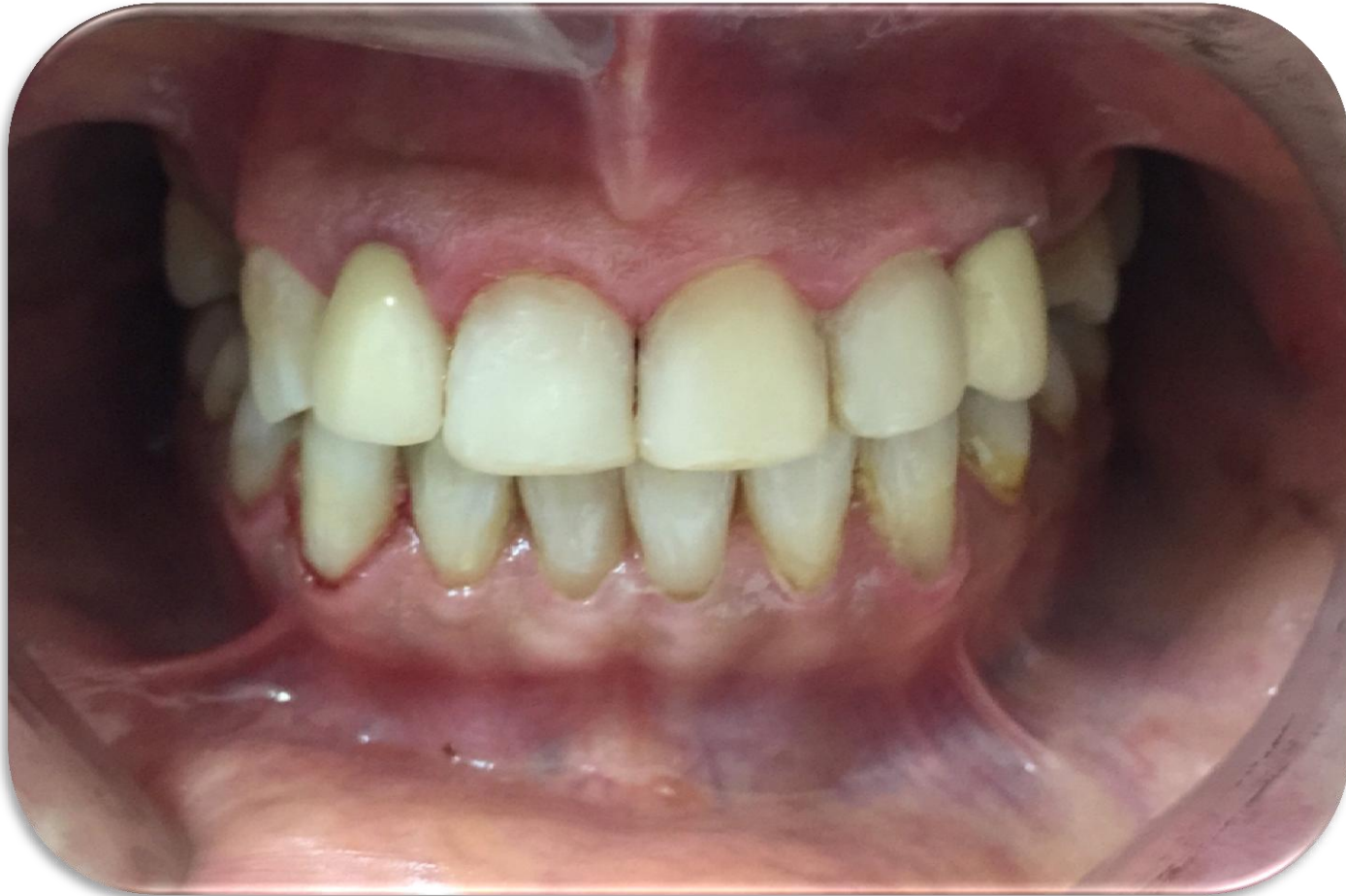Insertion



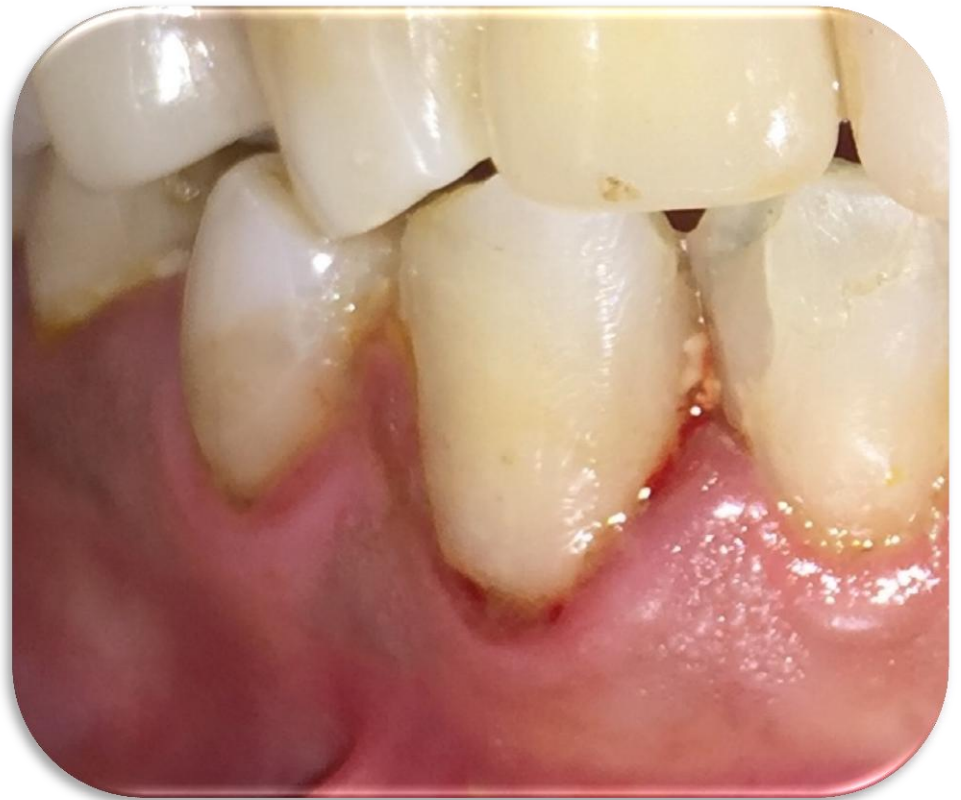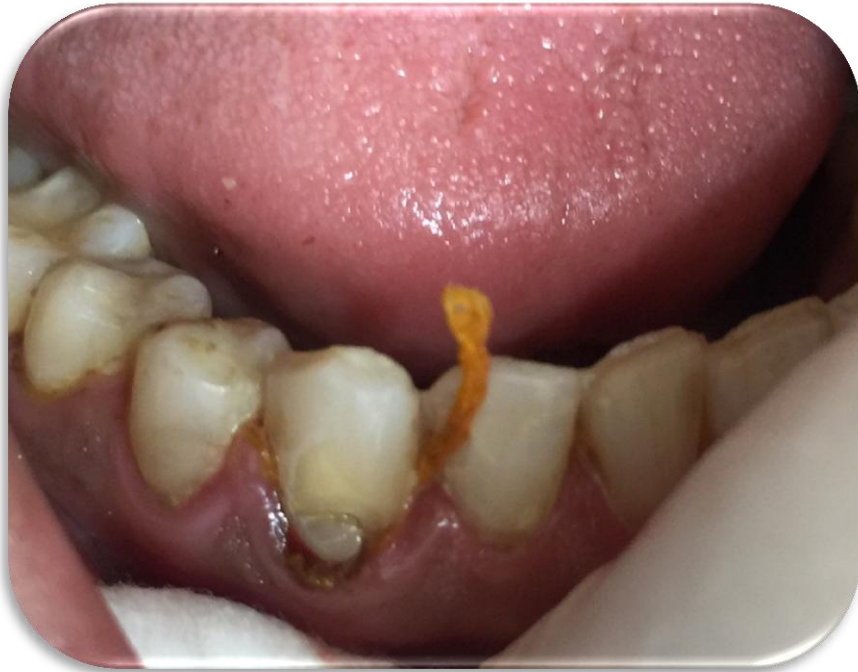Follow up after 1 week



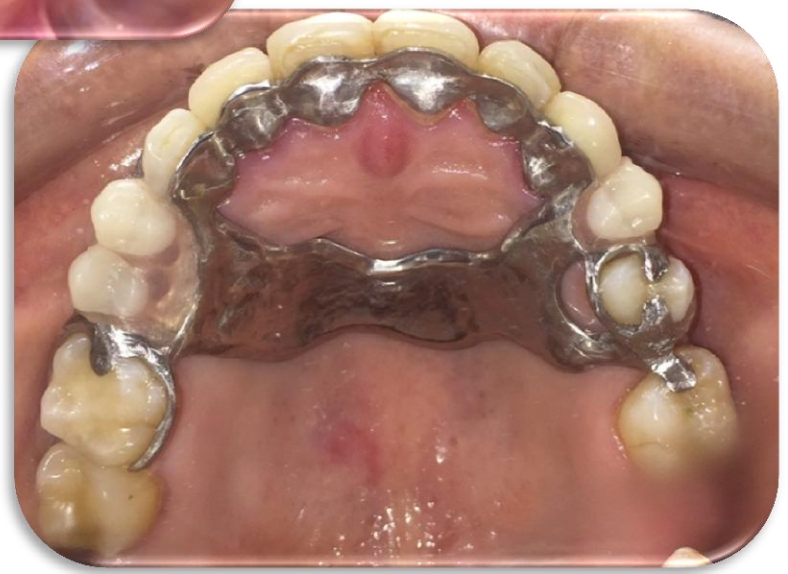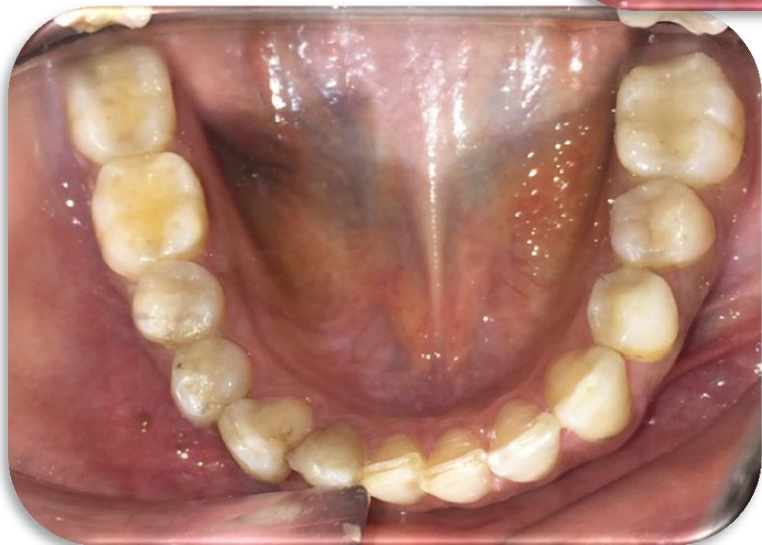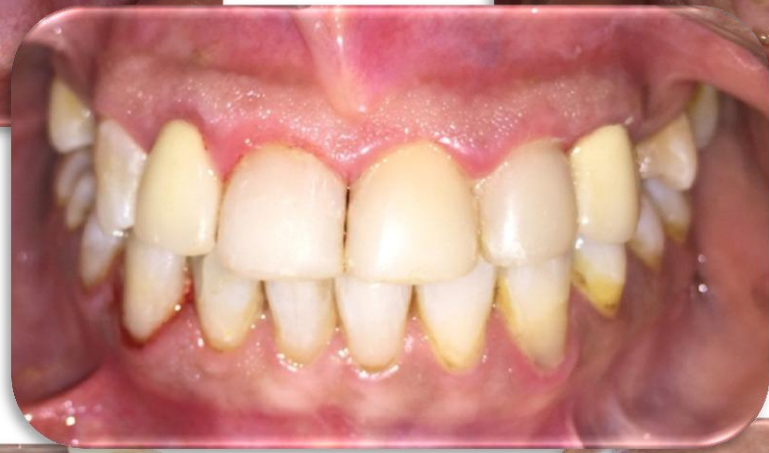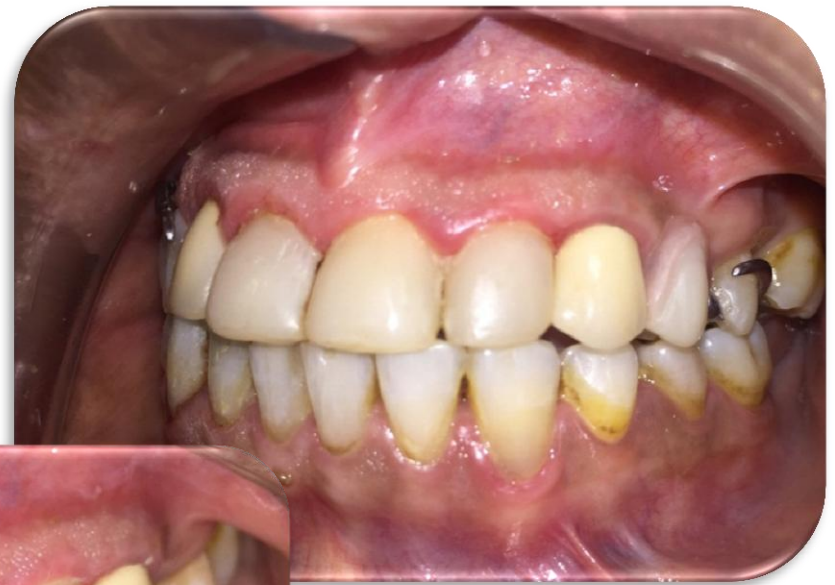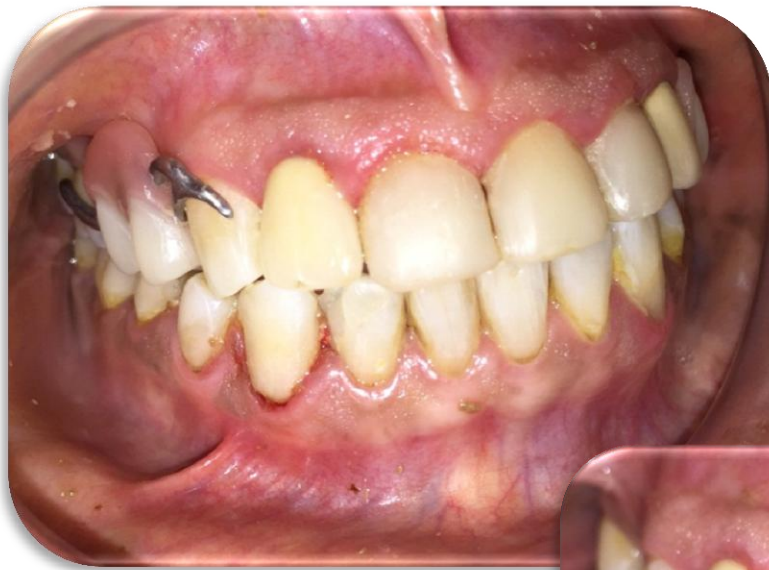Follow up after 3 week



Re _ Falling Lower 3

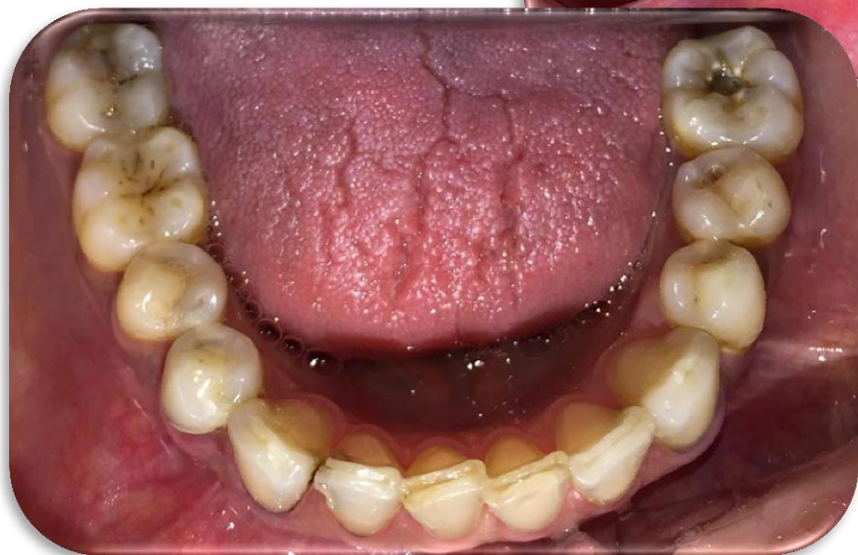


Final result



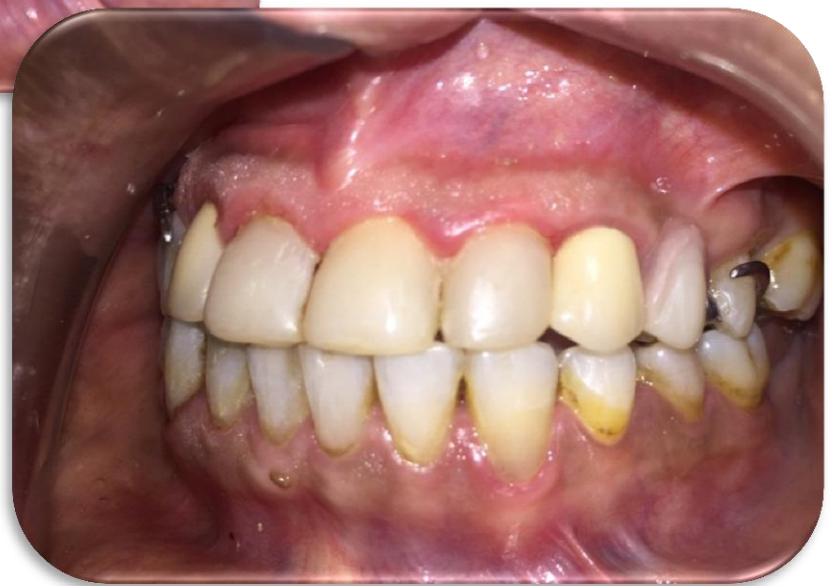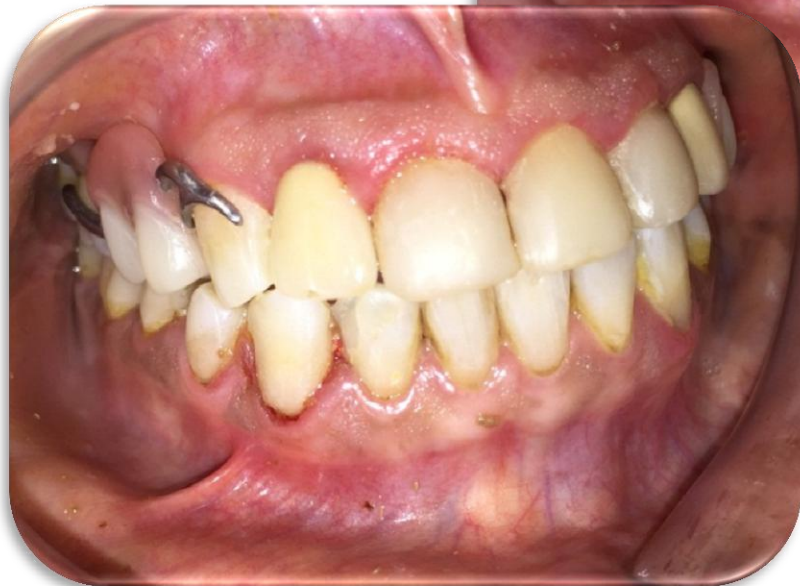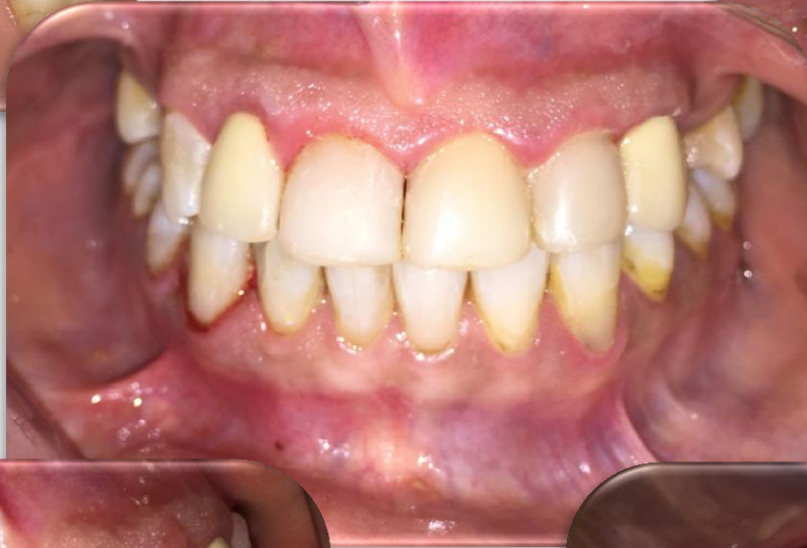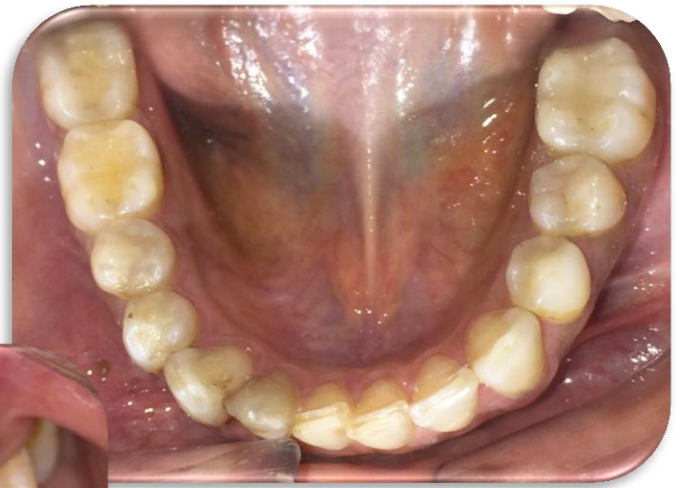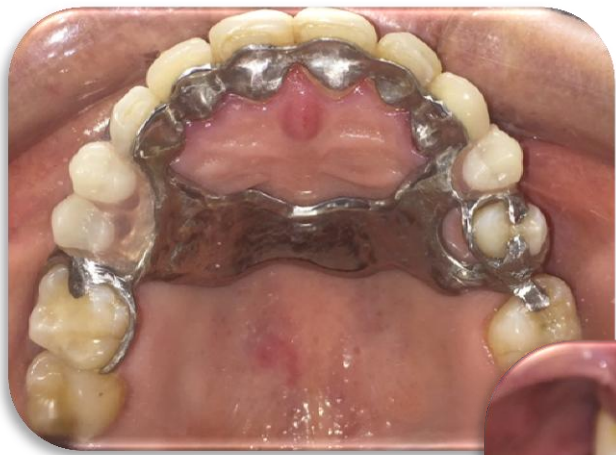before

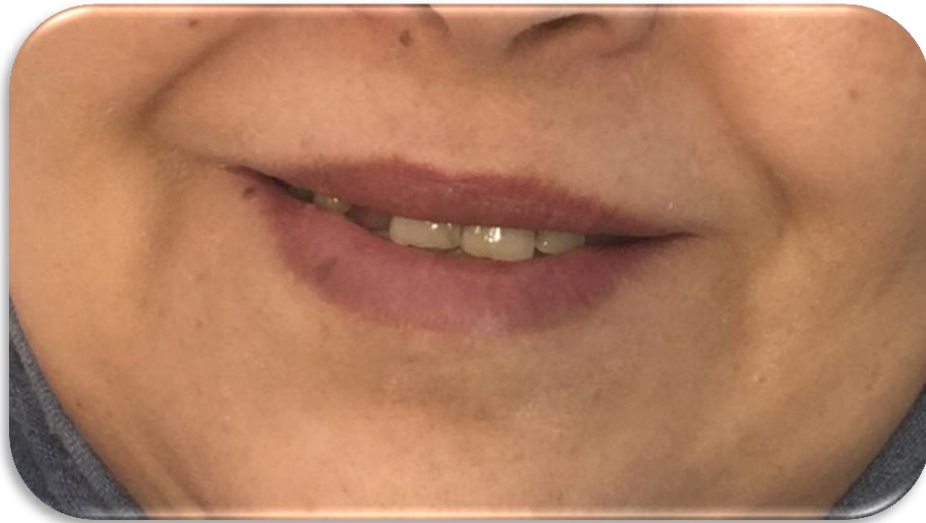



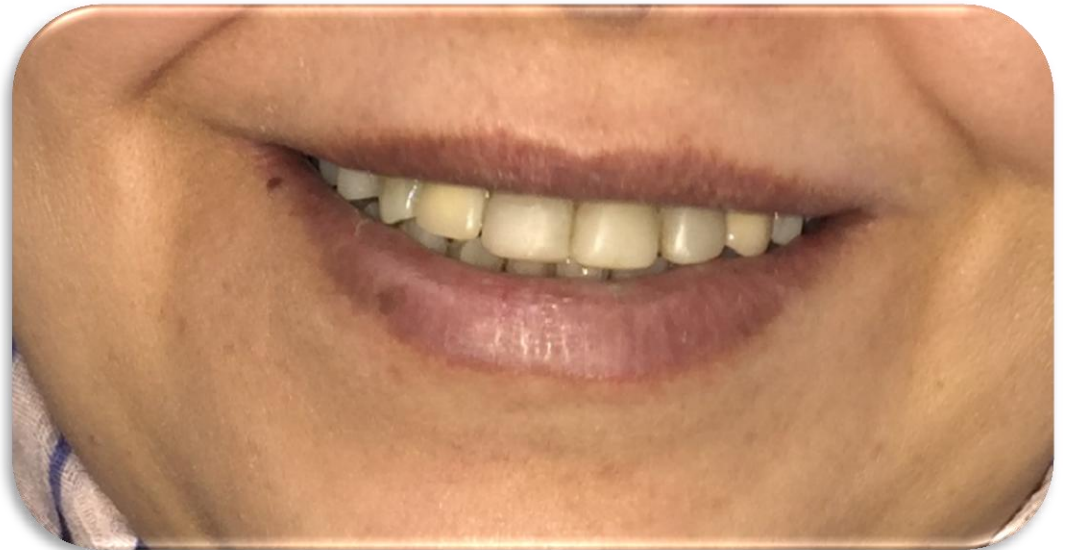AFTER



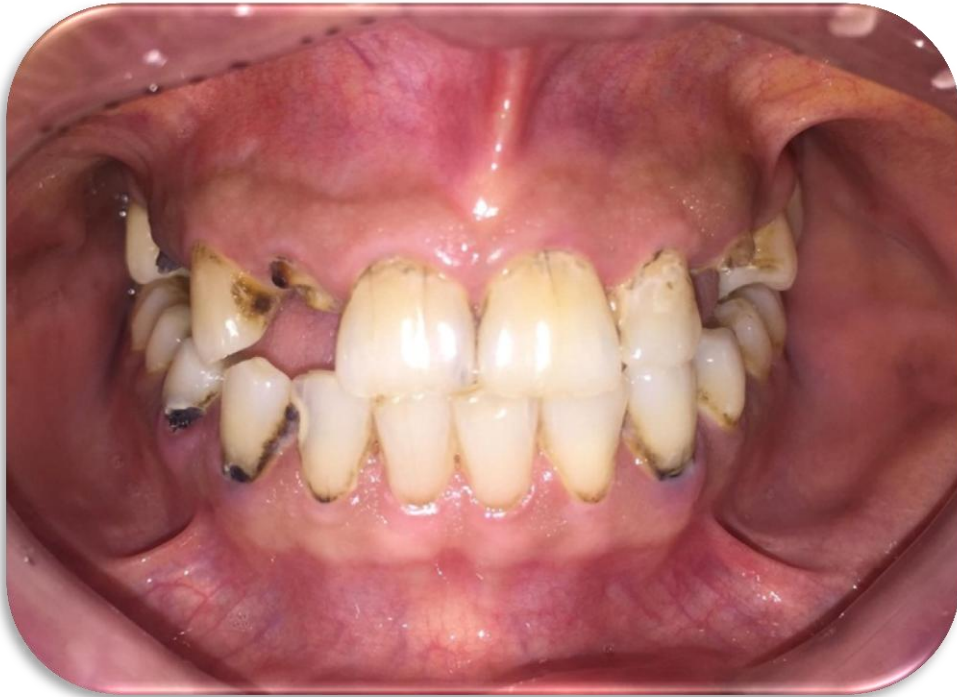



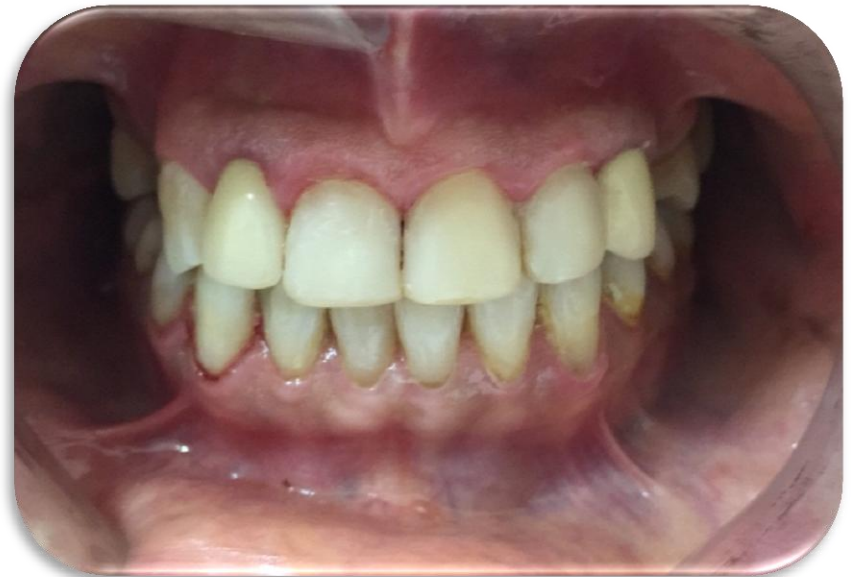**Patient
smile**



Before



AFTER



THANK YOU