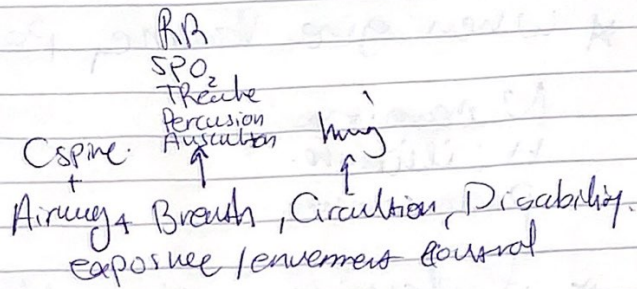


Case 5. haemorrh

① Primary Malignancy

- ABCDE + hypothermia



1. O₂
- 2.

B → X-Ray → Malignant Pneumothorax.

① needle decompression -> (Tension Pneum) * Signs.

- Chest Tube insertion
- 2nd IC Space / Mid Clavicular line
- 4th/5th space bet Mid & Ant Axillary line

1. Massive distress
2. Shock
3. going die
4. Absent breath sound, hyperresonance

A don't wait X-Ray.

② (Open Pneumothorax) → Sucking Chest wound

→ Tx
① strike 3 sided dressing

② Chest drain.

③ Massive haemothorax. →

Tx

- . IV support
- . Chest tube
- . Thoracotomy

Signs

- ① Shock
- ② Absence breath sound
- ③ Dullness.

③ 2 large Cante ③ Resuscitation w/ 2L NaCl.

④ Blood group + cross Match. → if urgent give uncross Blood twice
→ F → Post menu ⊕ ⊖ / Pre ⊖ ⊕
→ M → Cl / O₂

⑤ Fole'sy Catheter → ① Pressure.
② Shock
③ Monitoring.

⑥ Massive Blood Activate. RBC / FFP, Cryoprecipitate / Platelet.

⑦ OP room ⑧ NGT

② BP / Pulse → dropped Again ?
emergency exploratory laprotomy

③ if pt have Splenic injury? What next

Tx ① Observation → 1. Blunt injury 2. Stable pt 3. grade 1-2
4. pediatric

② Operative Salvage (Splenorrhaphy) → 1. Blunt 2. Stable.
3. Grade 1, 2 ④ unconscious pt 4 > 55y ⑤ conserve
mem/bleed
trans.
→ 1. Superficial hemostatic 3. Absorbable mesh 3-4
2. Suture Repair 4. Resectional debridement
2-3-4

③ Splenectomy → 1. hemodynamic unstable > 20 / < 90
2. extensive injury w/ bleed
3. Bleed hailes
4. Life threatening
HR SBP

④ Most important Complication.

- Overwhelming post-splenectomy infection (OPSI).

- Flulike symptoms progress rapidly to fulminant Sepsis, consumptive Coagulopathy, Bacteraemia + death w/ 12 to 48h.

- organism encapsulated Bacteria (1) Strep. pneumoniae
(2) H. influenzae Type B
(3) N. meningitides.

⑤ Tx Supportive care only / high dose 3rd gen Cephalosporin.

- Prevent immunization → elective → (2) 3-6 w. prior to surgery.
(Pneumococcal Vaccin) against 1. Strep. Pne. per ~~pre~~ surgery before
2. Hib
3. Meningitis
emergency → (2) w Post within.

* Signs of Splen

① Kehr's Sign → Referred Pain in Lt shoulder.

2 → AB

3 →

② Balance Sign → Soft Dullness on Rt side (free Blood)
→ fixed Dullness on Lt side (Clots/hematomas)

4 → Aspirin Analgesic low dose given but when Rasid give Scotten.

③ Cullen's sign → (rare).
→ Bluish discoloration around umbilicus.

* 5 areas in FAST (Focused Abdominal Sonography for Trauma)

① Pericardial

② Perihepatic

③ Perisplenic

④ Peripelvic (Pouch)

⑤ ~~perigolateral~~ Paracolic gutter.