



Cutaneous manifestations in patients with covid-19

Libyan International Medical University

Faculty of Applied Medical Science 2021-2022

Alsheima H. Alzewai -2579.3rd year medical student \

Supervised by Dr. Rema Saad



Introduction

Fever, cough, and shortness of breath were the first clinical signs of COVID 19 in Wuhan, although early reports in Italy and Spain predated the developing literature of skin involvement and there was a need to establish cutaneous involvement in patients with the disease in the literature after many observations. The clinical appearance and pathophysiological causes of these cutaneous lesions, Skin lesions appeared in 9.5% of the patients at the time of Covid-19 diagnosis or the commencement of Covid-19 respiratory symptoms, while 75.1 % appeared after the onset of Covid-19 respiratory symptoms or after laboratory detection of the condition., particularly dermatologists, Dermatologists must keep in mind that patients who visit skin clinics may be contaminated with a virus.

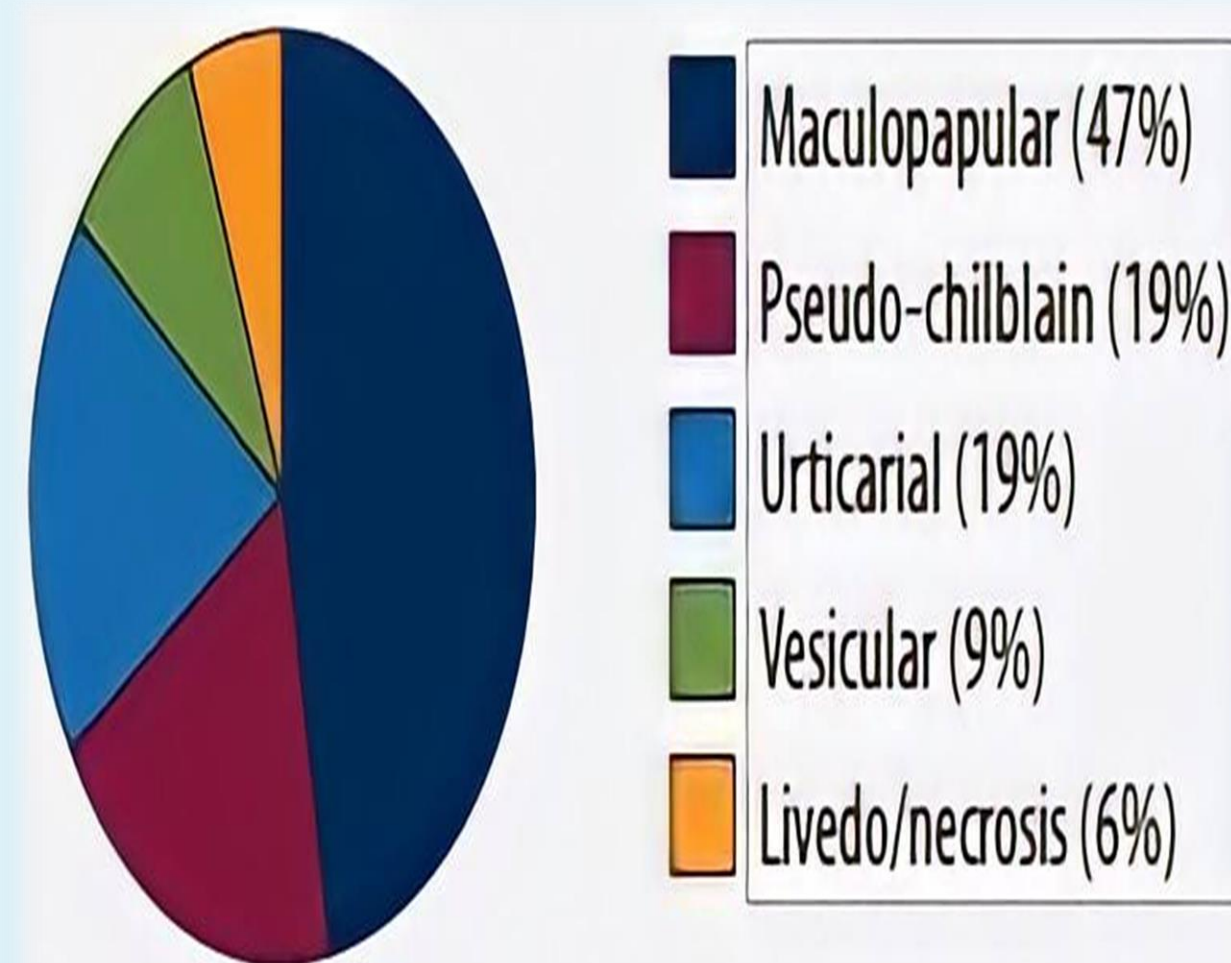


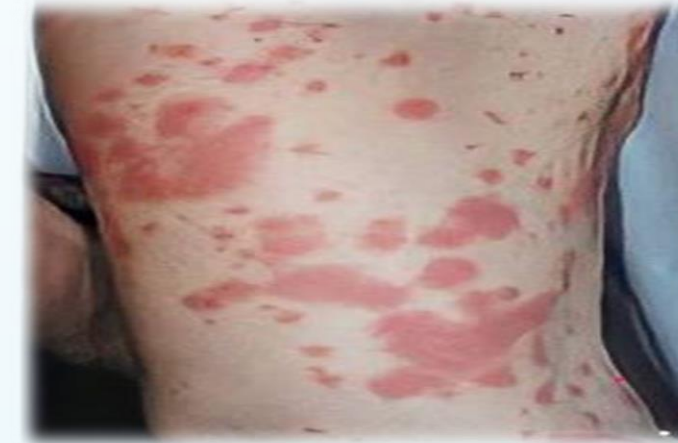Figure1: Adopted from Genovese G et al

Manifestations

Urticarial rash

Clinical features

Itching urticarial rash predominantly involving the trunk and limbs; angioedema may also rarely occur



COVID-19 severity

Intermediate severity

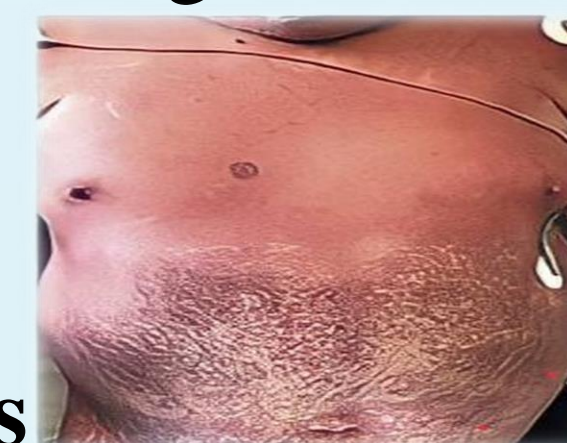Histopathological findings

Vacuolar interface dermatitis associated with superficial perivascular lymphocytic infiltrate

Confluent erythematous/maculopapular/morbilliform rash

Clinical features

Generalized ,symmetrical lesion starting from the trunk with centrifugal progression;, purpuric lesions may coexist from the onset or develop during the course of the skin eruption



COVID-19 severity

Intermediate severity

Histopathological findings

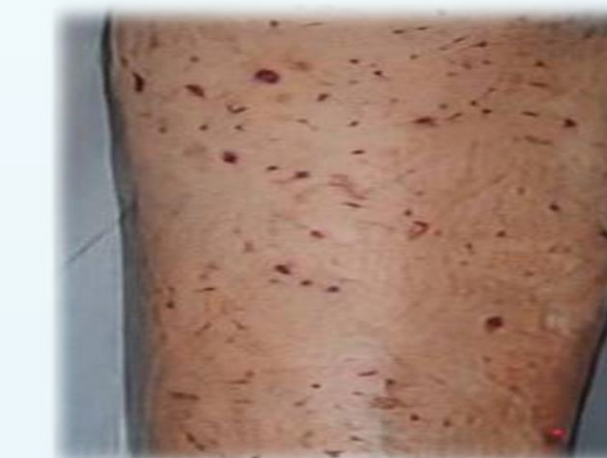Superficial perivascular lymphocytic and/or neutrophilic infiltrate

Manifestations

Papulovesicular exanthem

Clinical features

(i) Widespread polymorphic pattern consisting of small papules, vesicles and pustules of different sizes; (ii) localized pattern consisting of papulovesicular lesions, usually involving the mid chest/upper abdominal region or the back



COVID-19 severity

Intermediate severity

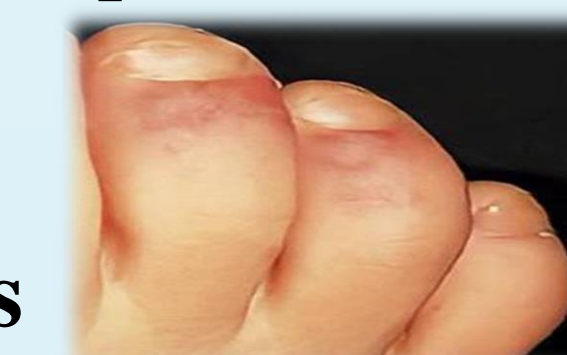Histopathological findings

Prominent acantholysis and dyskeratosis associated with unilocular intraepidermal vesicles in a suprabasal location

Chilblain-like acral pattern

Clinical features

Erythematous-violaceous patches or plaques predominantly involving the feet or, to a lesser status extent, hands. Pain/burning sensation as well as pruritus were commonly reported symptoms



Pain/burning sensation as well as pruritus were commonly reported symptoms

COVID-19 severity

Asymptomatic status

Histopathological findings

Perivascular and periadnexal dermal lymphocytic infiltrates

Conclusion

Unique to many other symptoms of COVID-19, Many skin lesions may appear as a result of COVID-19. its cutaneous manifestations have been found in people of all age groups, including. maculopapular and. Chilblainlike , urticarial. and vesicular, and ivedoid , and Papulovesicular exanthem

References

1. Genovese G, Moltrasio C, Berti E, Marzano A. Skin Manifestations Associated with COVID-19: Current Knowledge and Future Perspectives. *Dermatology*. 2020;237(1):1-12. doi:10.1159/000512932
2. Problems of the COVID-19 pandemic in dermatology. *Digital Doctor*. 2021;2(2). doi:10.47407/dd2021.2.0026
3. Marzano A, Cassano N, Genovese G, Moltrasio C, Vena G. Cutaneous manifestations in patients with COVID-19: a preliminary review of an emerging issue. *British Journal of Dermatology*. 2020;183(3):431-442. doi:10.1111/bjd.19264
4. Hoenig L. Update on the cutaneous manifestations of COVID-19. *Clin Dermatol*. 2020;38(4):507. doi:10.1016/j.clindermatol.2020.04.016