



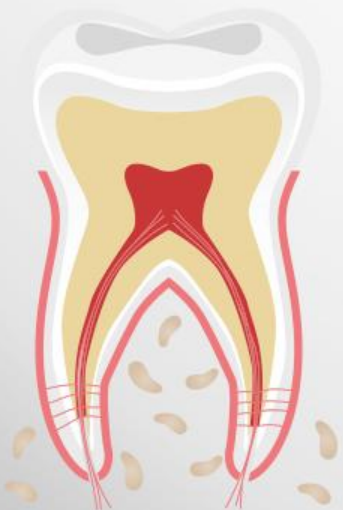**Libyan International Medical University**



# Comprehensive case presentation

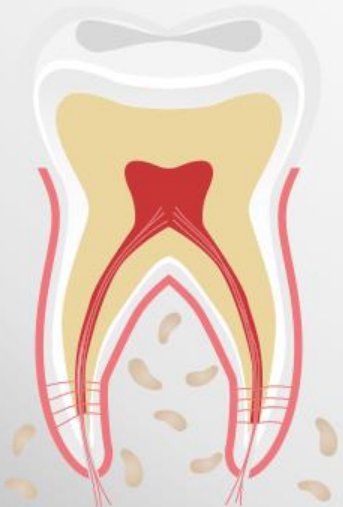**Presented by:** Sahar Khaled Althanie

**Roll No. 934**



This work was achieved by the student: Sahar Khaled Althanie under the supervision of dental teaching staff at Libyan International Medical University:

- Dr. Rafeeq M. Al Kuafi
- Dr. Abdelmonem Abdelnabi
- Dr. Ali Busnaina
- Dr. khadiga Alfallah
- Dr. Amal Alawami
- Dr. Noha Alkadiky
- Dr. Anas Alharati
- Dr. Abdasalam Alhadad
- Dr. Marwa Elsharkasi



# PERSONAL DATA



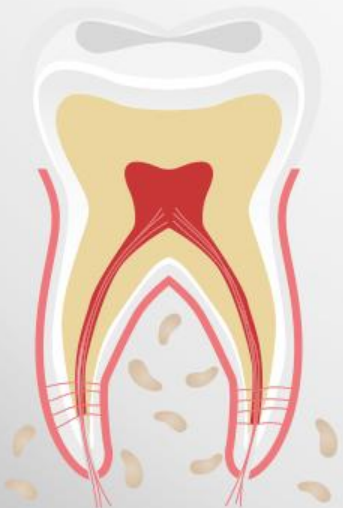Patient name :W.M.A  
D.O.B:1977  
Gender : F  
Occupation: lawyer  
Address: boatny  
Nationality: Libyan



**Chief complain** :Patient came to limu clinic complain from pain in upper front tooth since 1 week

## History of chief complain:

Sever localized throbbing spontaneous intermitted pain, exaggerated by eating relived by ketofane (1tablet daily)for 6 hours , interfere with sleeping radiated to ear &associated with headache ,tooth history of filling 1y without any symptoms (1visit), pain was mild past 2month become more sever from 1w.



**MEDICAL HISTORY** : Fit & well  
**Systematic review** : Nothing abnormal detected



## **DENTAL HISTORY**

**\*brushes her teeth ones morning with hard brush , History of fillings tooth , root canal treatment,extraction.**

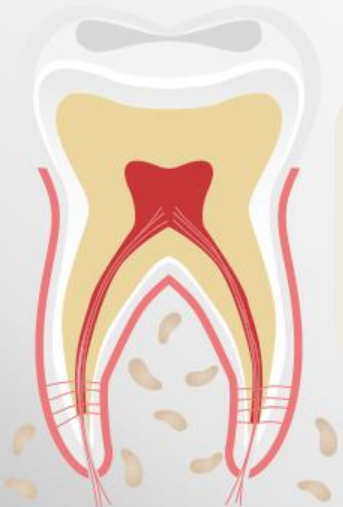**\*No oral harmful habits**

**Patient attitude for dentist (poor)**

**Patient irregular**

**Family history** :no finding

**Social history** : Married and a mother of 4 child



# EXTRA ORAL-EXAMINATION

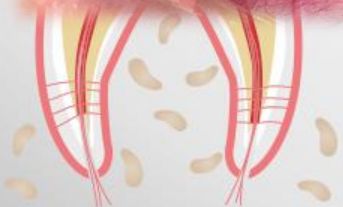
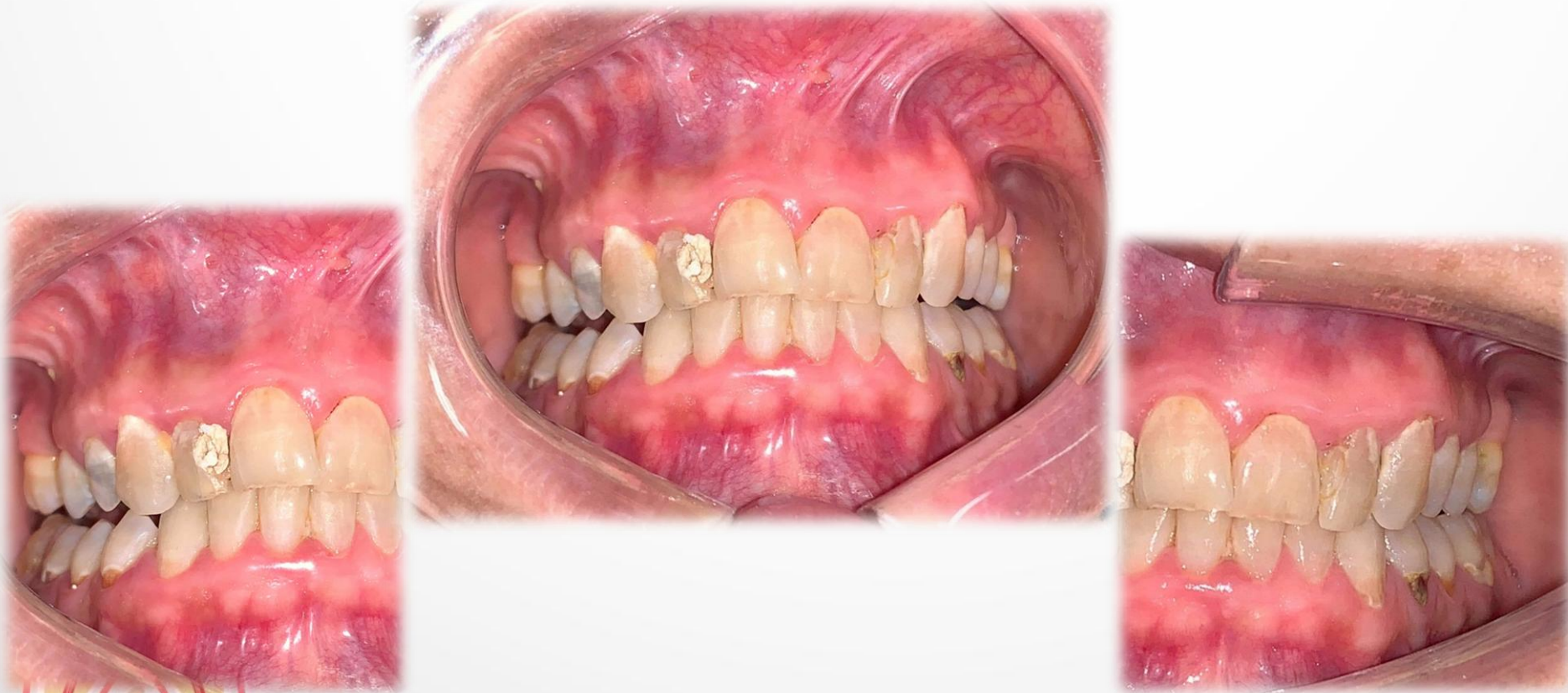Facial symmetry

TMJ: average mouth opening and  
movement, no crepitation no  
tenderness

Cervical LN : not palpable



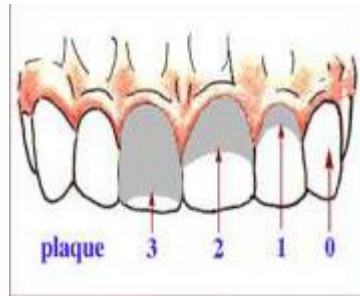
# Intra ORAL EXAMINATION: oral mucosa normal except tongue tie



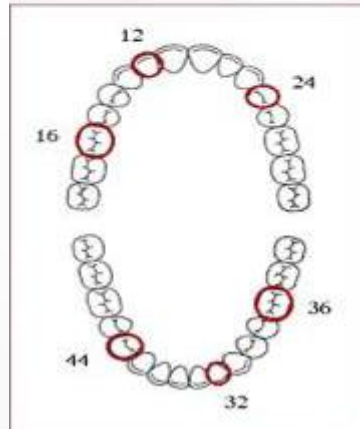


# DENTAL Chart

16	11	26
-	2	-
3	2	3
46	31	36



16	11	26
-	0	-
2	1	2
46	31	36



**Plaque Index**

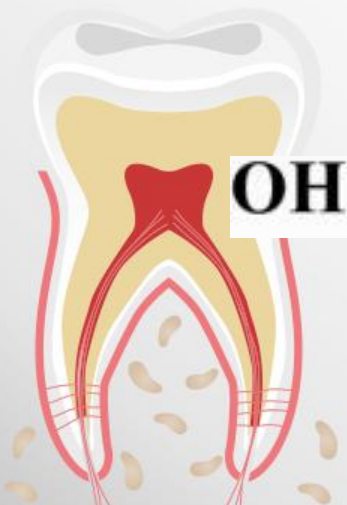$$10/6=1.66$$

**Calculus Index**

$$5/6=0.83$$

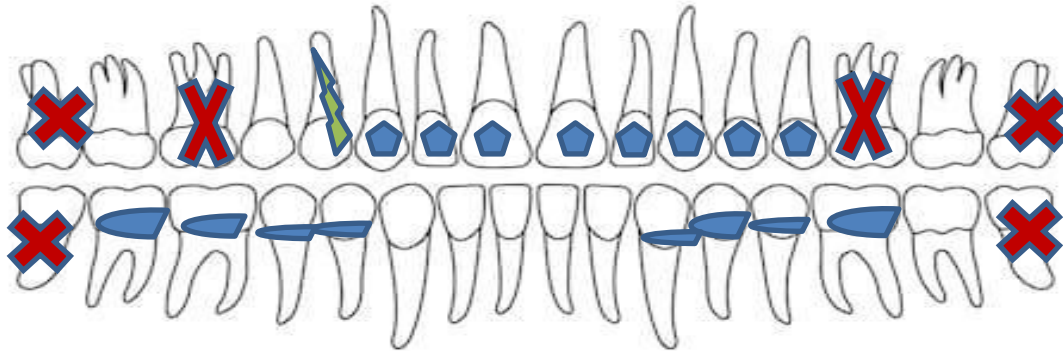
**OHI-S=**

$$1,66+1,16=2,49 \text{ (Fair)}$$





# DENTALChart



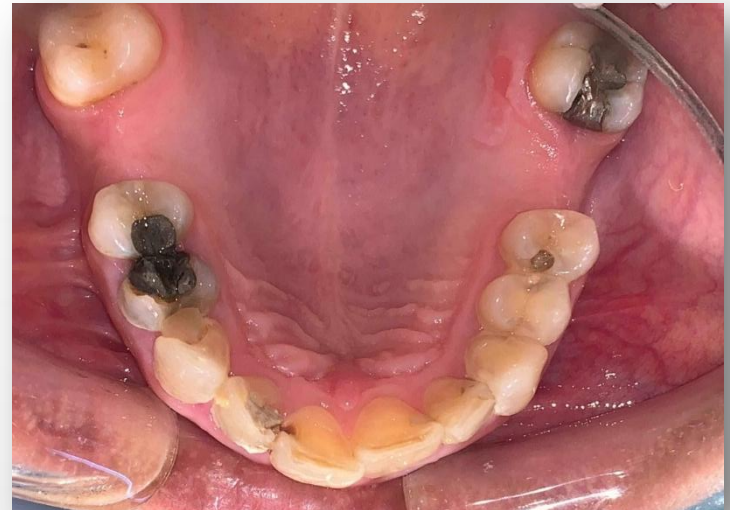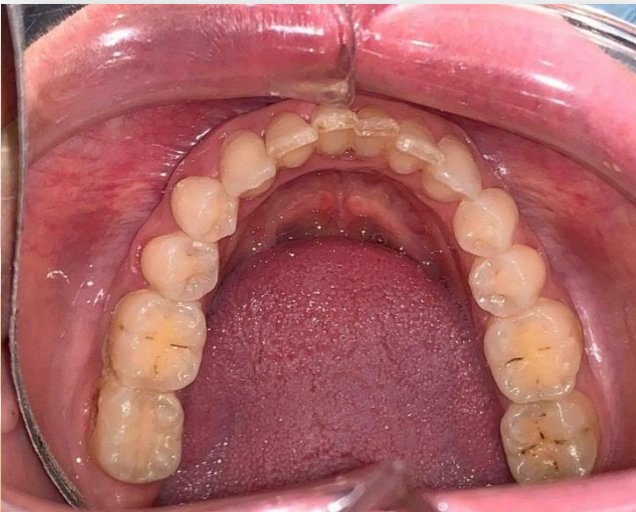shutterstock.com • 401714056

Missing: **X**

Decayed: **■**

DMFT=19

**Attrision**



# Periodontal Chart

Normal gingival size except lower anterior teeth & upper anterior (soft & edematous) with reddish pink color, scalloped round marginal, and blunt IDP and patient complaining from bleeding on brushing

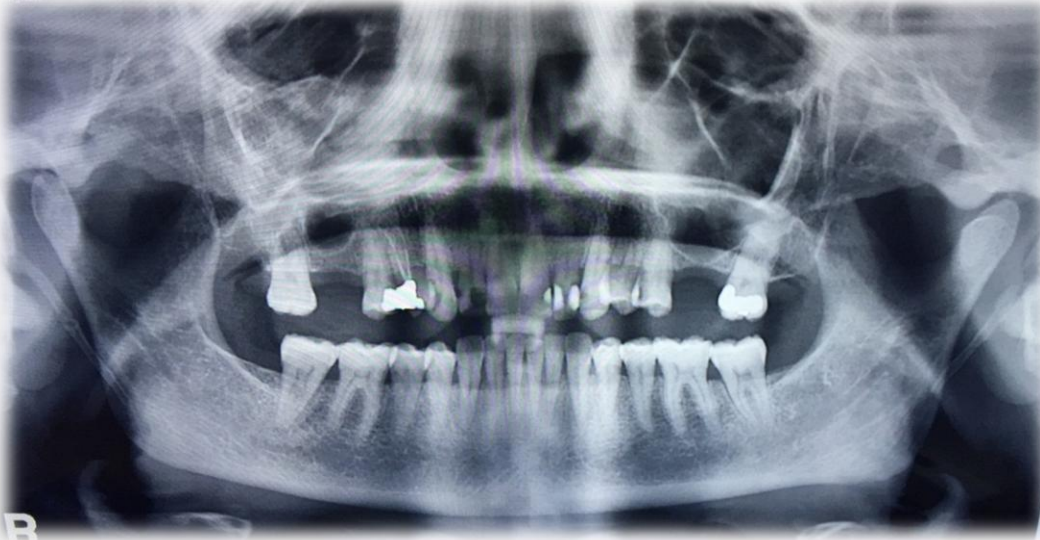Pocket depth within normal range for all teeth except lower left 7

Loss attachment absent in all teeth except lower right and left posterior 7654 | 3456 From 2 to 4

There is bleeding on probing in all sextants ..there is no mobility

**Diagnosis: Generalized Mild to Moderate periodontitis**

# ORTHO PANTOMOGRAPH

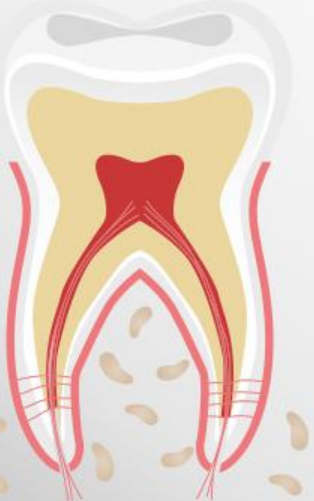

## Radiograph Examination

All teeth present except

UL6/UR6

Mild to moderate  
horizontal bone loss  
level at middle third  
root (Lower and upper  
anterior)



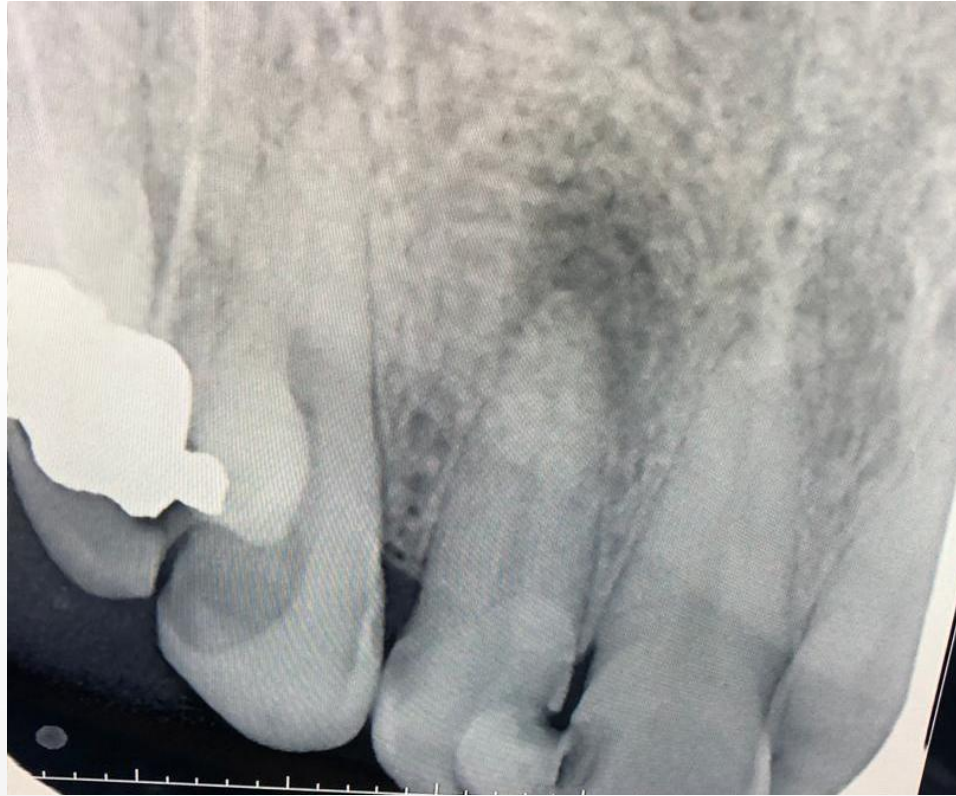**The patient is unidirectional group function occlusion**

**The incisor relationship : class I**

**Class III according to Kennedy classification, modification I**



# PERIAPICAL RADIOGRAPH





# FINAL DIAGNOSIS

**Acute exacerbation chronic periapical periodontitis  
UR2**

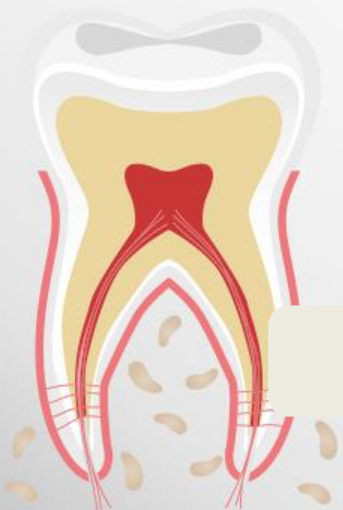**Generalized Mild to Moderate chronic periodontitis**

**CHRONIC PERIAPICAL PERIODONTITIS  
(UL2/3) (UR3)**

**Dental DECAY**

5 1	15 7
<hr/>	
7654	3456

**MISSING TEETH (UR6/UL6)**



## Investigations :

1. periapical Radiograph of **UL2**
2. Orthopantomogram Radiograph





# TREATMENT PLANE

## Preliminary \ Emergency Phase

### Pulp exacerbation UL2

#### Phase I

OHI, patient modification ,Scaling ,root planning , dite sheet and pit fissure sealant, fluoride application

#### Phase II

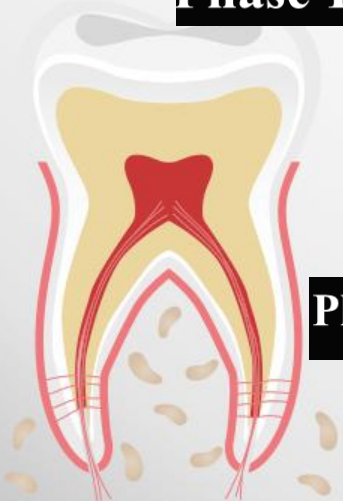No indication for surgery

#### Phase III

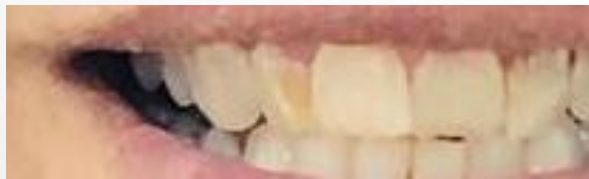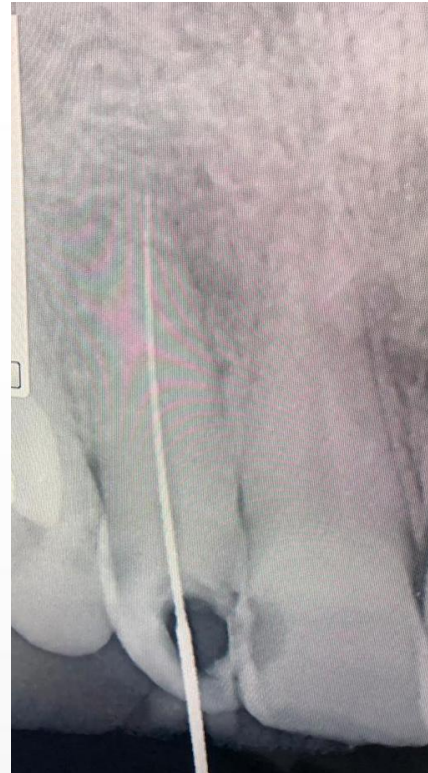
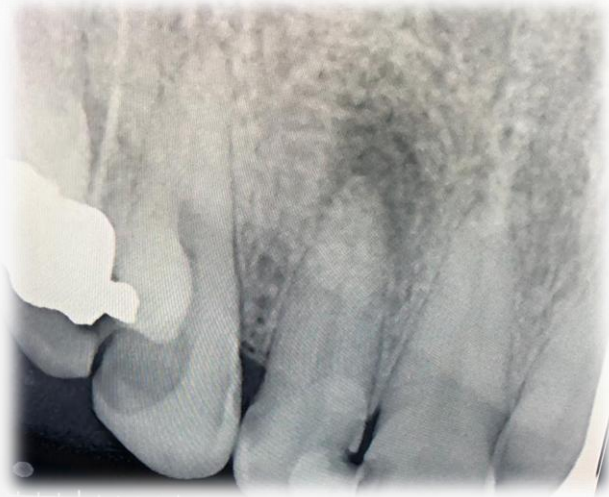RCT(UR5/3/2/)(UL/2/3/5) ,  
Restoration(LR7/6/5/4)(LL6/5/4/3)(UR1/UL1) ,  
Retreatment(UR4) Replacement missing teeth  
(UL6-UR6)

#### Phase IV Maintenance

Follow up 1W , 1M



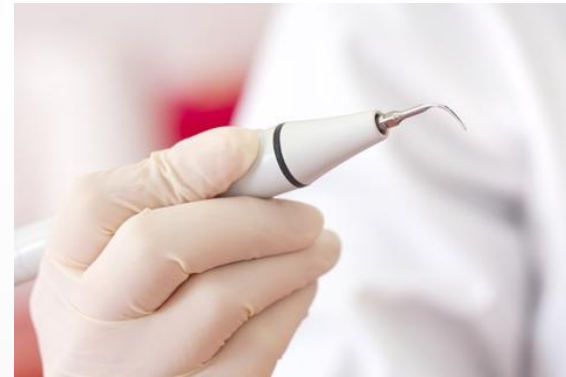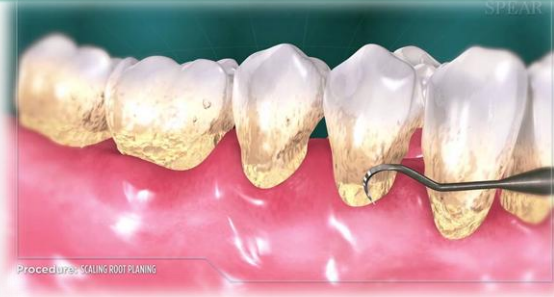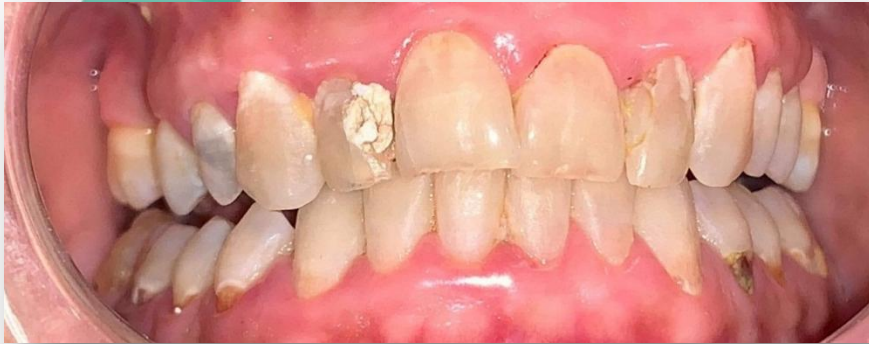# Emergency Phases:



# Phase I

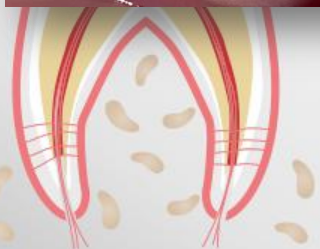
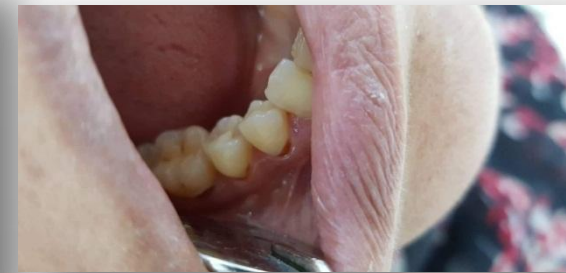
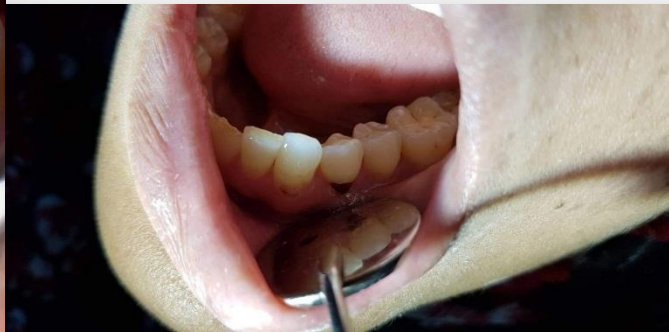
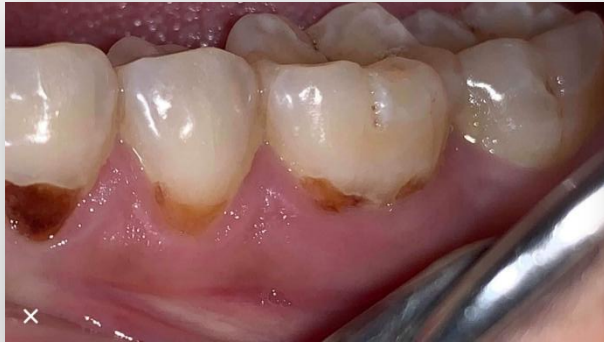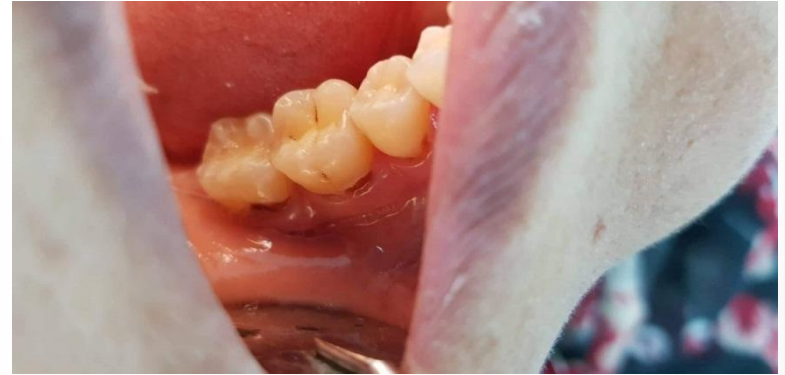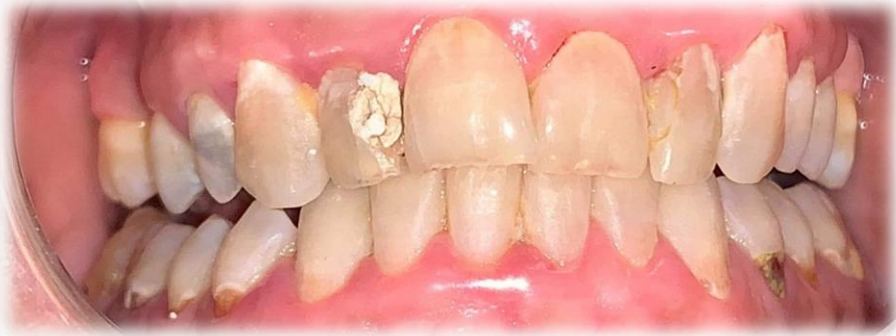# OHI, SCALING & FLURIDE APPLICATION

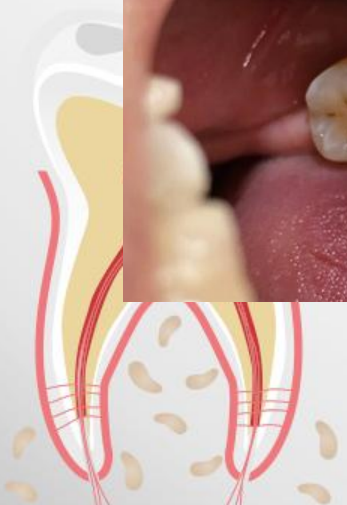
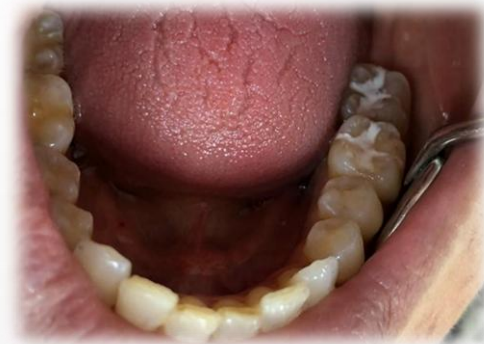
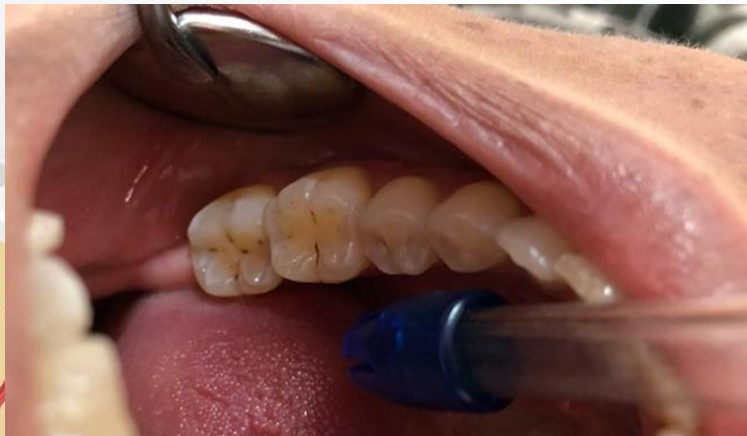
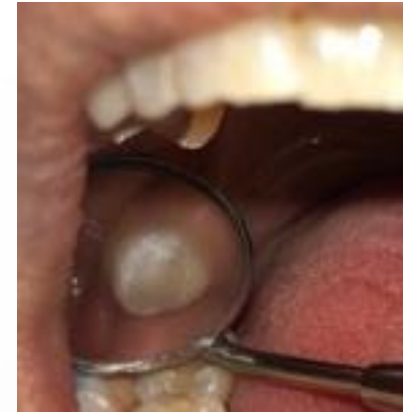
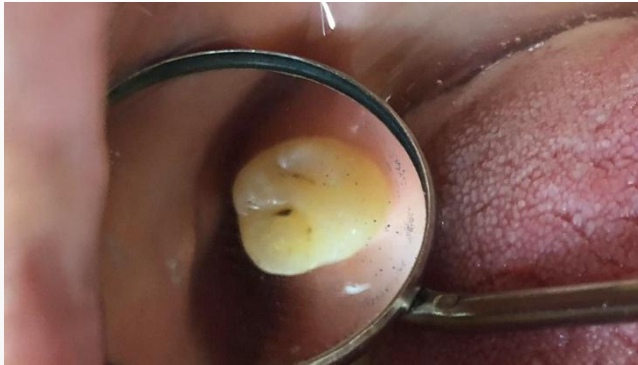
# RE-EVALUATION



# PIT & FISSURE

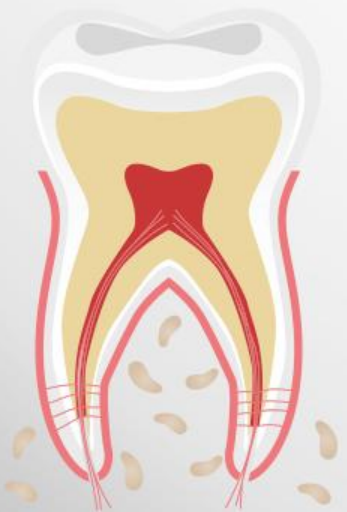

# DIET SHEET

Patient Name: [Redacted] Gender: M/F Date of Birth: 1977  
 Occupation: [Redacted] Address: [Redacted]

نوع الوجبة	الأكلات والمشروبات	الوقت	اليوم
مطبوخ	قهوة بالكافيين / بنكهة	8:30	الاحد
غداء	بندوشن لون ميموسه + حليب + زبادي كوب ماء بكرينه / سلطه / آوب حليب تفاح	11:30 2:30	
حشاش	فستق قهوة + موزون لوز واحد شويطه + بيشه مقلبي كوب ماء	5:00 7:00	
مطبوخ	توست بالبوربون + حليب شامبين لطا حقه لوز ماء	8:00 12:30	
غداء	طبيقة زبادي سلطه + بيشه شامبين لوز + كسولان	3:00 5:00	
حشاش	بندوشن قهوة + مشامبين (مشامبين قهوة)	8:30	
مطبوخ	حليب مشامبين بنكهة	9:30	الثلاثاء
غداء	لوز + حليب + حليب تفاح رز اصفر + لوز + سلطه	12:00 2:30	
حشاش	قهوة + بنكهة توست بالجبنة + زبادي كوب ماء	7:00 4:00	

\* خصل الدسناز مع حصة في الصباح

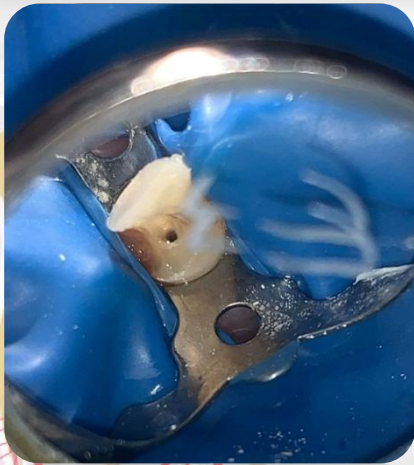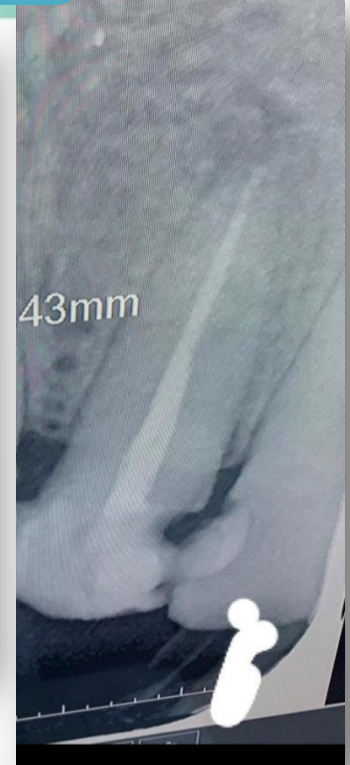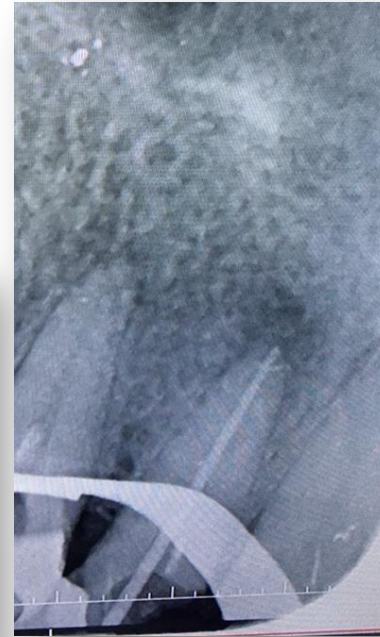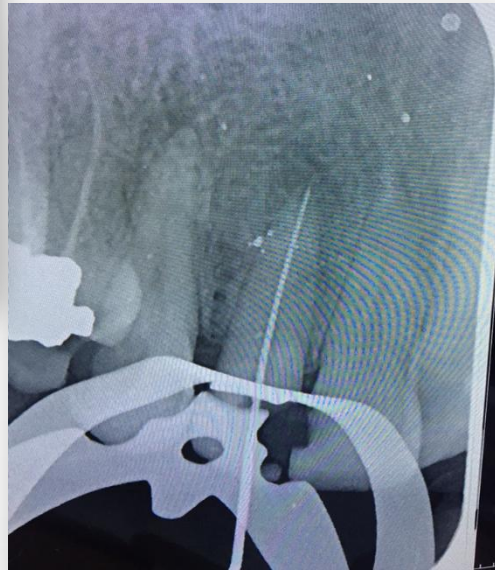



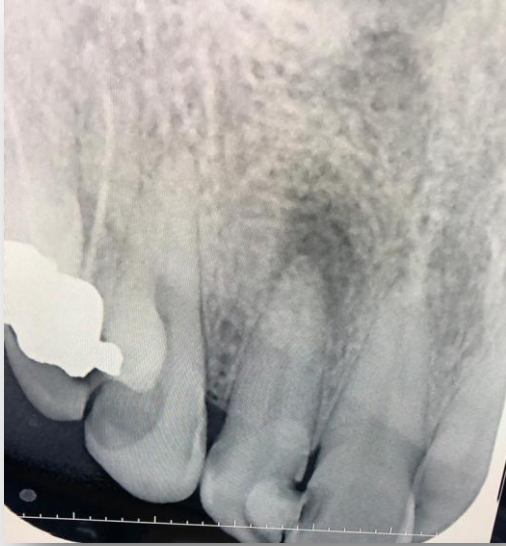
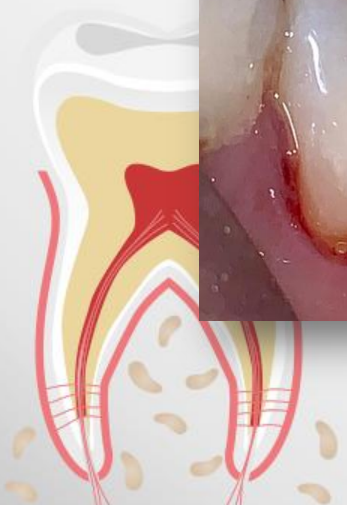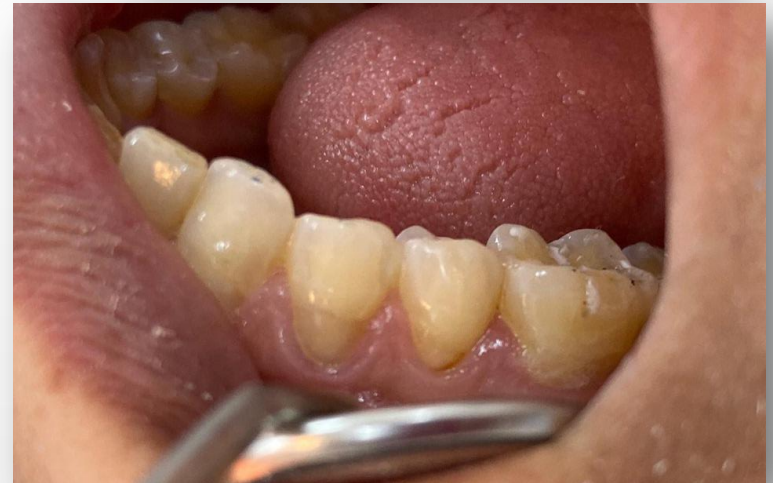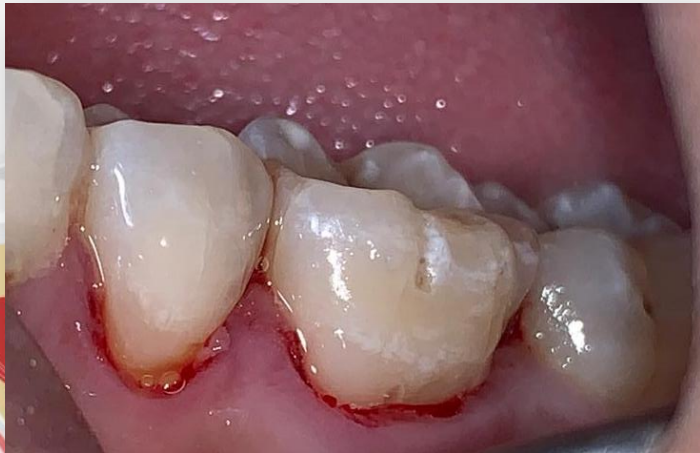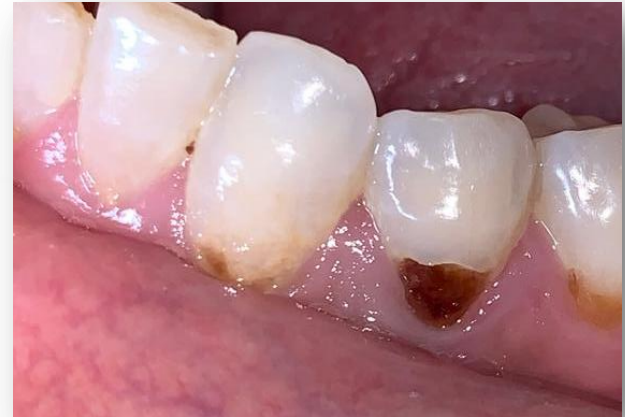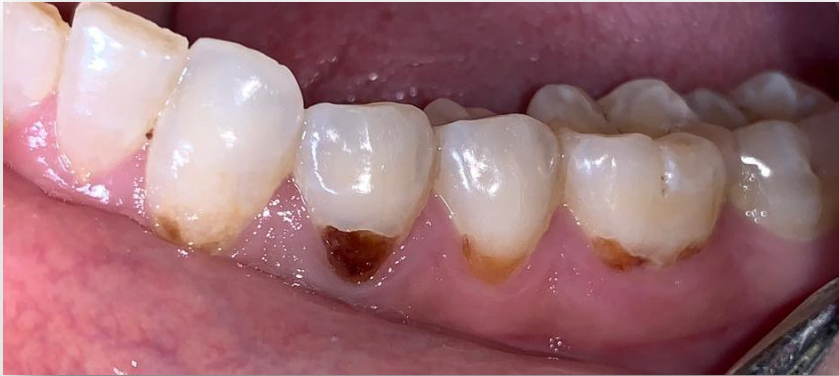# Phase III



# RCT UR2

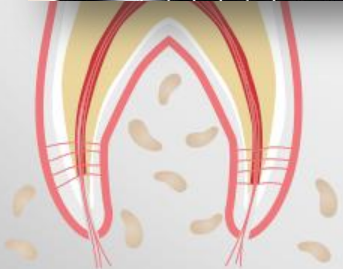
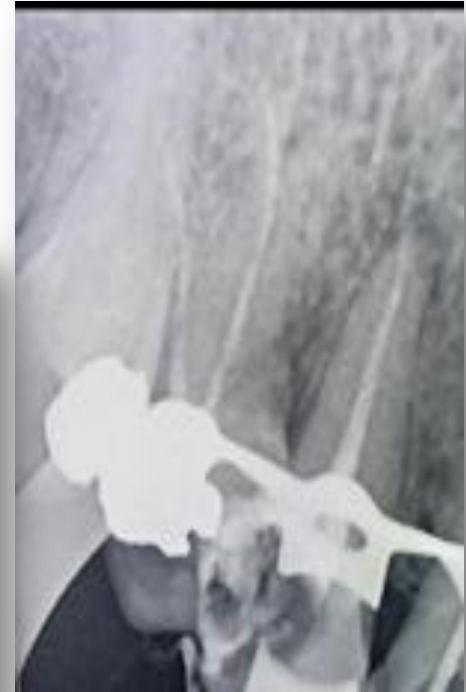
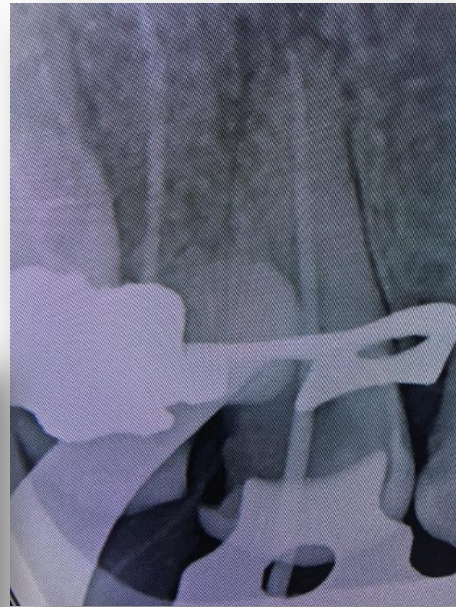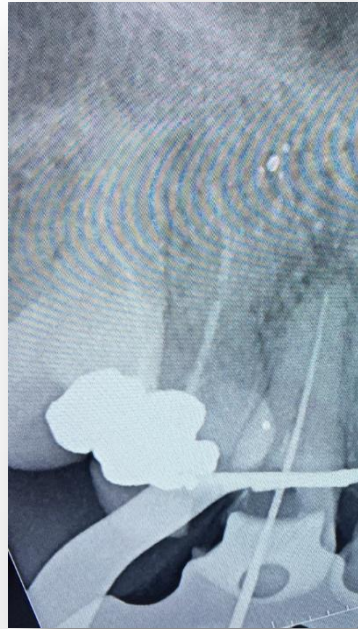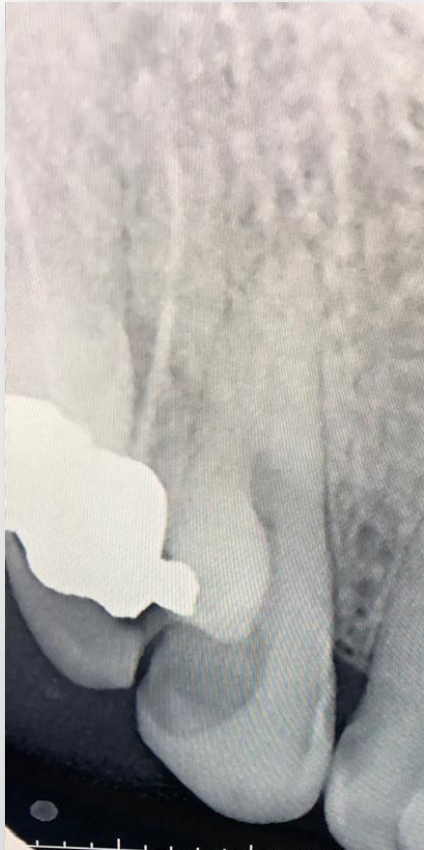# FILLING LL6/5/4/3

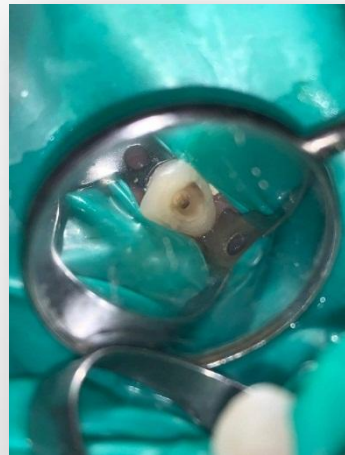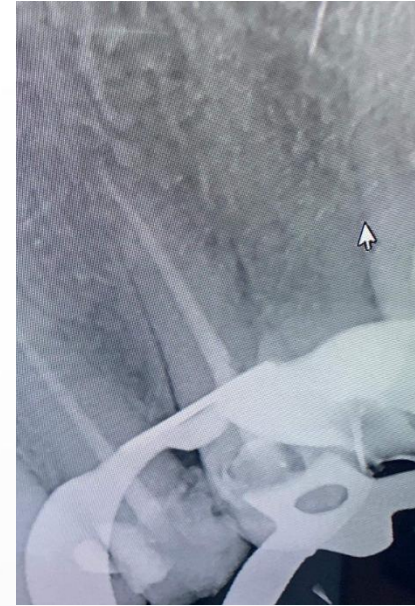


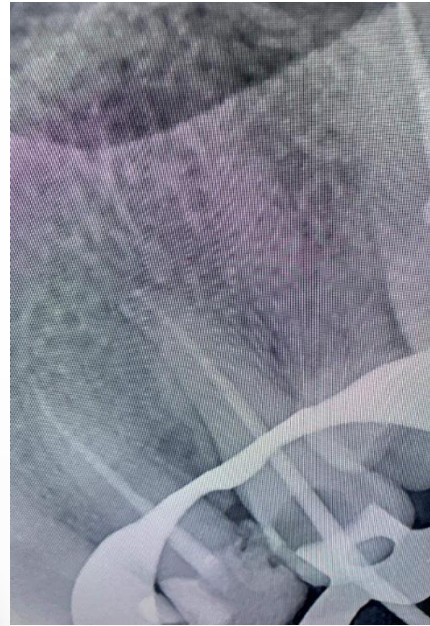
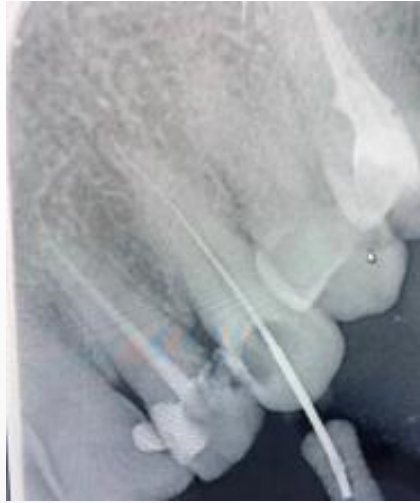
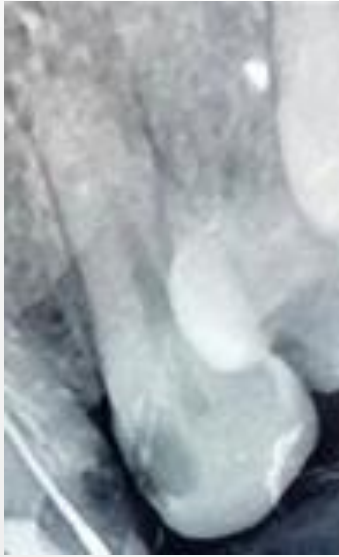# RCT UR3

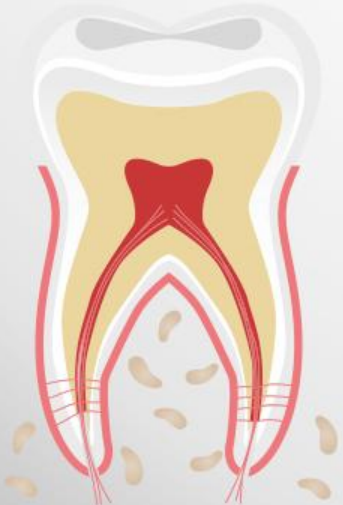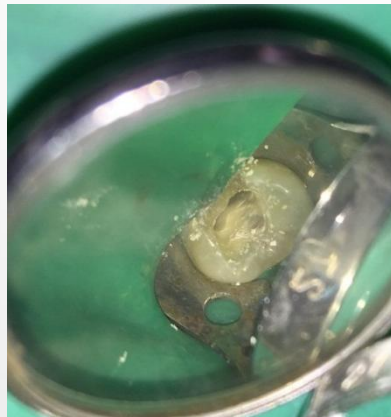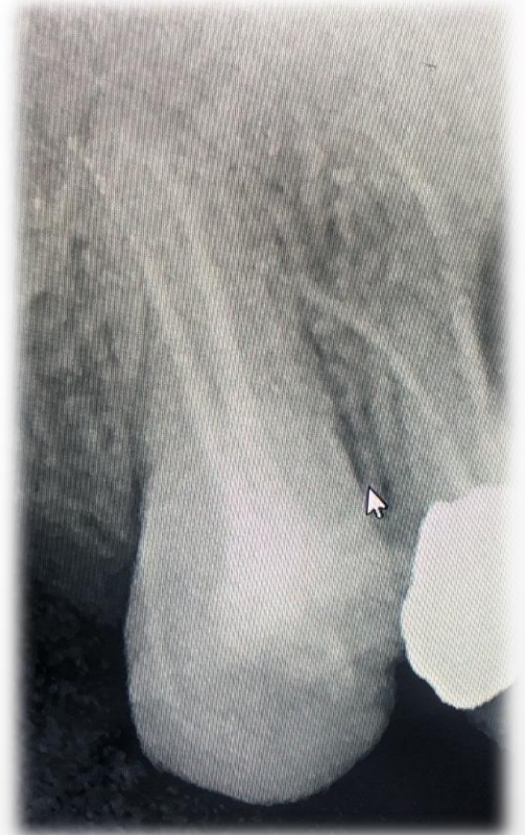


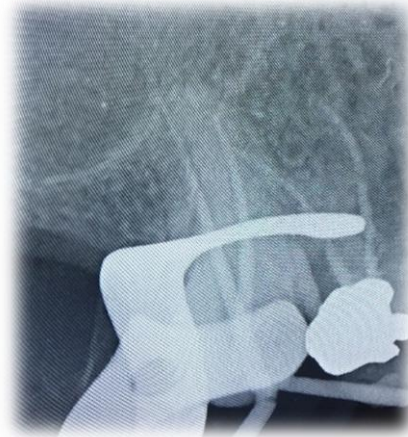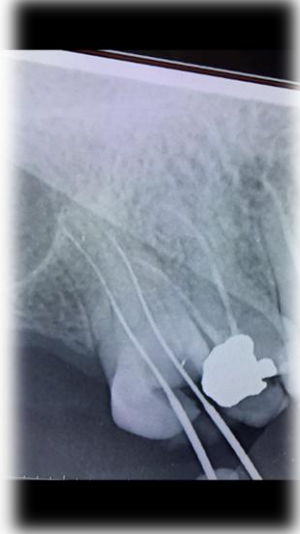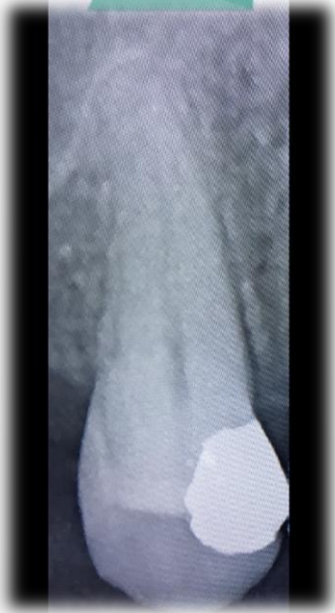# RCT UL3

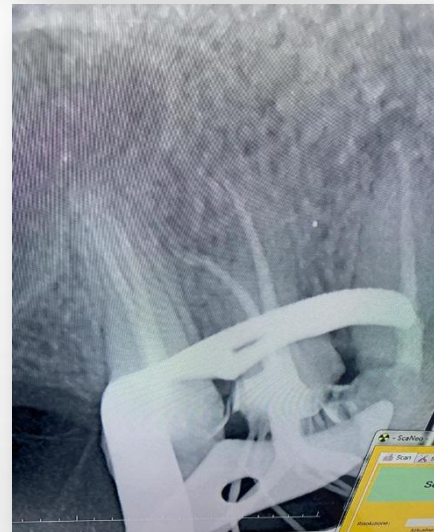
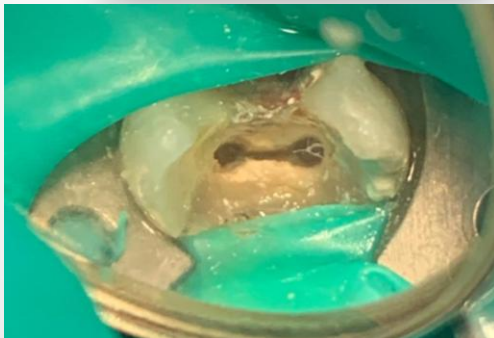
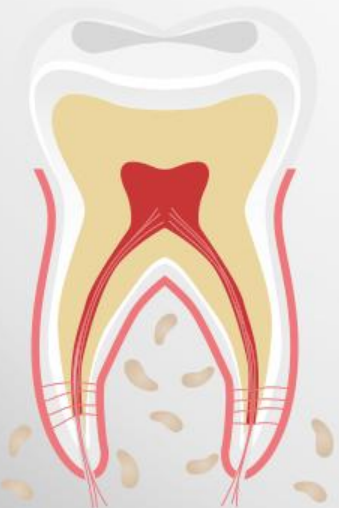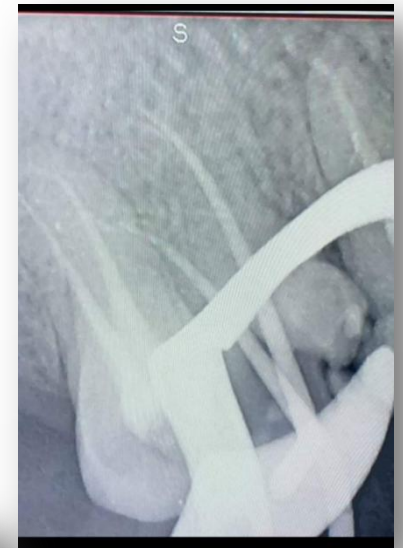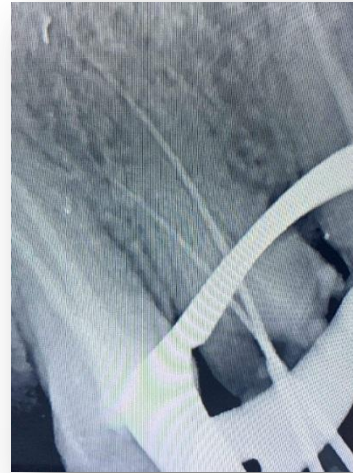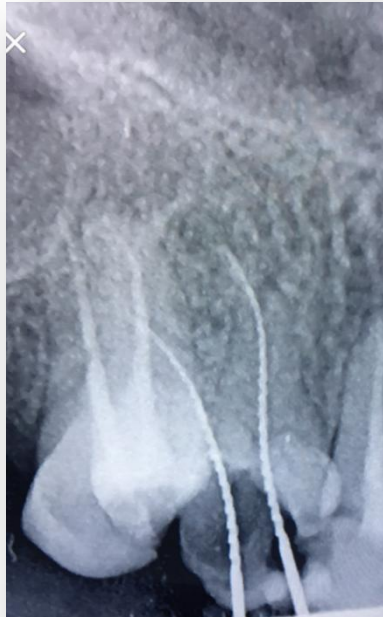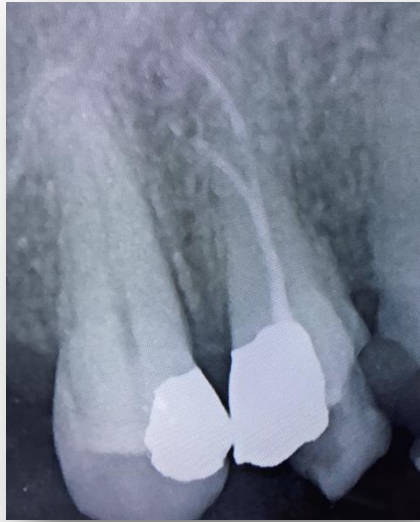




# RCT UR5

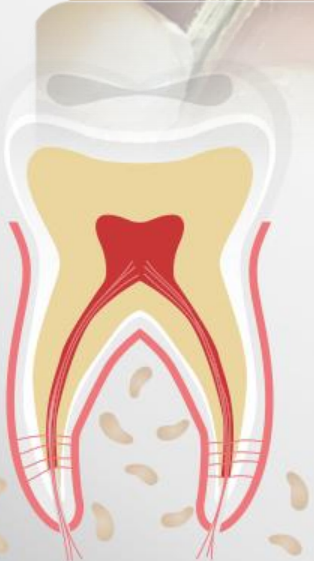
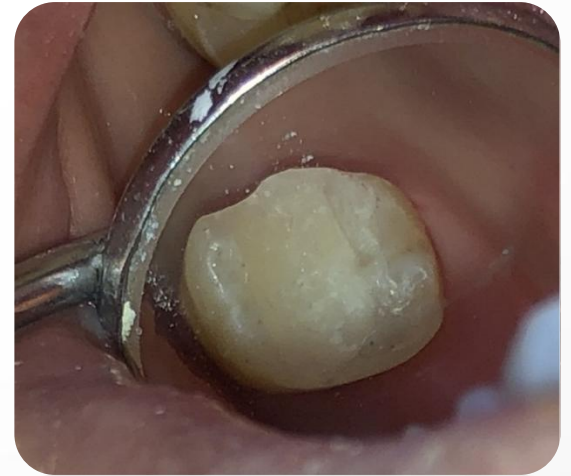
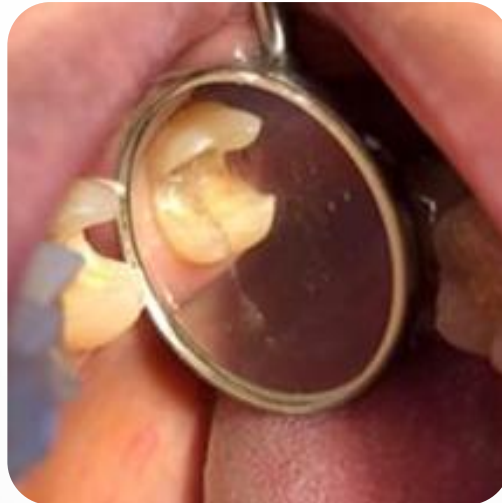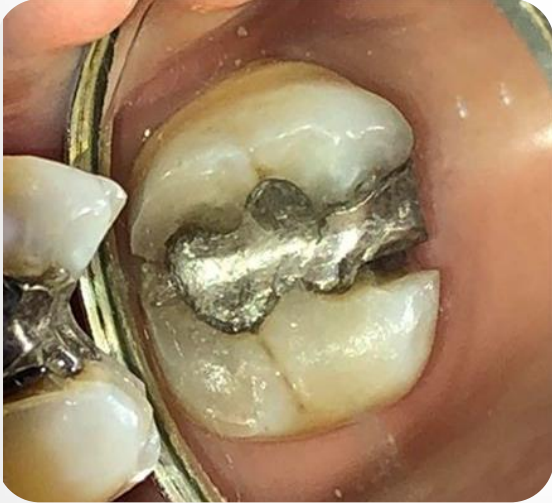# RCT UR2

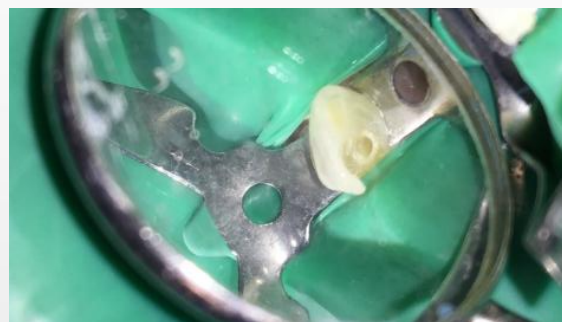
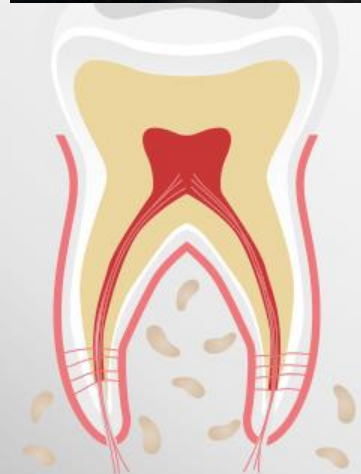
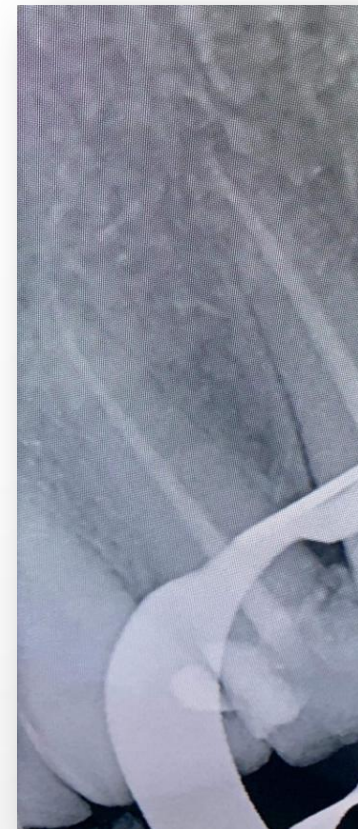
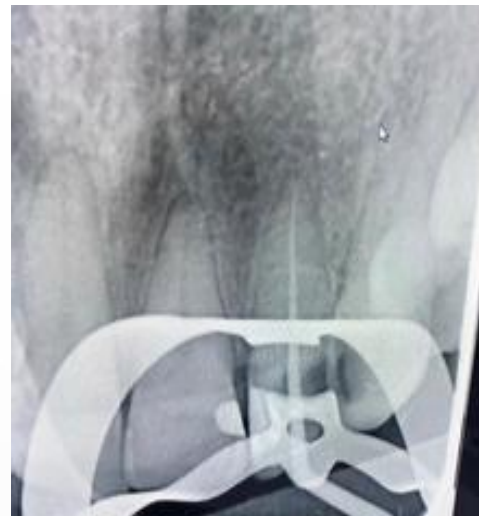
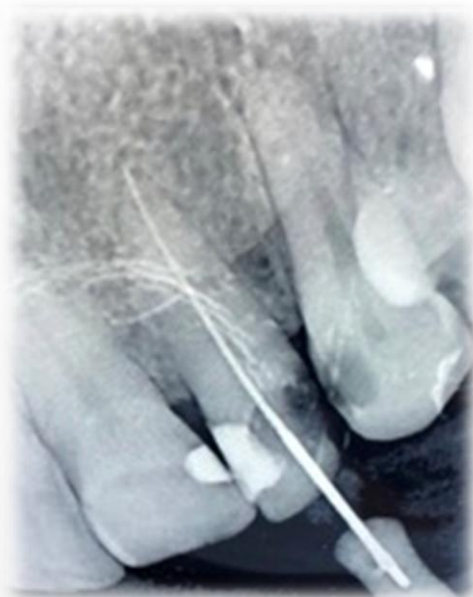
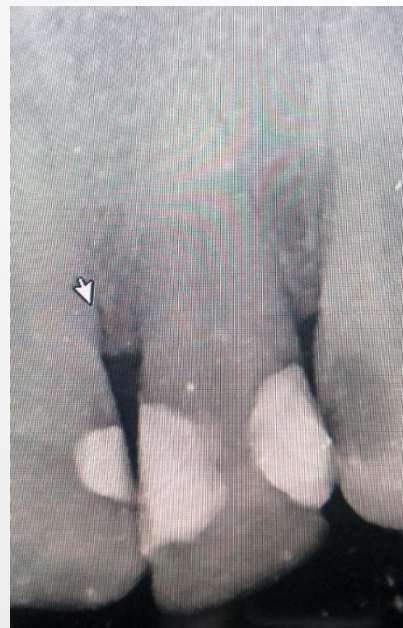# FILLING UL7

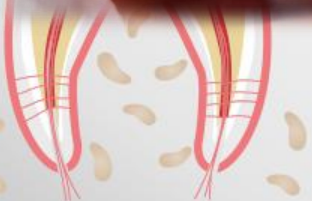
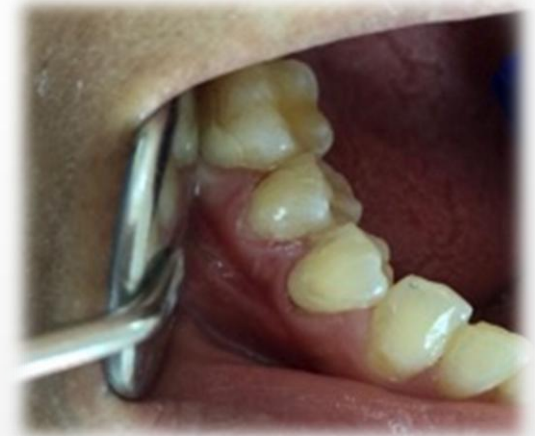
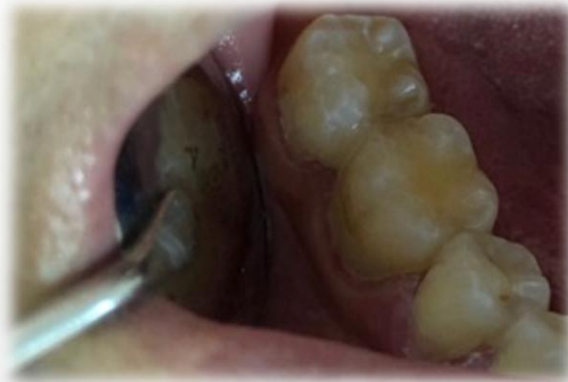
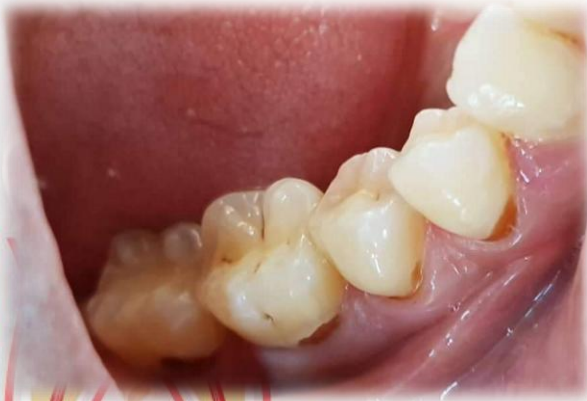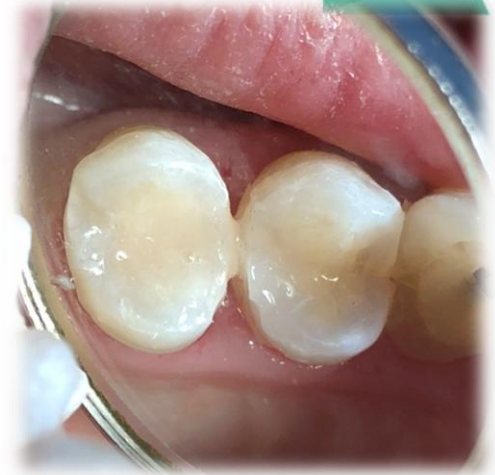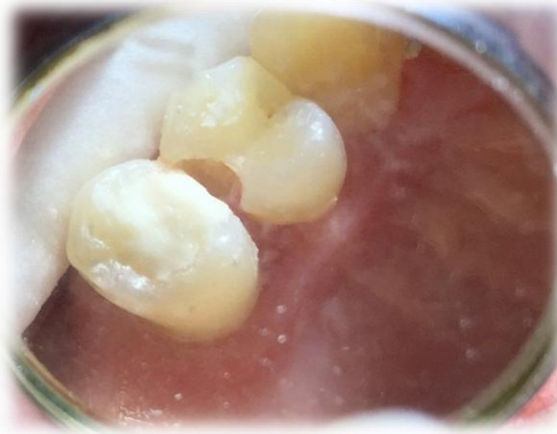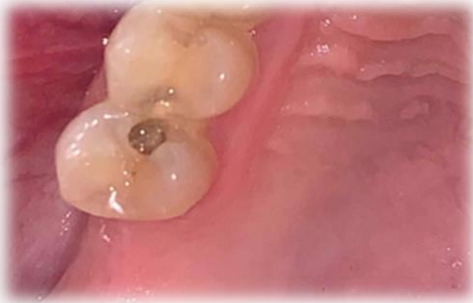# RCT UL2

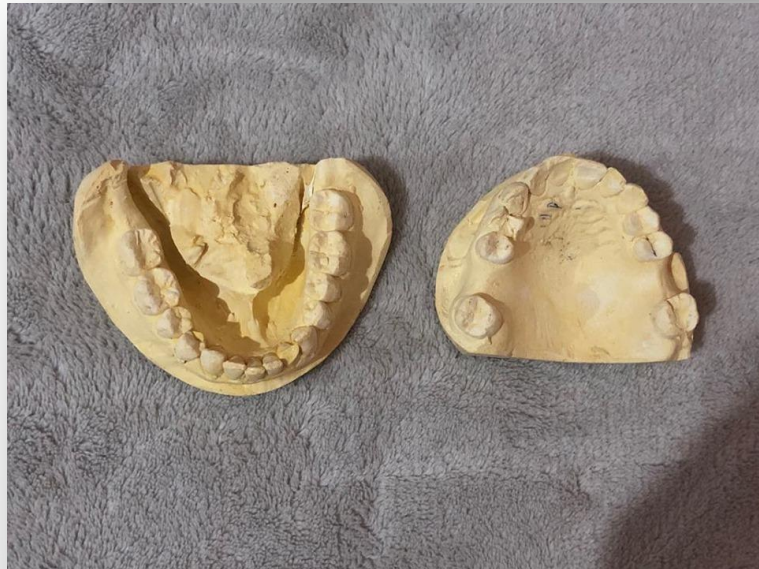
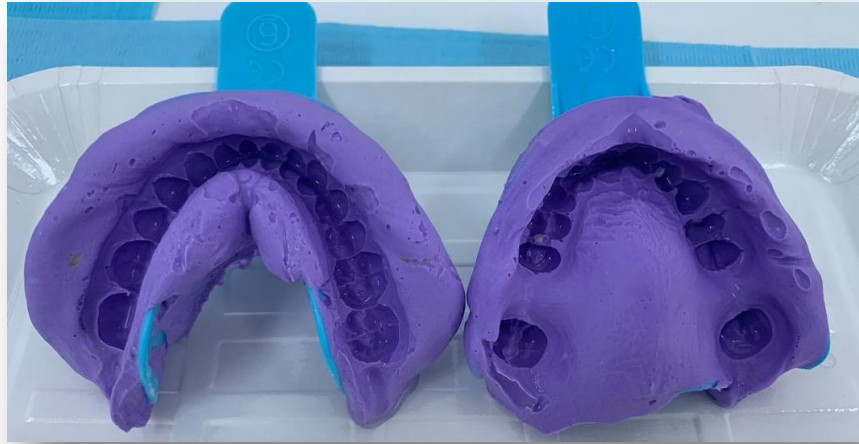


# FILLING UL4/LR7654



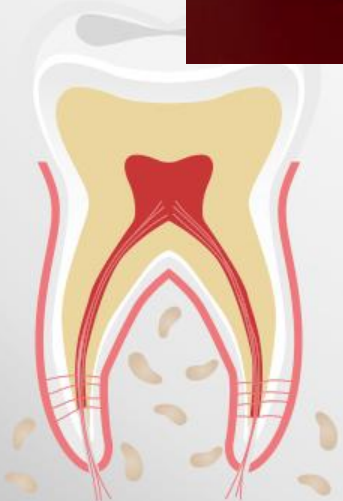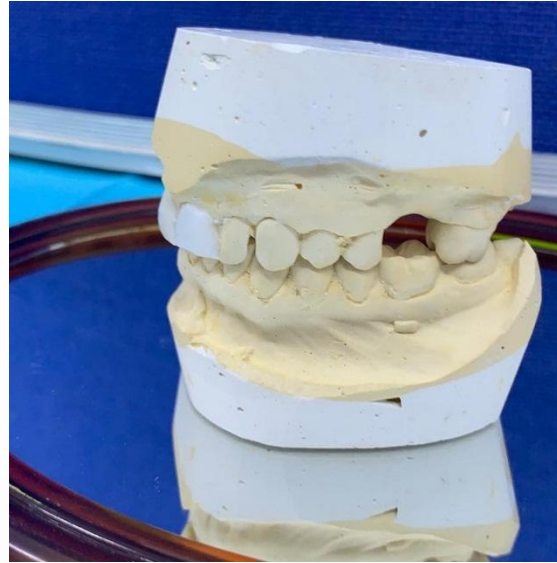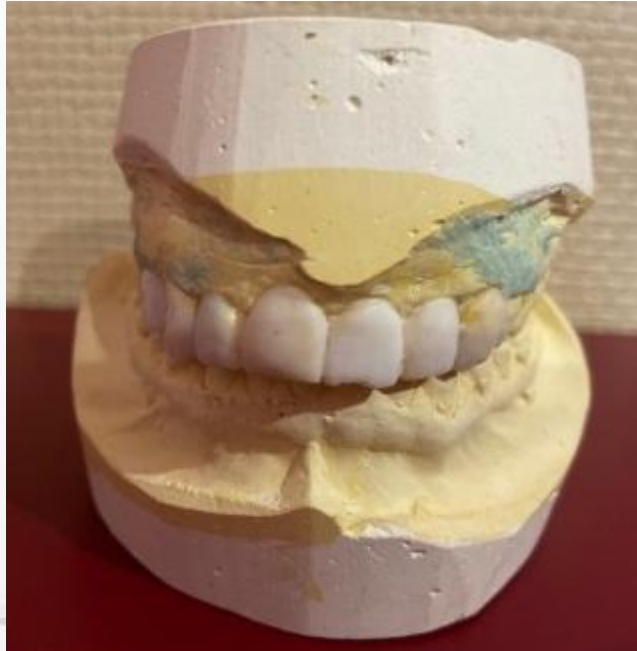# PRIMARY IMPRESSION



STUDY  
CAST

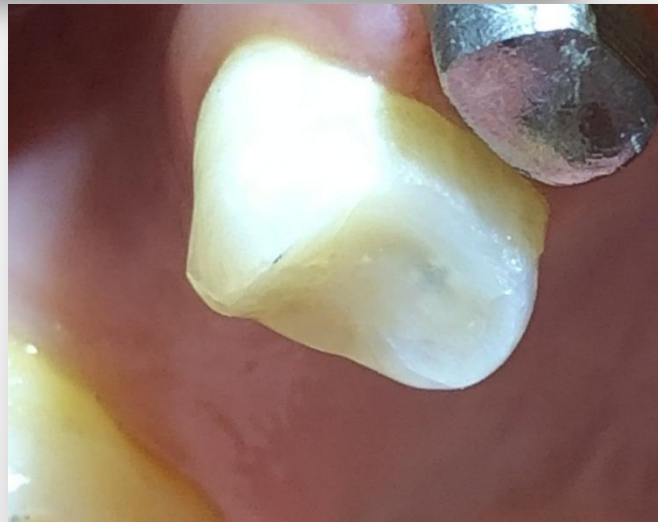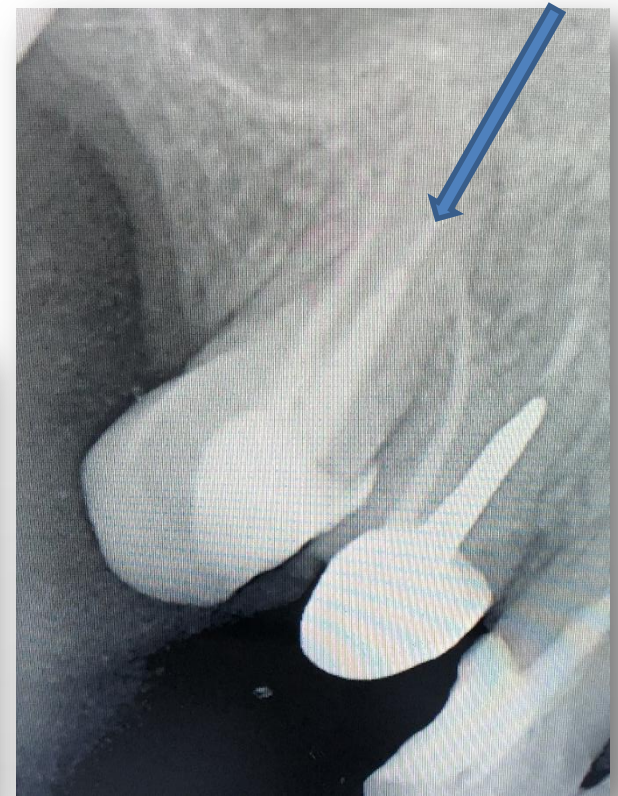


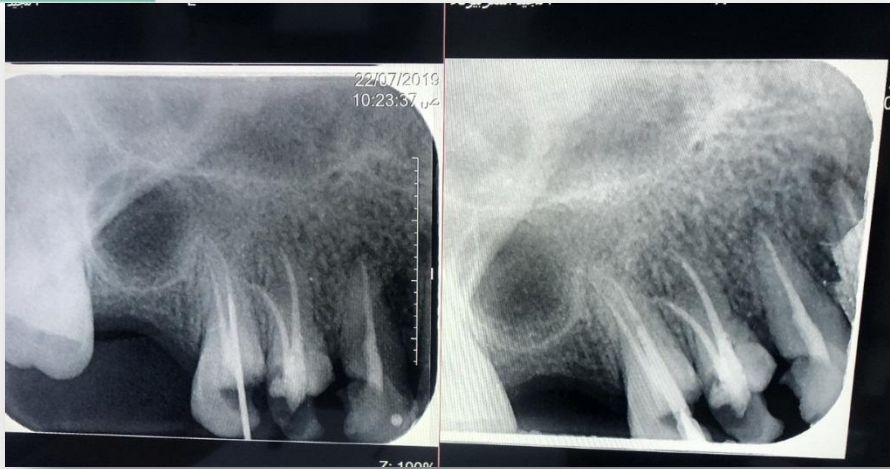# WAX UP

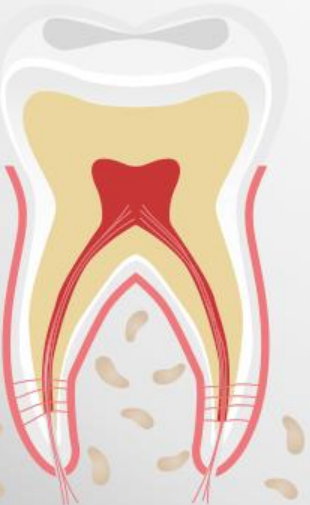
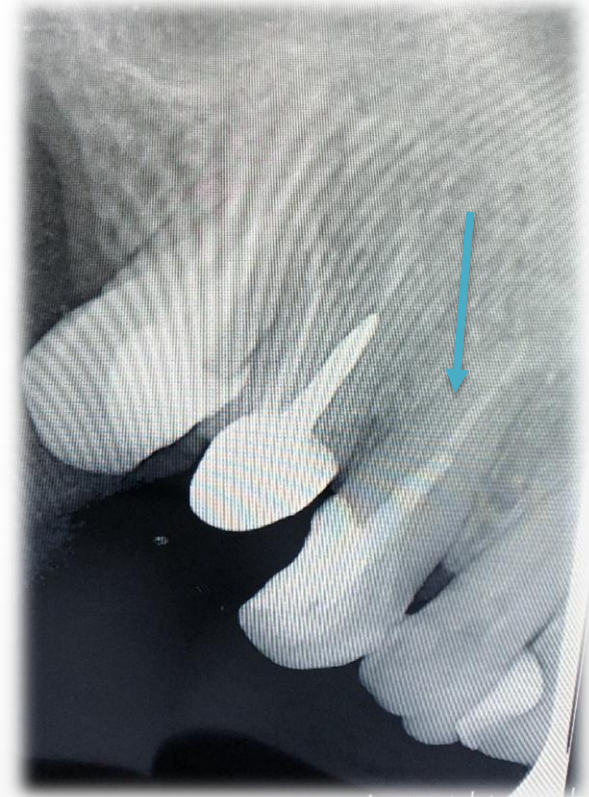
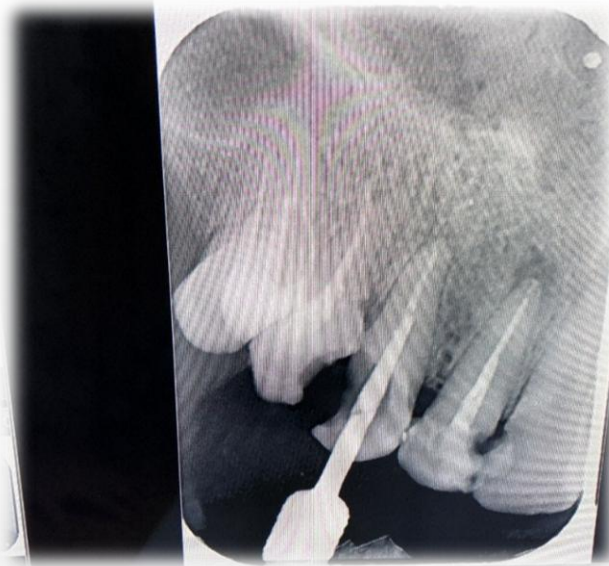
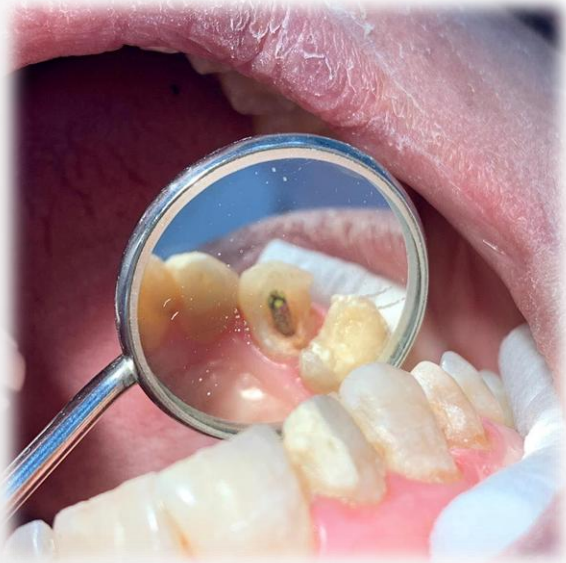
# POST INSERTION UR5

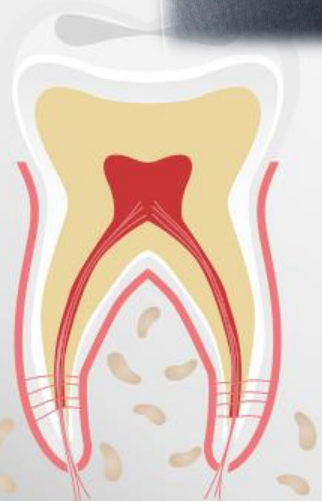
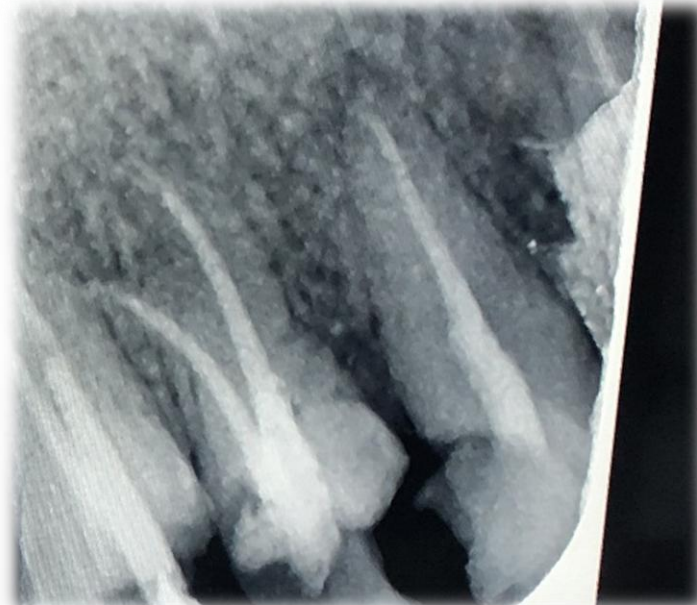
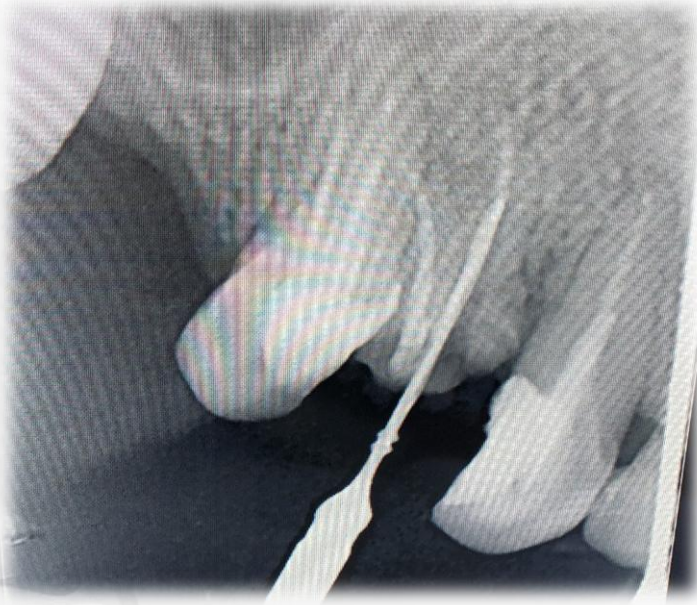# POST INSERTION UR3

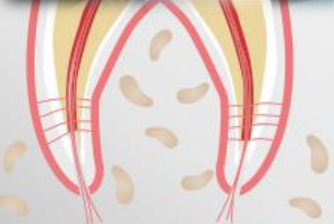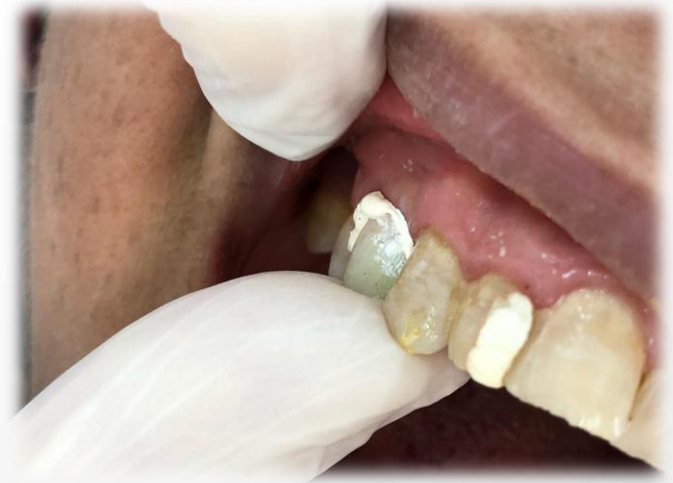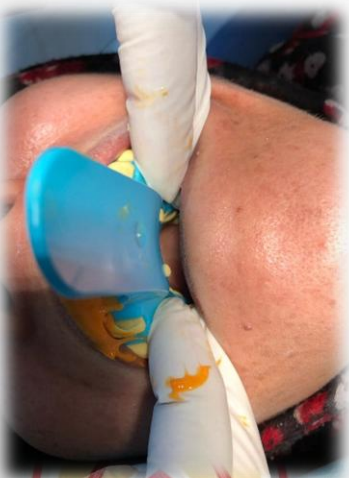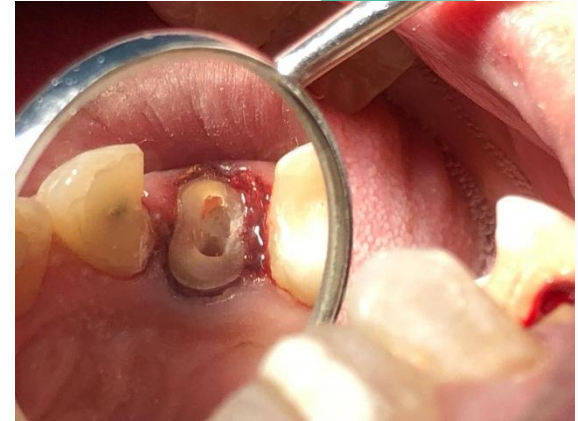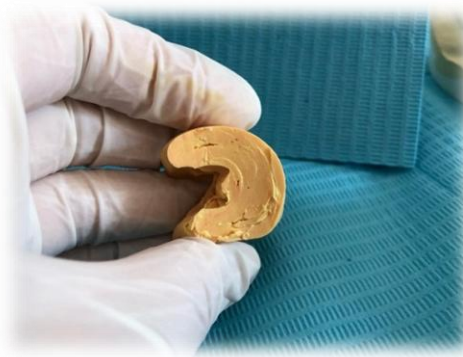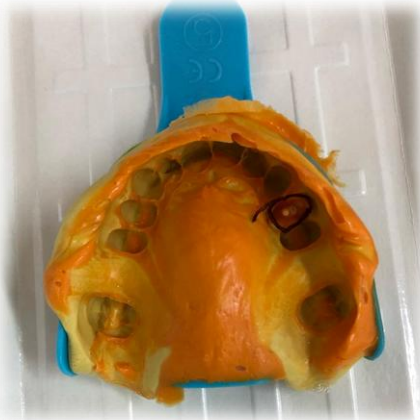




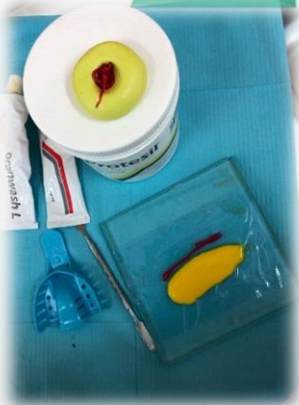# POST INSERTION UR4

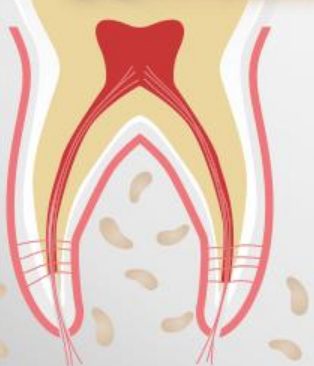
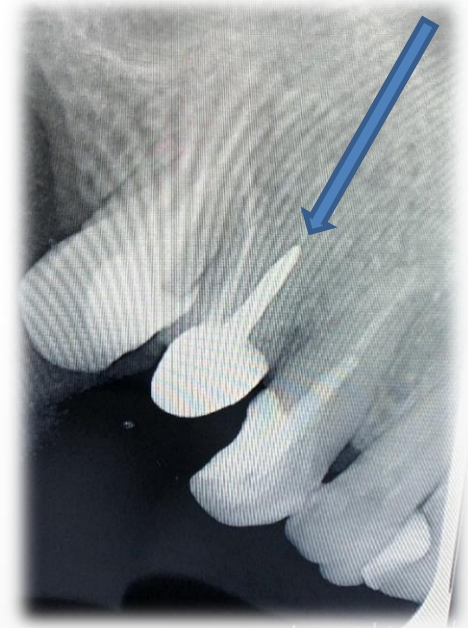
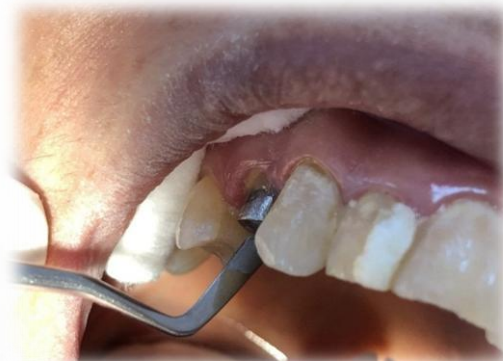
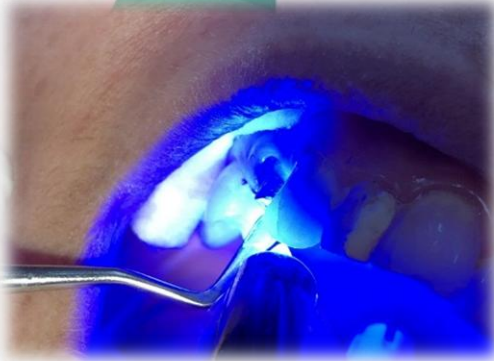# POST INSERTION UR3

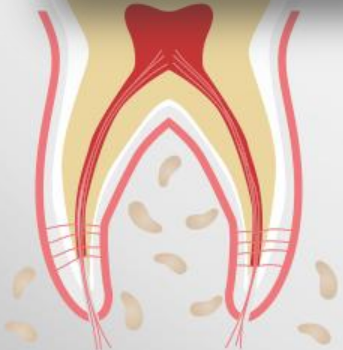
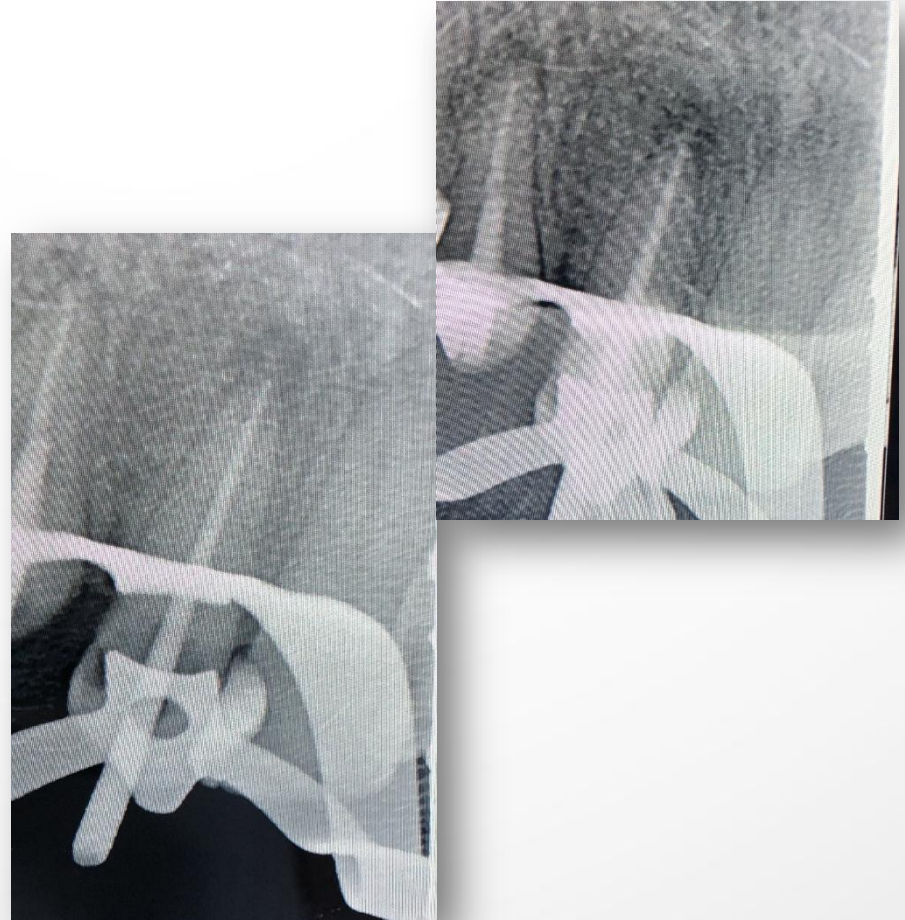
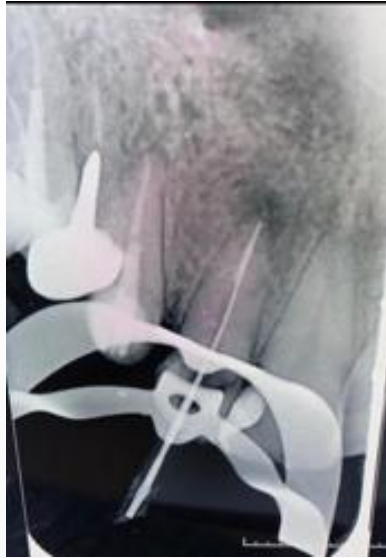
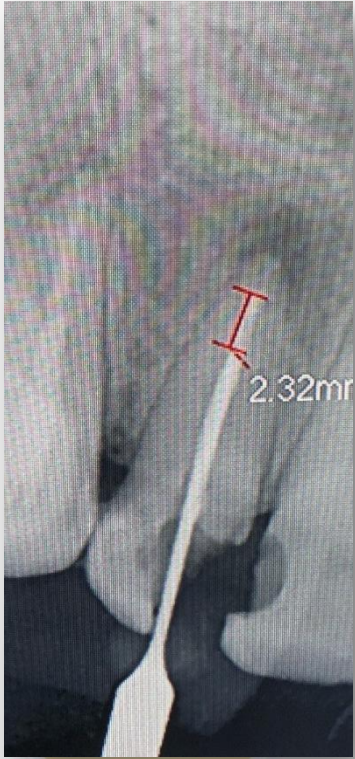


# POST INSERTION UR3

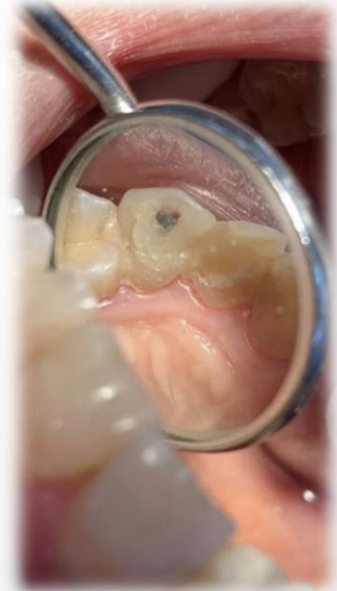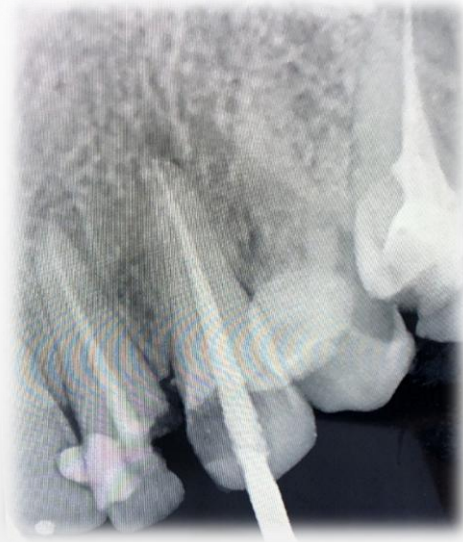
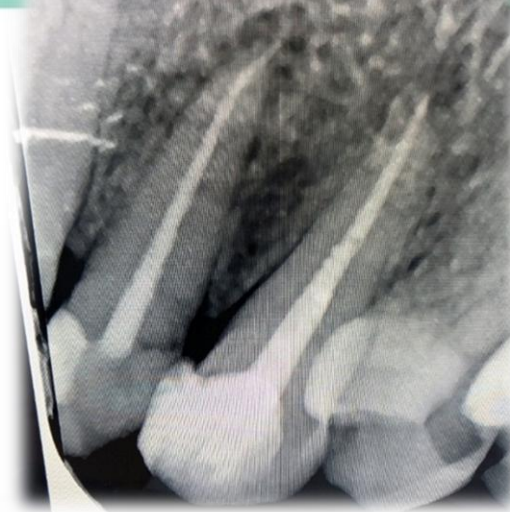
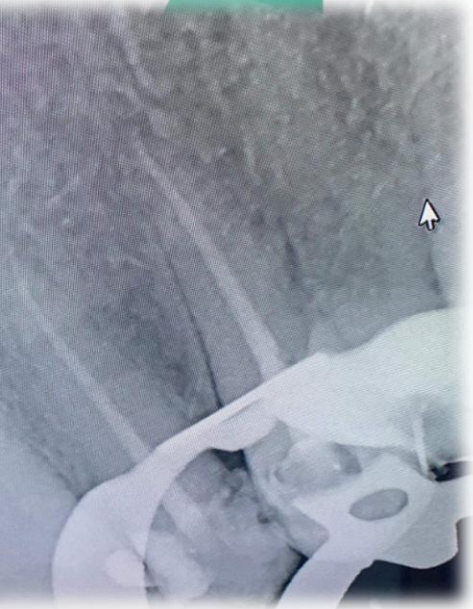


# RETREATMENT UR2



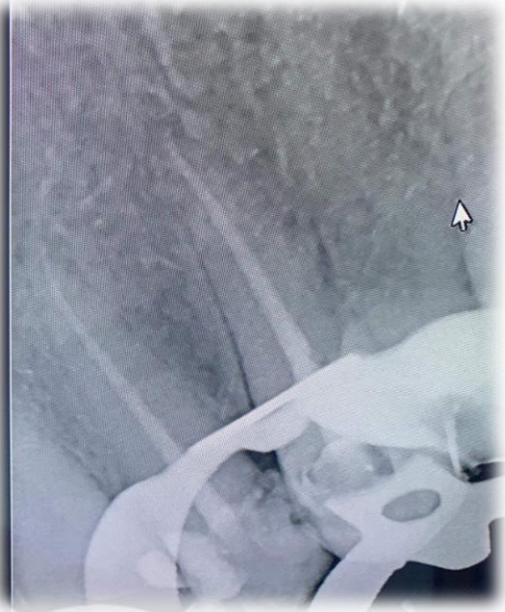

# POST INSERTION UL3

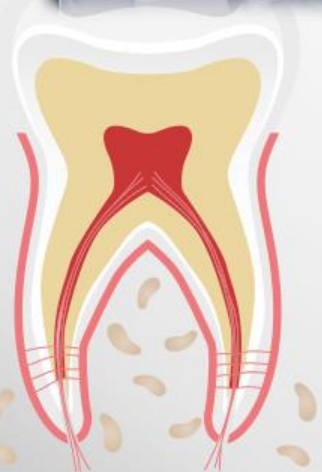
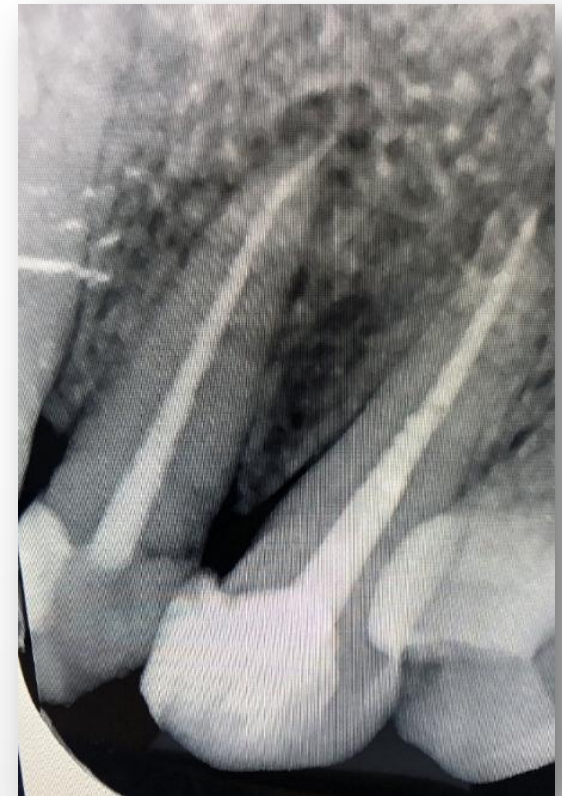
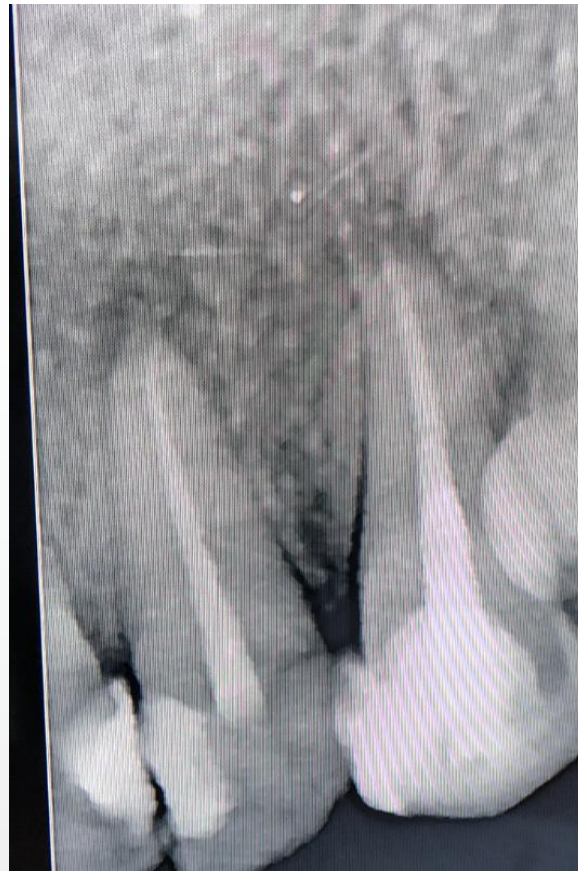# FOLLOW UP UL2

3M

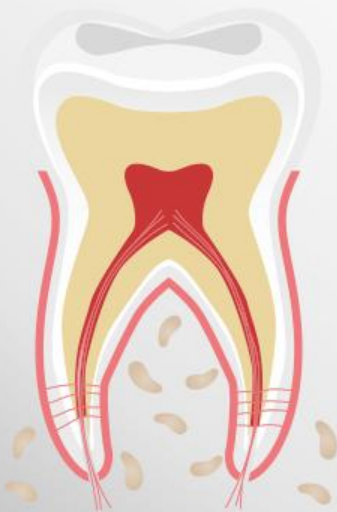
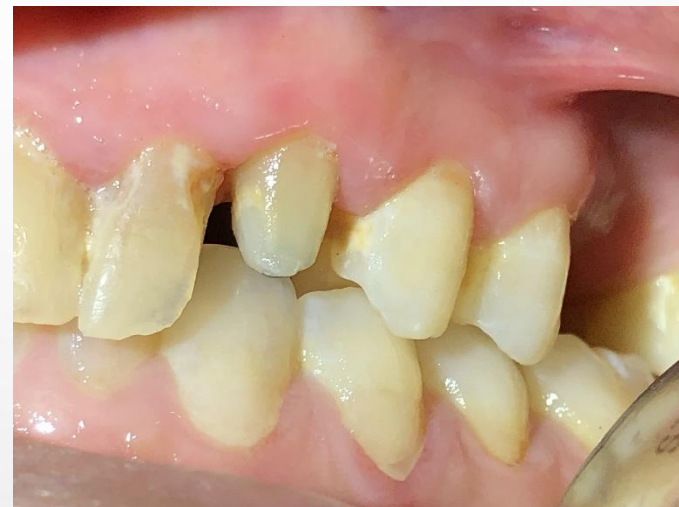
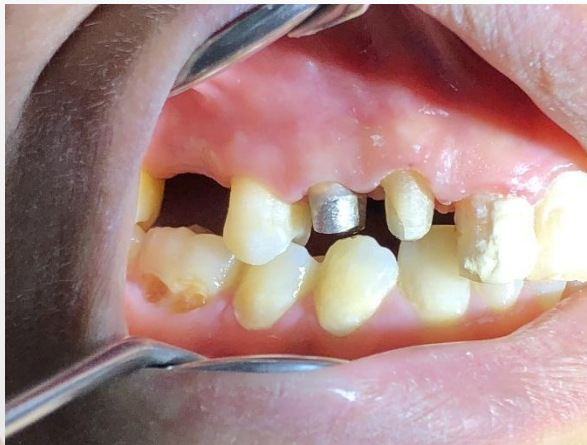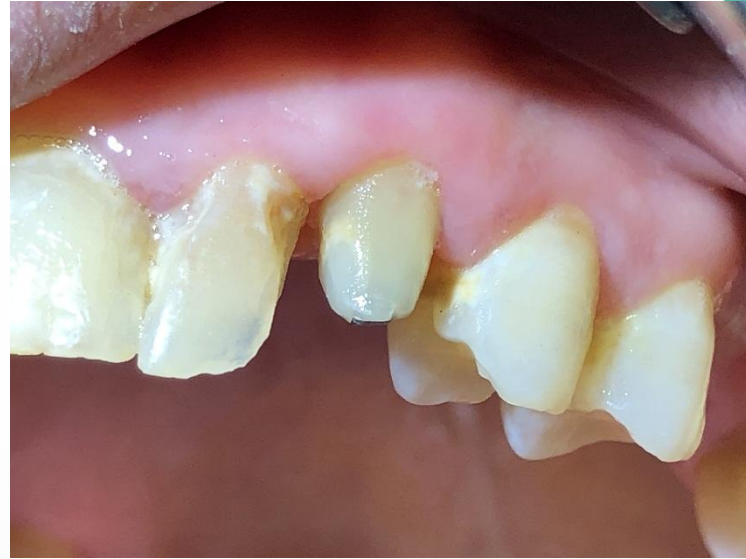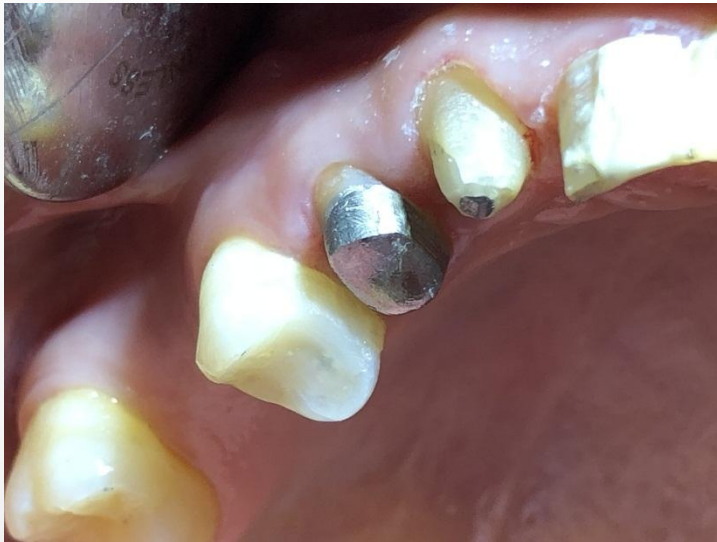4M

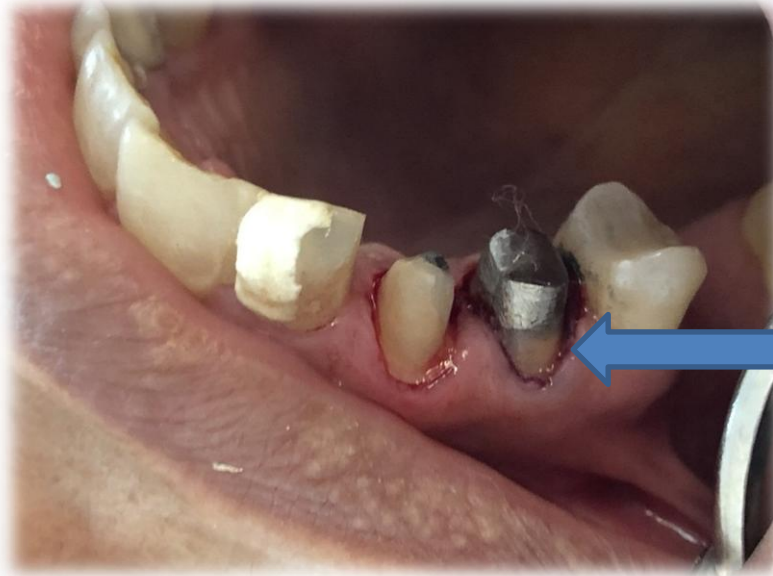
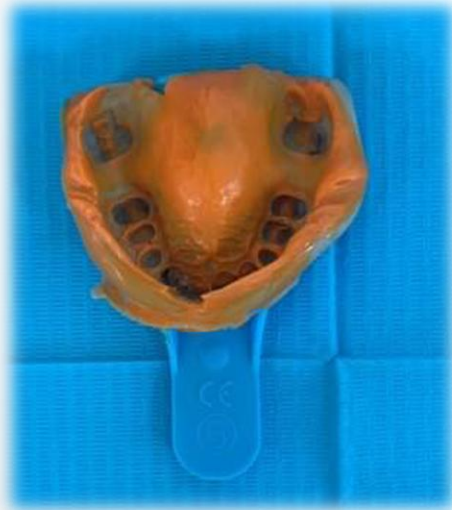



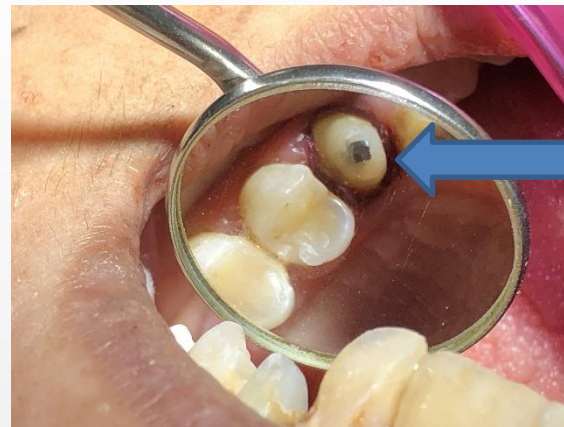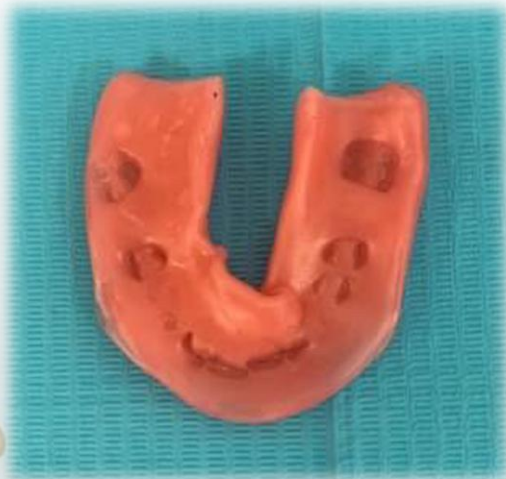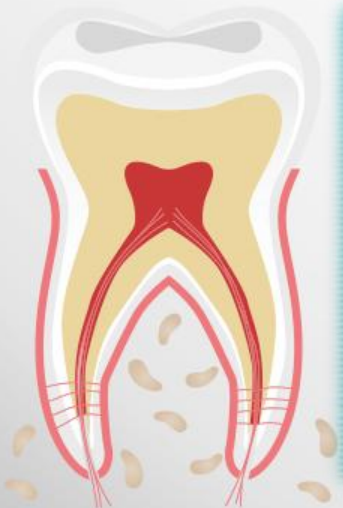# PREPARATION TOOTH UR43 /UL3



# FINAL IMPRESSION UR43/UL3



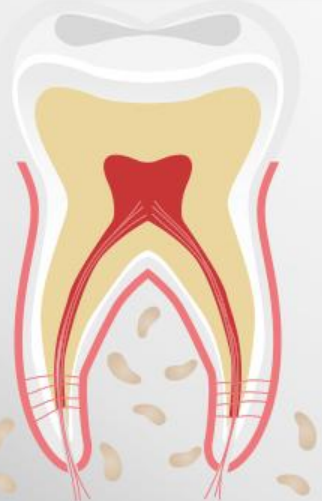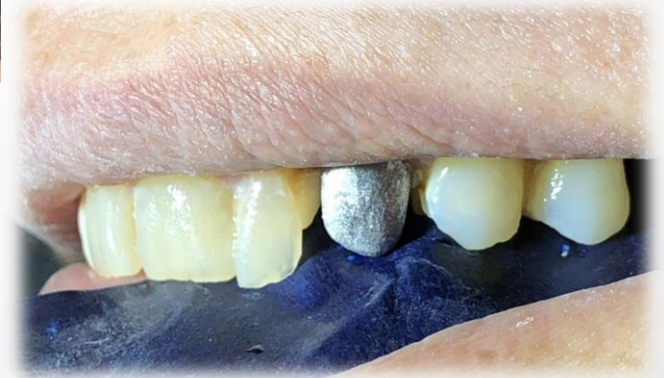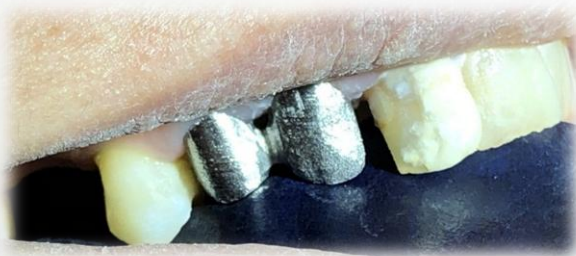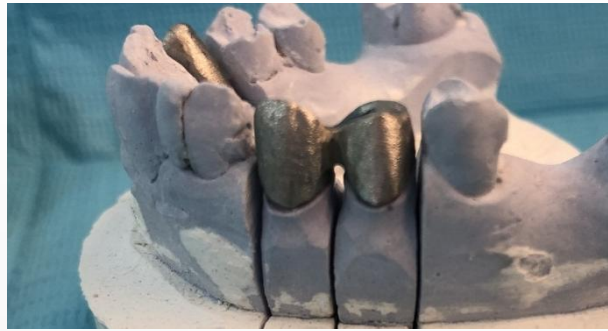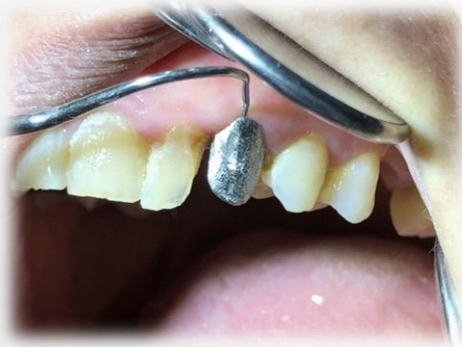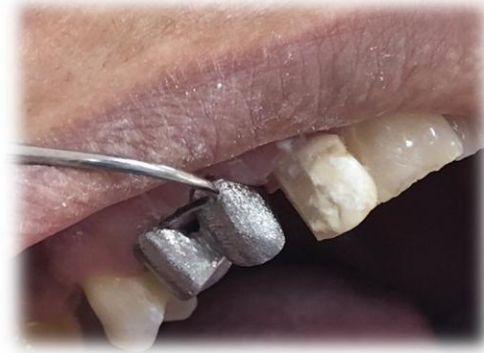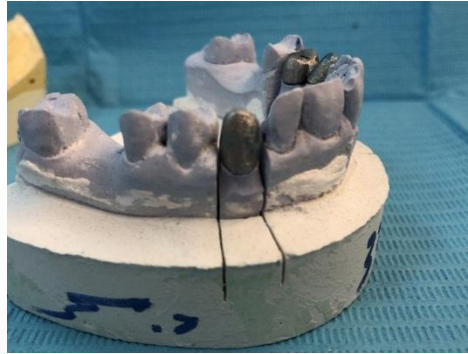
Retraction  
cord



Retraction  
cord

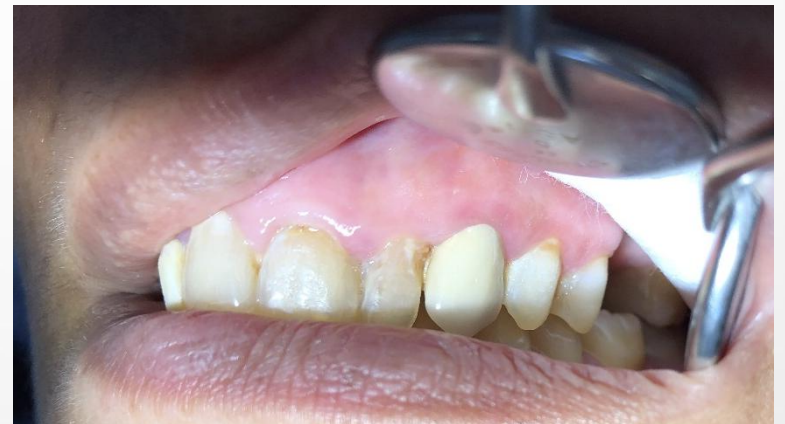

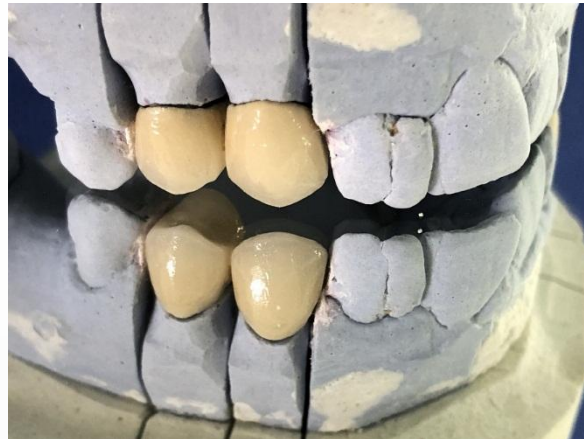
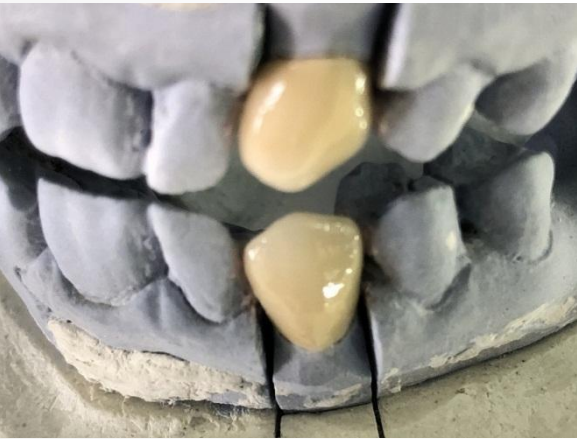# TRAY IN

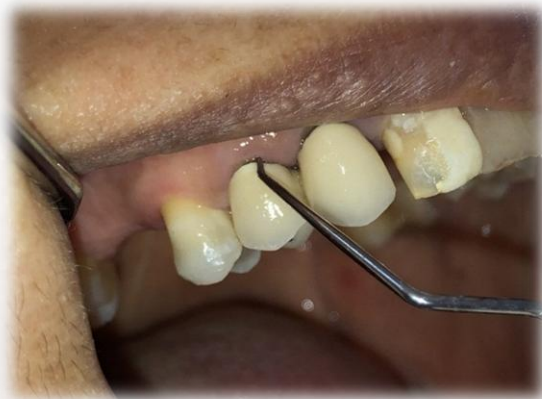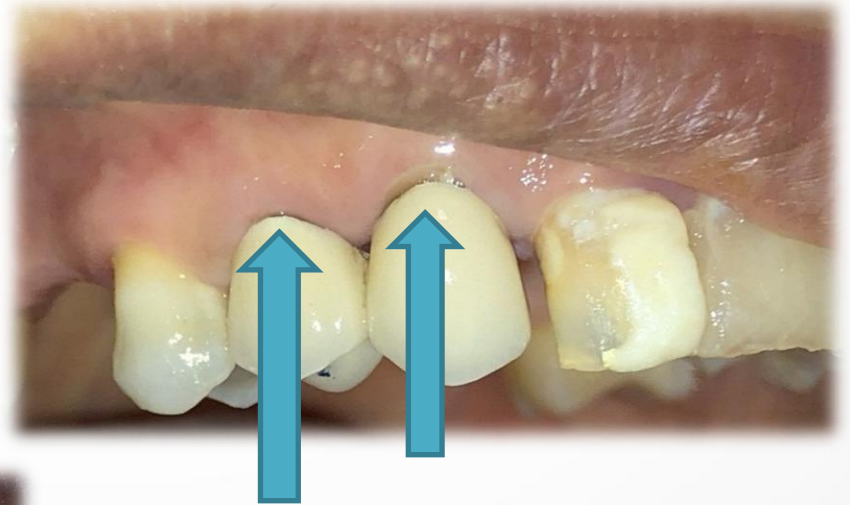


# INSERTION UR3

Temporay  
cementation



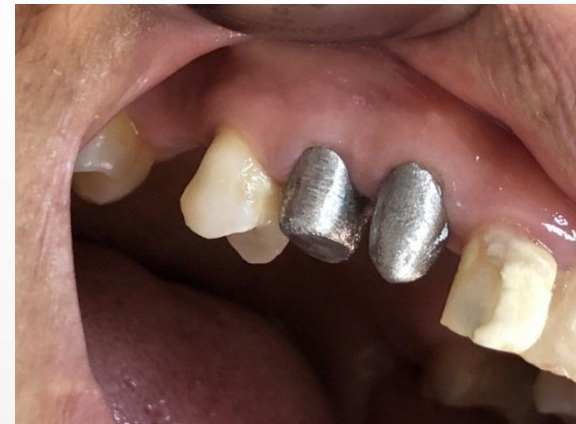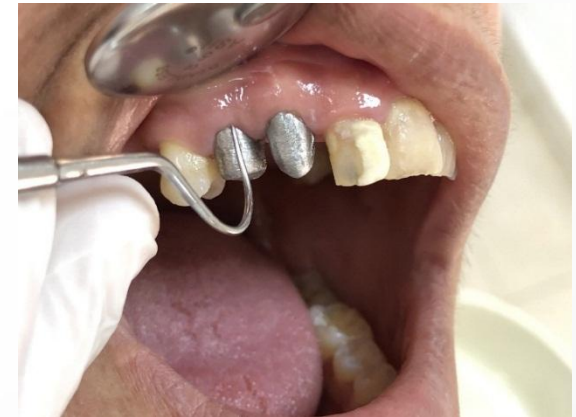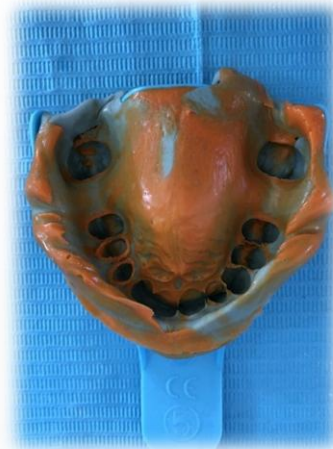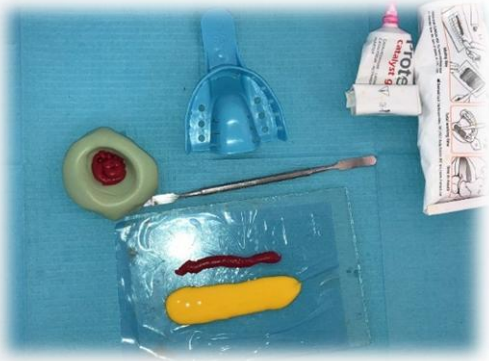**Open marginal**  
**UR 43**





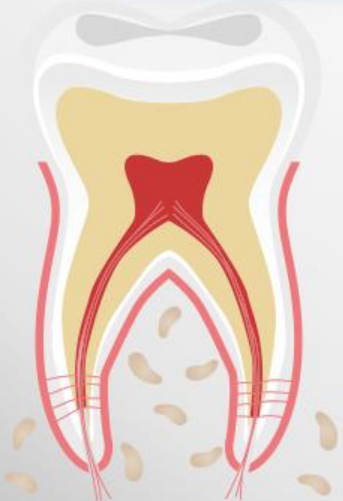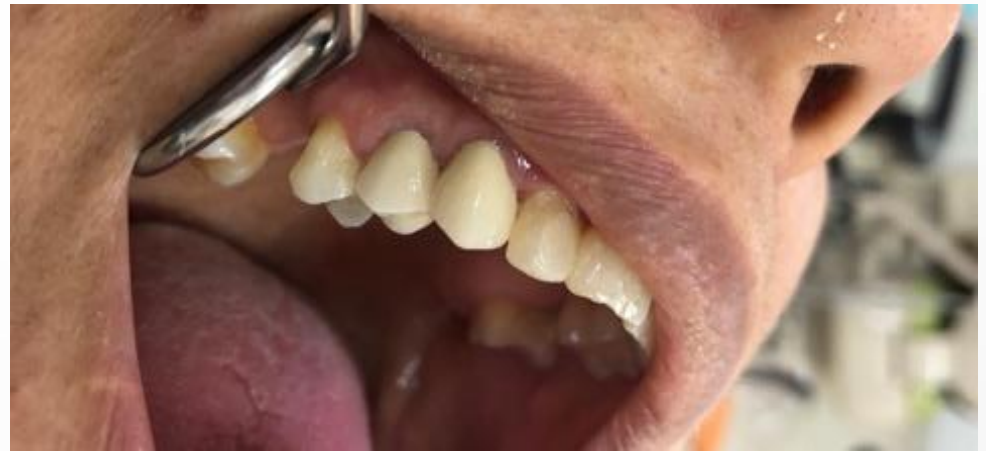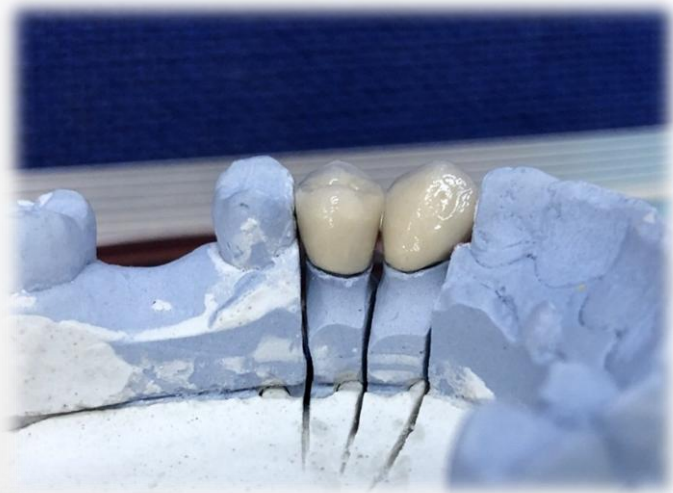# RETURIN TRAY IN

# UR43


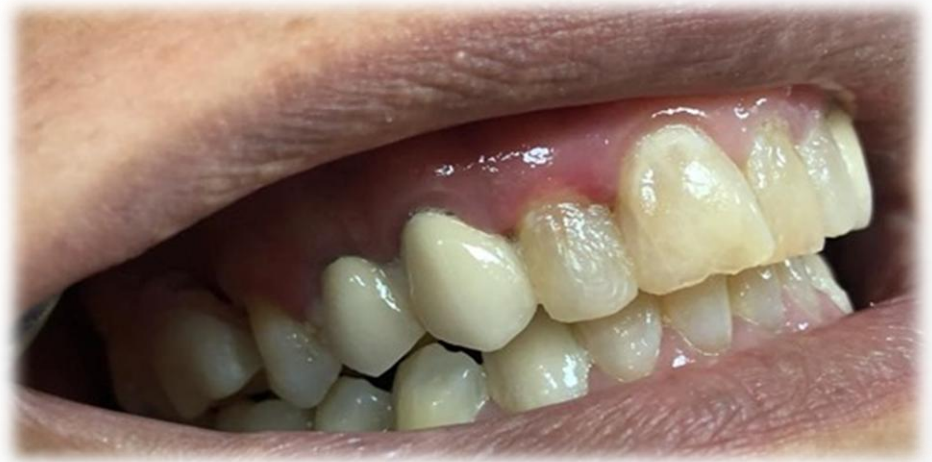
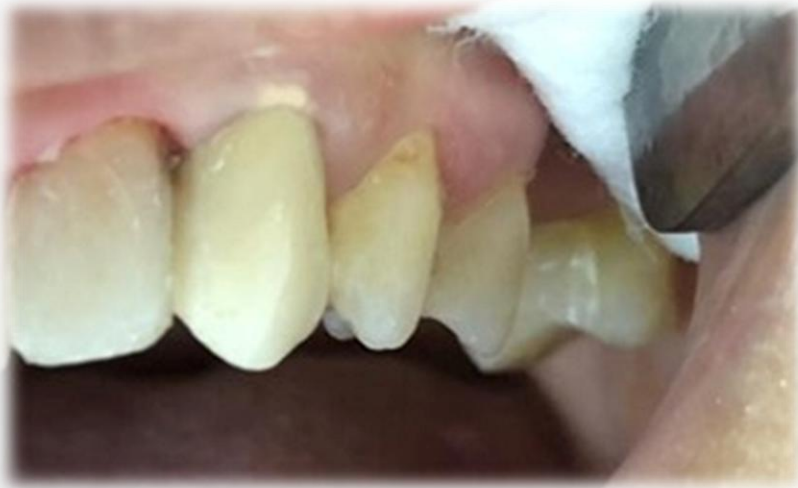

# TEMPORAY CEMENTATION UR34

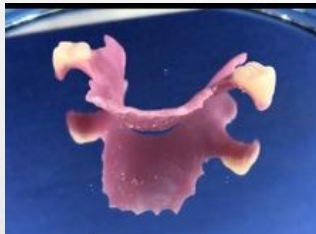
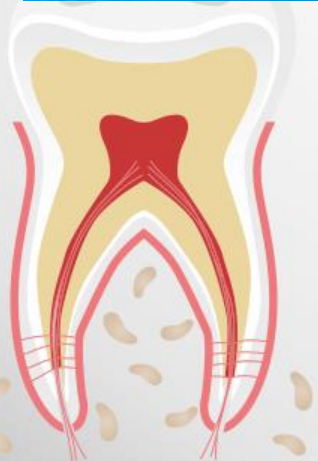
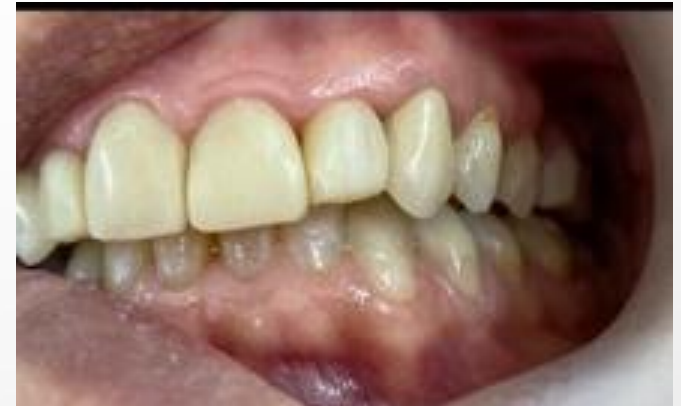
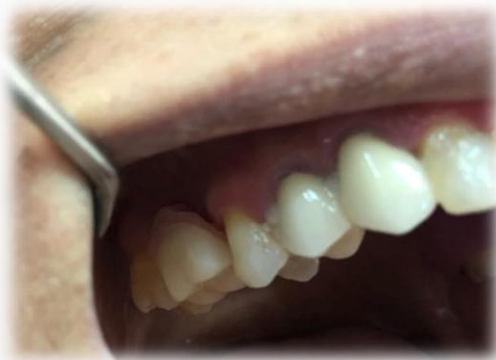
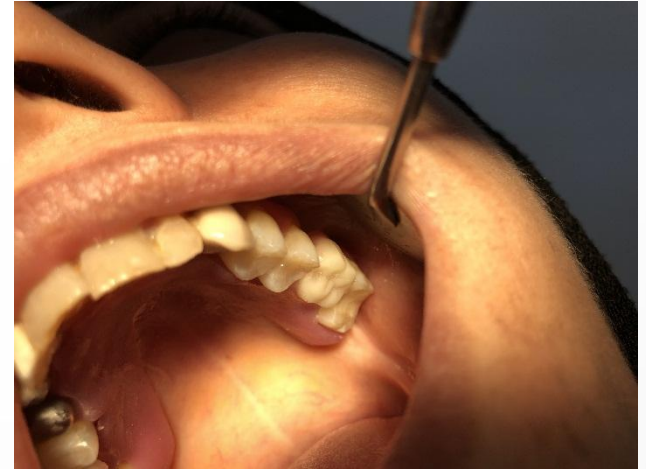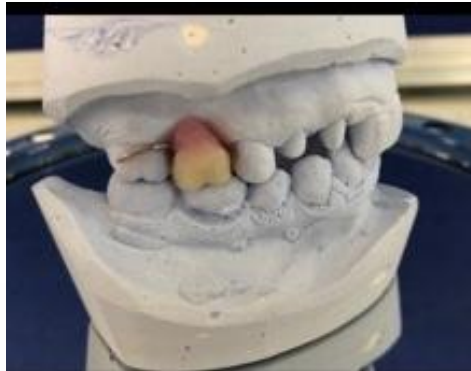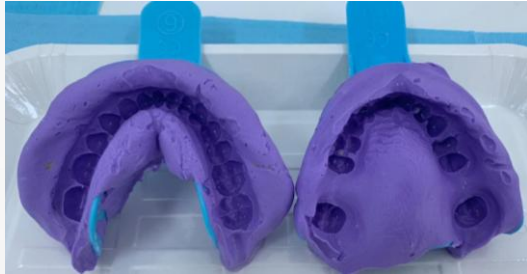# FINAL CEMENTATION UR4 3/ UL3



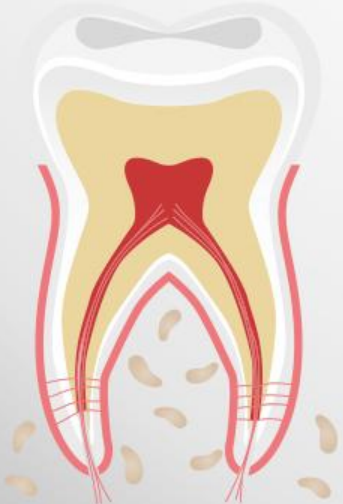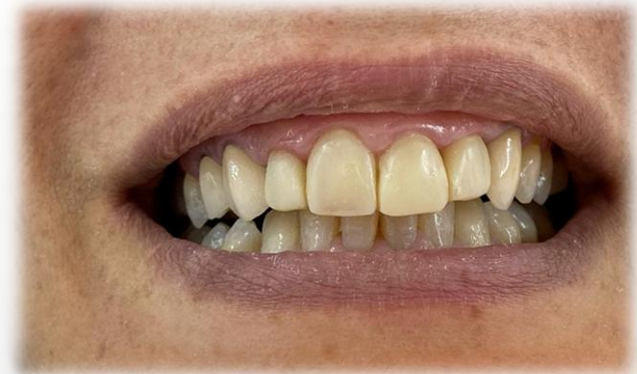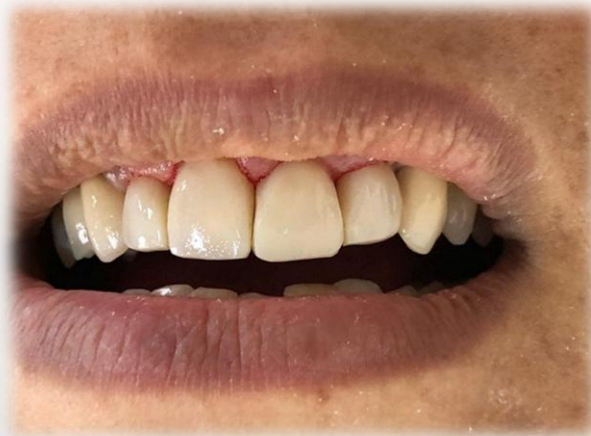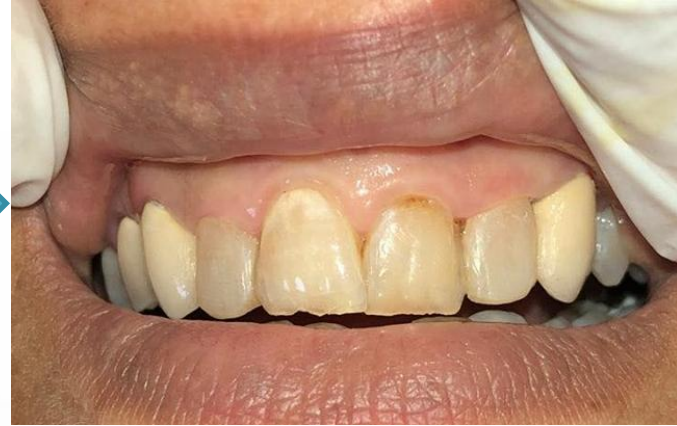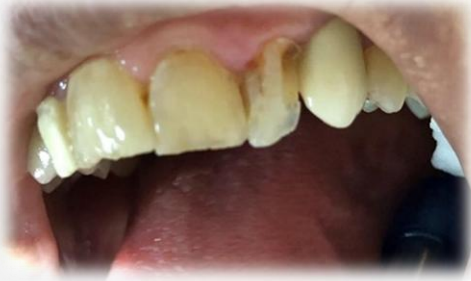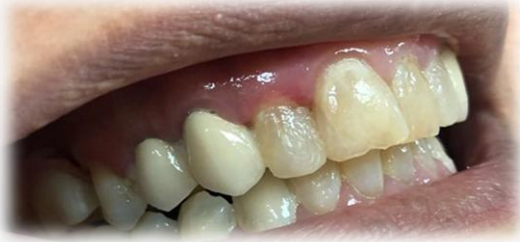# REMOVABLE PARIAL DENTURE

## UR6/UL6



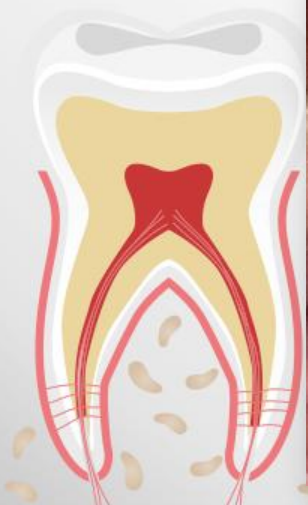
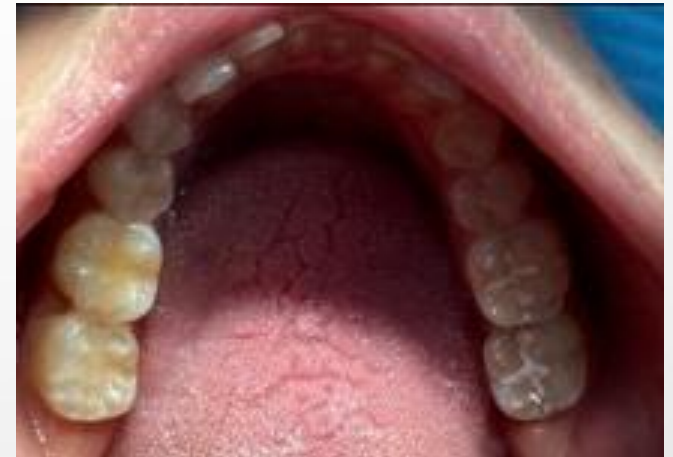
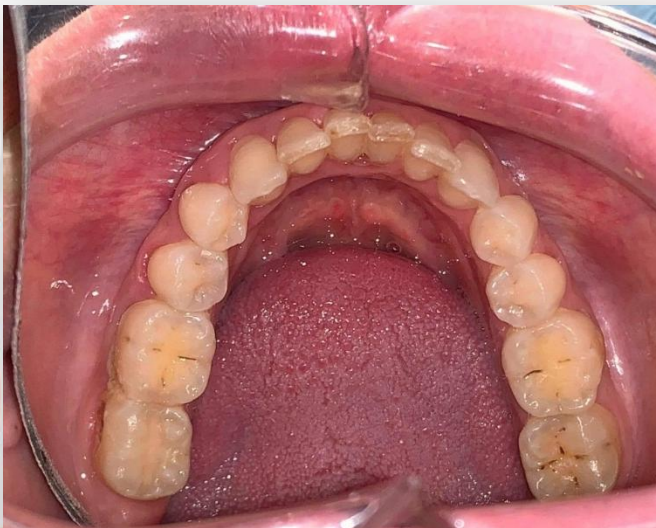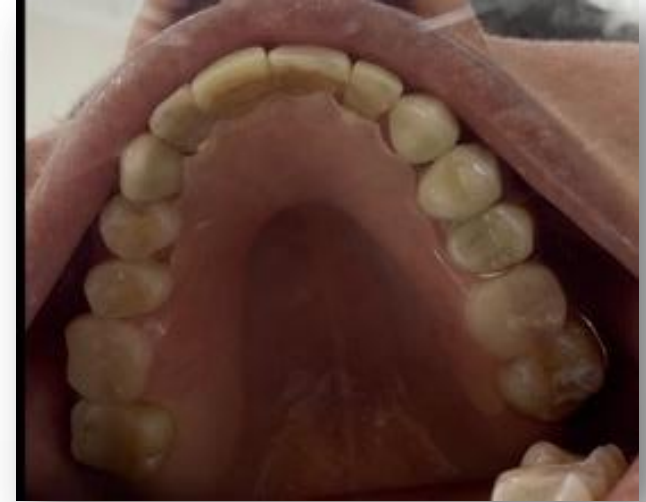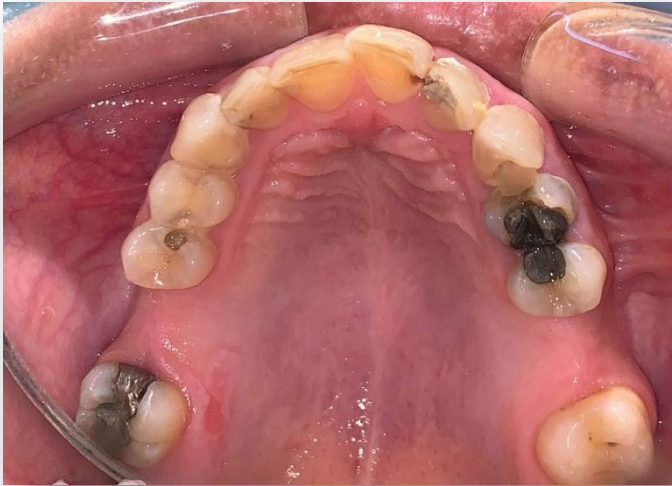# BULID UP COMPOSITE UR2/UL2 COMPOSITE VNEER UR1/UL1



**Befor**

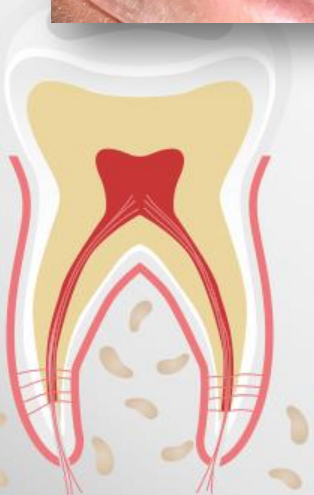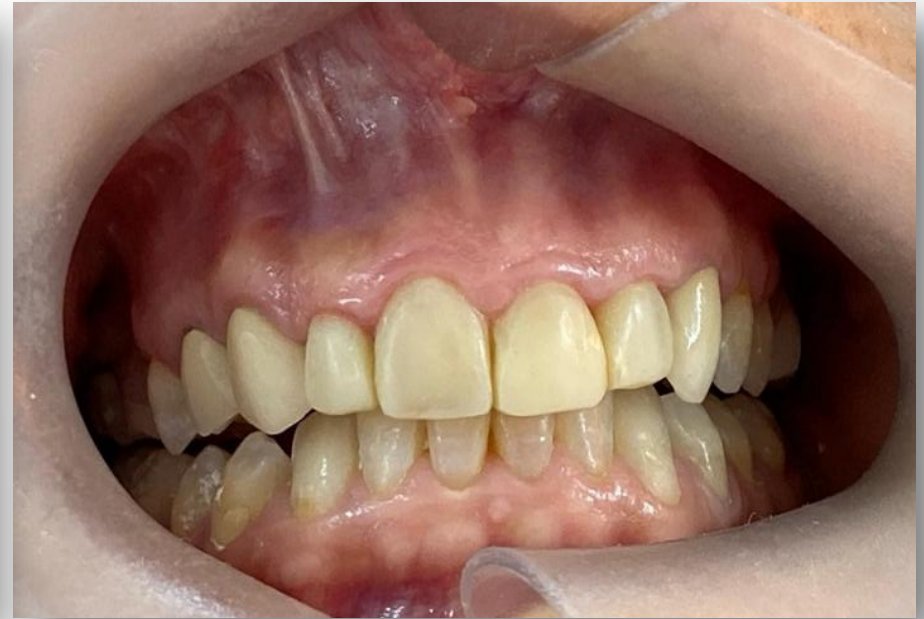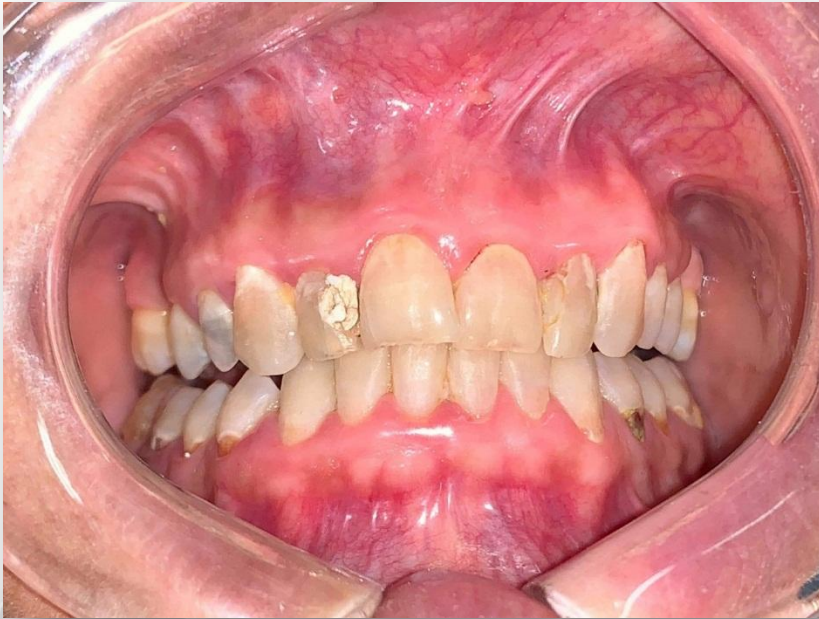**After**





**Befor**

**After**







thank  
you

