



# Cervical Ectopic Pregnancy



Esra Hammid Eltaboly

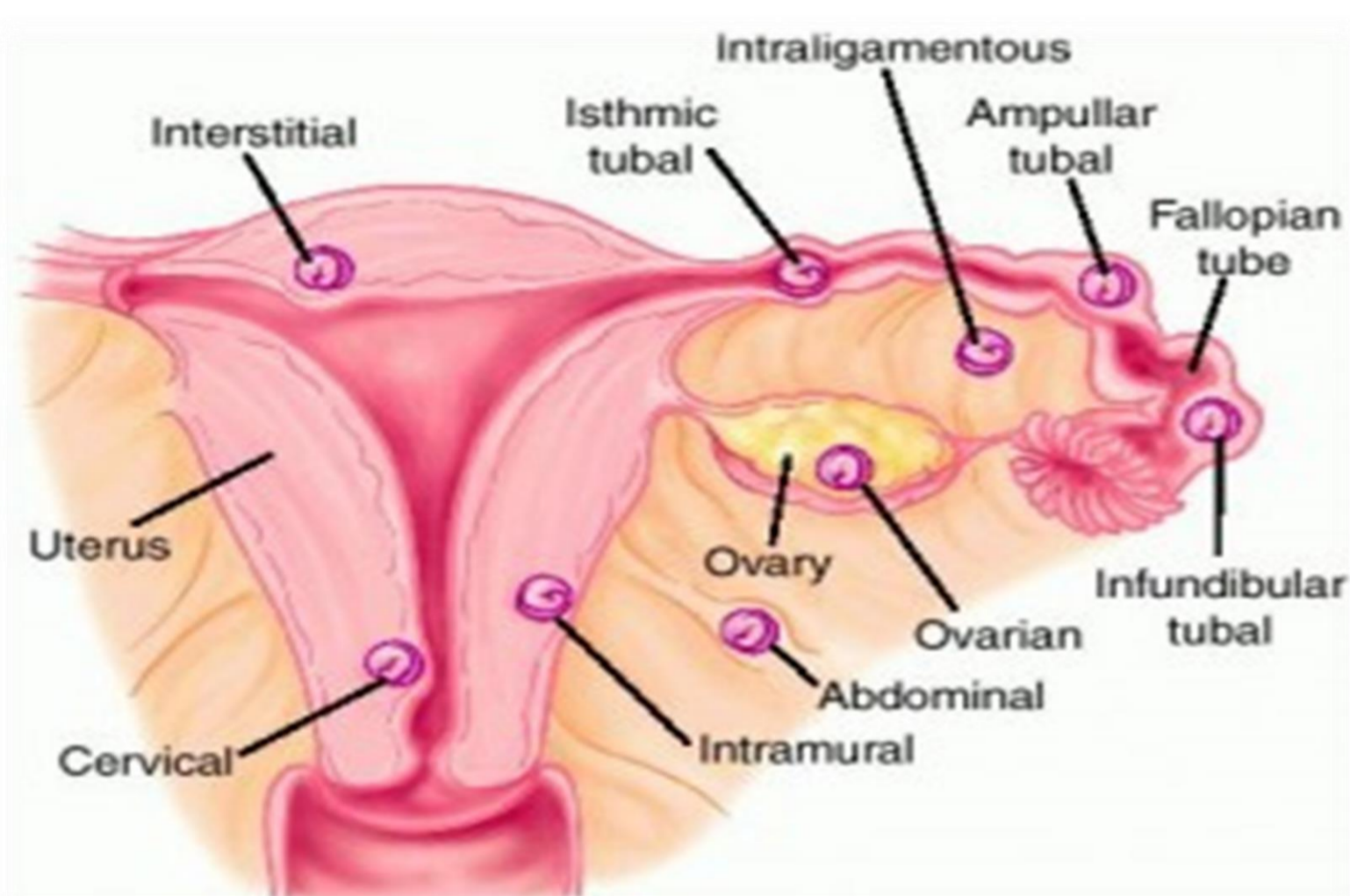
Libyan International Medical university

## Introduction

Ectopic pregnancy is a complication of pregnancy in which the embryo implants and develops outside the uterine cavity.

The most common site is in one of the narrow tubes that connect each ovary to the uterus (fallopian tube) and are referred to as a tubal pregnancy. Other sites for embryo implantation include the ovary or outside the reproductive organs in the abdominal cavity or the cervix.

About 1 in 100 pregnancies is ectopic.



Cervical pregnancy is an ectopic pregnancy in which the gestational sac implants in the cervical canal. The incidence of cervical pregnancy is rare at <1% of ectopic Pregnancies.

Risk factors increase with any of the following:

- 1- Maternal age between 35 and 40 years.
- 2- Use of intrauterine devices, and assisted reproductive technologies.
- 3- previous endometrial curettage.
- 4- previous cesarean section.
- 5- In vitro fertilization
- 6- Asherman's syndrome, leiomyomata.<sup>1</sup>

## Methods

This method is based on two studies:

First study: is performed in India , published in September 3,2013.

Second study : performed in university of , California Published in April 8,2015.

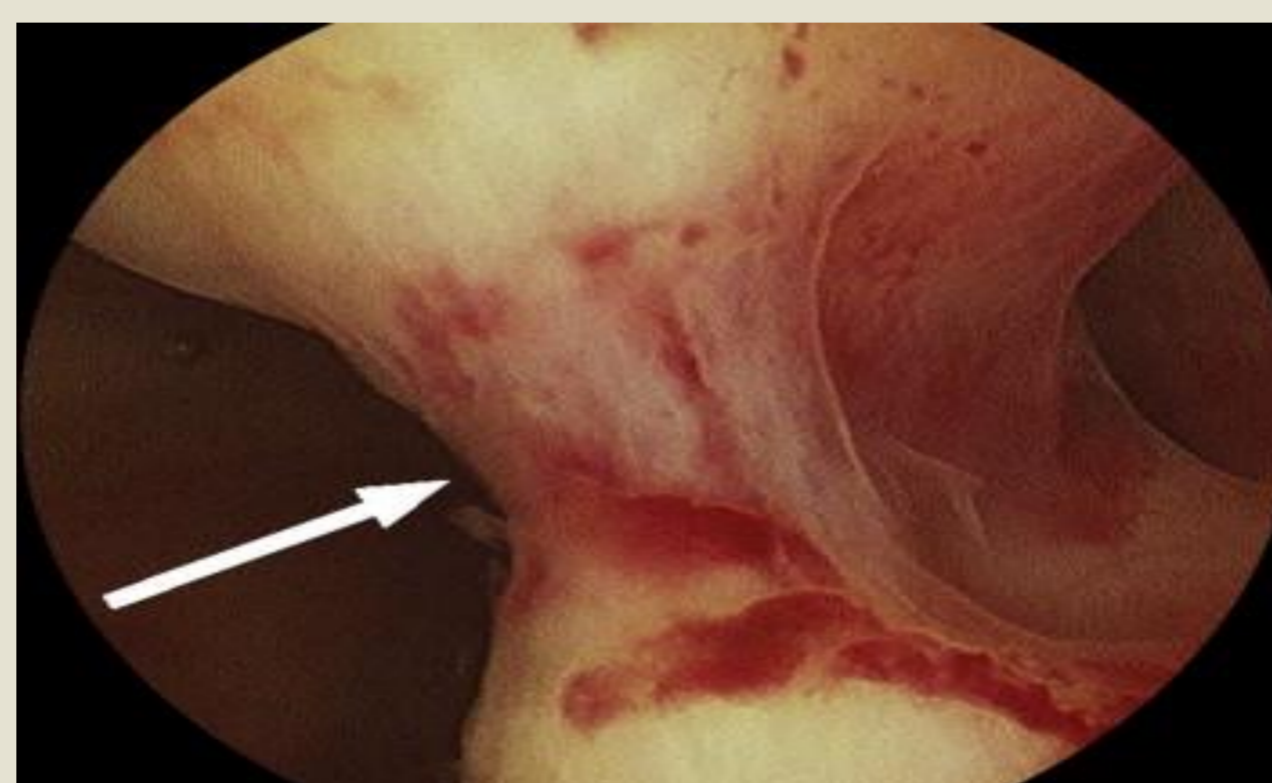
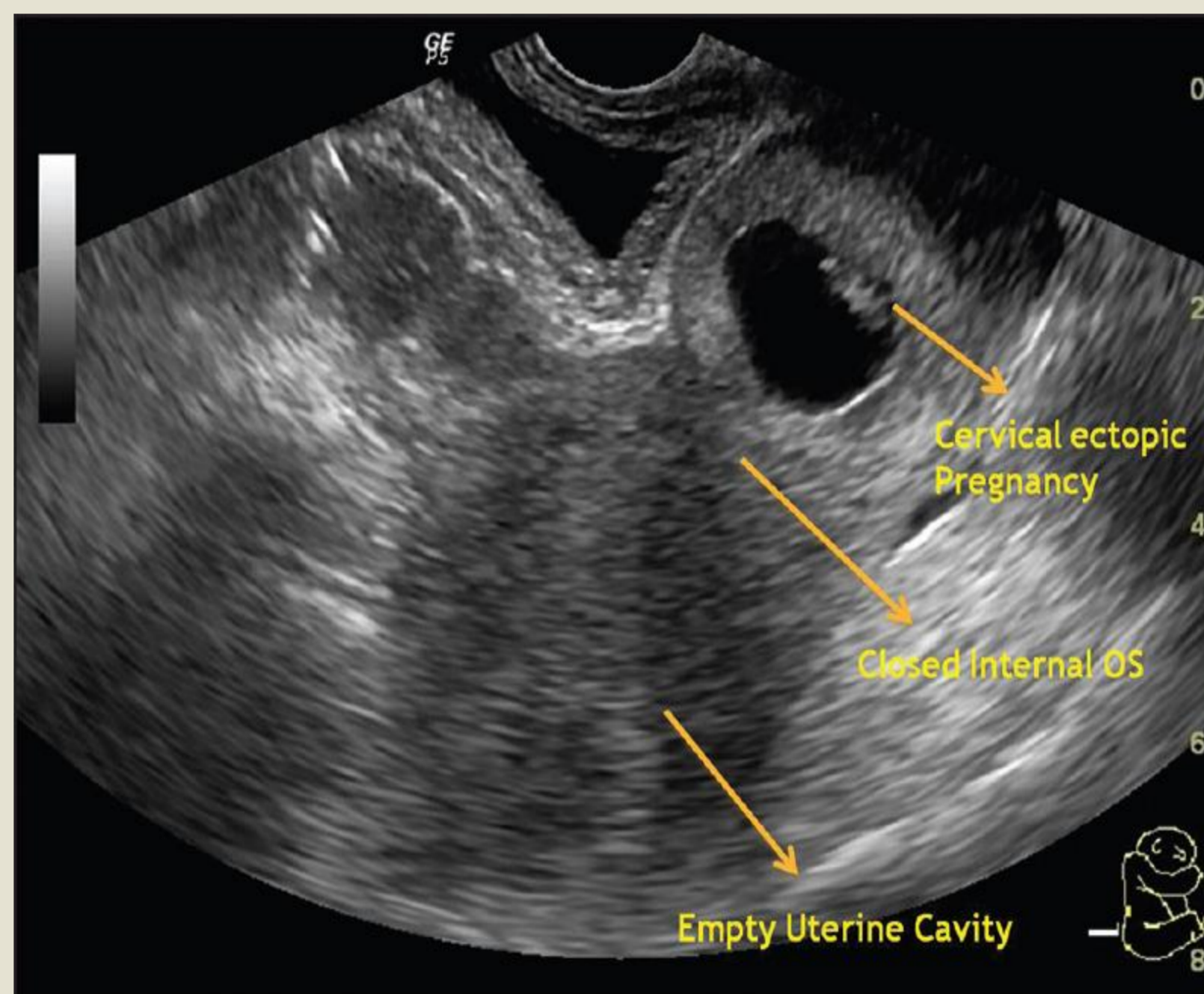
## Results

Cervical ectopic pregnancy was diagnosed :

In 27 women with a median age of 34 years. Two thirds of them were nulliparous, and 44% reported infertility. The mean gestational age at diagnosis was seven weeks. <sup>2</sup>

In 12 women pregnancy diagnosed with ultrasound Gestational age at diagnosis ranged from 5.0 to 7.9 weeks. The median age of patients was 38 years.

The diagnostic procedures include symptomatology and ultrasound imaging. The most common symptom is painless vaginal bleeding.<sup>3</sup>



## Conclusion

1-Cervical ectopic pregnancy is a rare form of ectopic pregnancy .

2- Defined as implantation of blastocyst in the endocervix, below the internal os .

3-Representing less than 1 % of all ectopic pregnancies.

4-Etiology of cervical pregnancy is unknown.

5-Early diagnosis and management is necessary for preserving patient's fertility without significant complications.<sup>4,5</sup>

## Discussion

Cervical ectopic pregnancies are feared due to their associated life-threatening transvaginal hemorrhage associated with the high risk of emergency hysterectomy and massive blood transfusions.

In the past, hysterectomy was often the only choice available due to uncontrollable hemorrhage.

Nowadays,using transvaginal sonography (TVS), the diagnosis of "cervical ectopic pregnancy" has significantly improved.

### Ultrasound Criteria for cervical pregnancy :

- 1-Echo-free uterine cavity.
- 2-Diffuse uterine wall structure.
- 3-Hourglass uterine shape.
- 4-Ballooned cervical canal (enlarged cervix equal to or larger than fundus).
- 5-Gestational sac in the endocervix.
- 6- Placental tissue in the cervical canal.
- 7-Closed internal os and a partially opened external os.<sup>4</sup>

Early diagnosis and management is necessary for preserving patient's fertility without significant complications.

### Treatments :

1-Medical treatment -single or multiple dose intra muscular methotrexate is effective in 80-90 % cases of early cervical pregnancy.

2-Potassium chloride intra amniotically can be given along with methotrexate when cardiac activity is present.

3-Need for surgical treatment increases advancing with gestational age.<sup>5</sup>

## References

- 1-Celik C, Bala A, Acar A, Gezginç K, Akyürek C. Methotrexate for cervical pregnancy. A case report. J Reprod Med. 2010;48:130-2.
- 2-Chauhan N, Goyal P, Lal A, Chhatwal J, Shamim S. Cervical ectopic pregnancy: ultrasound diagnosis and conservative management. Int J Reprod Contracept Obstet Gynecol 2013;3:3613-5.
- 3-Vela G, Tulandi T. Cervical pregnancy: the importance of early diagnosis and treatment. J Minim Invasive Gynecol 2015;14:481-484 .
4. Kirk E, Condous G, Haider Z, Syed A, Ojha H, Bourne T. The conservative management of cervical ectopic pregnancies. Ultrasound Obstet Gynecol 2016; 27: 430-437
- 5-Modayil V,Ash A,Raio C.Cervical ectopic pregnancy diagnosed by point-of-care emergency department ultrasound.J Emerg Med 2014; 41(6): 655-7