

Preliminary Report on Histopathological Aspect of Fibrous Dysplasia in Third Dimension-3D Images and Video

Sandhya Tamgadge, Avinash P. Tamgadge

Department of Oral and Maxillofacial Pathology and Microbiology, D.Y. Patil University School of Dentistry, Navi Mumbai, Maharashtra, India

Abstract

Fibrous dysplasia is a fibro-osseous lesion of the jaw which runs a chronic course. It has been well explained in the literature through high-quality 2D clinical, radiographic, and histopathological images. But the clinicians and most of the times students too, don't understand the histopathological aspect of fibrous dysplasia through the description of text and existing 2D images. This article is preliminary attempt to explain the key events of histopathological aspects of fibrous dysplasia in third dimension in a life-like manner through 3D images and video which author herself has designed, for better understanding not only by oral and general pathologists, and students but also by patients, which is the unique feature of this manuscript. Preliminary 3D images and videos on histopathological aspect of fibrous dysplasia were designed by using 3Dmax (Autodesk Media and Entertainment) and Adobe premiere pro 5.5 software which is a video editing software (Adobe Systems). Internal cellular environment of a lesion has been created in a life-like manner through 3D animation video. Histopathological aspect of all oral lesions should be explained in this manner for better understanding.

Keywords: 3D, fibrous dysplasia, histopathology, third dimension

INTRODUCTION

Fibrous dysplasia is an intraosseous bony lesion and most of the times recur. It is very common lesion to be discussed in academics in dental and medical literature and is familiar lesion among the clinicians too. It has been well explained in dental literature through high-quality 2D images. However, readers cannot visualize its pathogenesis and histopathology through such description in a life-like manner because the description has always been of a slice of the biopsy. Histopathological aspects of all the lesions in the literature have been explained, only with the help of 2D images. Therefore, author has designed 3D images and video to recreate life-like tissue and to explain the key events of its etiopathogenesis and histopathology, to be clearly understood not only by dental and medical experts and students but also by patients.^[1-3] Only few diseases have been explained in dental literature with the help of 3D images and video so far.^[4-8]

METHODOLOGY

Preliminary 3D images and videos [Video 1] on histopathological aspect of fibrous dysplasia were designed

by using 3Dmax (Autodesk Media and Entertainment) and Adobe premiere pro 5.5 software which is a video editing software (Adobe Systems).

Ethical approval was not considered as this manuscript is not patients based original research. Instead it's an original article based on 3D animation and 3D images on histopathological aspect of fibrous dysplasia using various softwares which has never been reported yet.

Histopathological of fibrous dysplasia in 2 dimensions

Biopsy tissue shows numerous irregular, C-shaped trabeculae of woven bone, not connected to each other, showing no relation to functional patterns, in a background of low to moderate cellular fibrous connective tissue. Early lesions

Address for correspondence: Dr. Sandhya Tamgadge,

Department of Oral and Maxillofacial Pathology and Microbiology,
D.Y. Patil University School of Dentistry, Sector 7, Nerul, Navi Mumbai,
Maharashtra, India.

E-mail: sandhya.tamgadge@gmail.com

Video Available on: journal.limu.edu.ly

Access this article online

Quick Response Code:



Website:
journal.limu.edu.ly

DOI:
10.4103/liuj.liuj_75_21

This is an open access journal, and articles are distributed under the terms of the Creative Commons Attribution-NonCommercial-ShareAlike 4.0 License, which allows others to remix, tweak, and build upon the work non-commercially, as long as appropriate credit is given and the new creations are licensed under the identical terms.

For reprints contact: WKHLRPMedknow_reprints@medknow.com

How to cite this article: Tamgadge S, Tamgadge AP. Preliminary report on histopathological aspect of fibrous dysplasia in third dimension-3D images and video. *Libyan Int Med Univ J* 2021;6:99-102.

Received: 16-06-2021 **Revised:** 15-07-2021

Accepted: 27-08-2021 **Published Online:** 05-01-2022




Figure 1: 3D image shows spongy bone with (a) trabeculae and overlying osteoblasts (b)

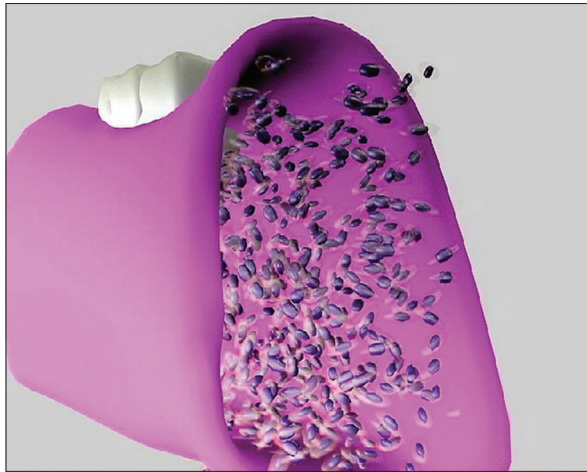


Figure 3: 3D image showing spongy bone completely replaced by cellular fibrous stroma

show more of fibrous tissue whereas advanced lesions show more of bony trabeculae imparting the characteristic “Chinese letter pattern.” The intervening fibrous connective tissue shows mononuclear cells resembling fibroblasts and progenitor osteoblasts.^[3]

Key events in the pathogenesis of fibrous dysplasia in the third dimension

1. Resorption of existing spongy bone - The spongy bone has been shown as interconnected rods present between the two cortical plates. Resorption process has been shown as disappearance of trabecular bone [Figures 1 and 2]
2. Spongy bone is replaced by highly cellular stroma - The resorbed spongy bone is then replaced by highly cellular fibrous stroma which has been shown as cell-rich tissue with plump-shaped fibroblasts [Figure 3]
3. Formation of immature bone - These young fibroblasts then lay down immature bone which is curvilinear. All the bony spicules are equidistant from each other. It gives typical Chinese script pattern [Figure 4].
4. Due to the proliferation of the lesion, the cortical plate shows expansion. All the above events have been put together in a 3D animation video https://drive.google.com/file/d/16F_HXwHTqcgdjbbvxOssgruYMpN1Y3P_/view?usp=sharing [Video 1].

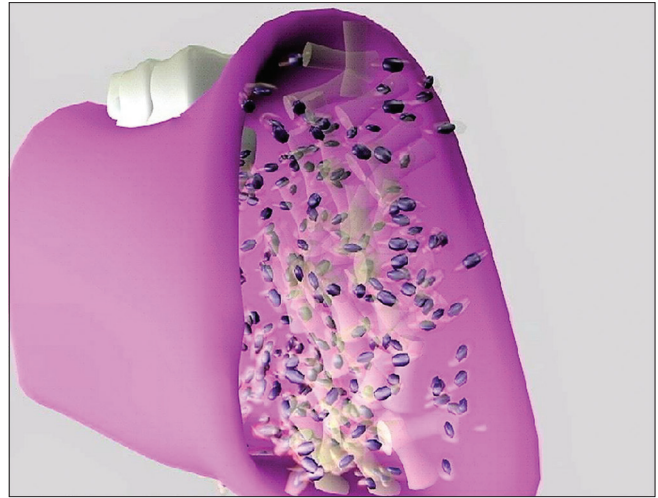


Figure 2: 3D image showing disappearing spongy bone which is replaced by cellular fibrous tissue

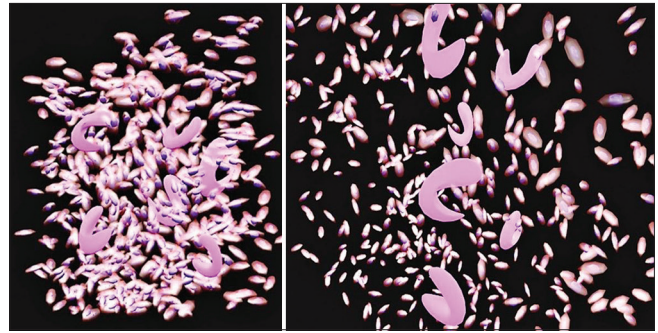


Figure 4: 3D image showing new immature bone formation in the form of Chinese script pattern

CONCLUSION

3D animation videos on histopathological aspects of all lesions should be made available on multimedia for better understanding for students in a life-like manner and to discontinue the trend of rote learning among the students.

Acknowledgment

The authors would like to thank Mr. Harishankar Agnihotri and late Mr. Bhavesh, faculties of “Maya Academy of Advanced Cinematics (MAAC)” Mulund West, Mumbai, Maharashtra, for teaching various software to author (Dr. Sandhya Tamgadge).

Financial support and sponsorship

Nil.

Conflicts of interest

There are no conflicts of interest.

REFERENCES

1. Cholakova R, Kanasirska P, Kanasirski N, Chenchev Iv, Dinkova A. Fibrous dysplasia in the maxillomandibular region – Case report. J IMAB - Annu Proc (Scientific Papers) 2010;16;10-3 (book 4) [Google Scholar]DOI: 10.5272/jimab.1642010_10-13.

2. Feller L, Wood NH, Khammissa RA, Lemmer J, Raubenheimer EJ. The nature of fibrous dysplasia. *Head Face Med* 2009;5:22.
3. Sapp JP, Eversole LR, Wysoki GP. *Contemporary Oral and Maxillofacial Pathology*. 2nd ed. St. Louis: Mosby; 2004.
4. Tamgadge S, Malathi N. From the author's desk. *J Oral Maxillofac Pathol* 2015;19:273-4.
5. Sandhya T, Avinash T. A survey based pilot study on three dimensional images and animated videos in oral histopathology. *Int J Oral Maxillofac Pathol* 2015;6:2-8.
6. Tamgadge SA. 3D Animation Video on Histopathological Features of Dentigerous Cyst. *Advances of Cytology and Pathology*. Available from: <http://medcraveonline.com/Videos>. [Last accessed on 2017 Apr 19].
7. Tamgadge S, Tamgadge A. "Histopathological aspect of oral epithelial dysplasia – Third dimension" A preliminary report. *Acta Sci Dent Sci* 2018;2:33-6.
8. Tamgadge S, Tamgadge A. Third dimension on histopathological aspect of oral lichen planus: An innovation in teaching oral pathology. *J Oral Maxillofac Pathol* 2019;23:310.

ملخص المقال باللغة العربية

تقرير أولي عن الجانب المرضي لخلل التنسج الليفي باستخدام صور وفيديو ثلاثي الأبعاد

المؤلفون

Sandhya Tamgadge, Avinash P. Tamgadge, Department of Oral and Maxillofacial Pathology and Microbiology, D.Y. Patil University School of Dentistry, Navi Mumbai, Maharashtra, India

المؤلف المسؤول: Sandhya Tamgadge ، **E-mail:** sandhya.tamgadge@gmail.com

خلل التنسج الليفي هو آفة مزمنة لعظم الفك. وقد تم شرحه بشكل جيد من خلال صور سريرية وشعاعية ونسجية عالية الجودة ثنائية الأبعاد. لكن الأطباء ومعظم الطلاب أيضًا لا يفهمون التشريح المرضي الجانب من خلال وصف النص والصور ثنائية الأبعاد الموجودة. هذه المقالة هي محاولة أولية لشرح الأحداث الرئيسية للجوانب النسيجية المرضية لخلل التنسج الليفي في البعد الثالث بطريقة تشبه الواقع من خلال الصور والفيديوهات ثلاثية الأبعاد التي صممها المؤلف بنفسه من أجل فهم أفضل ليس فقط من قبل أخصائي علم الأمراض الفموي والطلاب ولكن أيضًا من خلال المرضى، وهي السمة الفريدة لهذه المخطوطة. تم تصميم الصور ومقاطع الفيديو الأولية ثلاثية الأبعاد (فيديو 1) حول الجانب المرضي لخلل التنسج الليفي باستخدام برنامج (Adobe premiere pro 5.5 وبرنامج تحرير الفيديو (Autodesk Media and Entertainment) Dmax (Adobe Systems). تم إنشاء البيئة الخلوية الداخلية للآفة بطريقة تشبه الواقع من خلال فيديو الرسوم المتحركة ثلاثي الأبعاد. هذه الطريقة توضح أهمية شرح الجانب النسيجي لجميع الآفات الفموية.

الكلمات المفتاحية: ثلاثي الأبعاد، خلل التنسج الليفي، التشريح المرضي، البعد الثالث.